

# Closed-perforation of gastric fundus and gastric outlet obstruction caused by a giant gastric trichobezoar: A case report

## *Kapalı perforasyon ve gastrik çıkış obstrüksiyonuna neden olan dev trikobezoar olgusu*

Bünyamin Gürbulak<sup>1</sup>, Özgür Seğmen<sup>1</sup>, Taşkın Rakıcı<sup>2</sup>, Kenan Büyükaşık<sup>1</sup>, Mazlum Yavaş<sup>1</sup>

### ABSTRACT

A bezoar is a mass formed because of the accumulation of indigestible material in the stomach and/or small intestine. Bezoars are rare but occasionally occur with acute abdomen findings. Bezoars form as a result of changes in the gastrointestinal system anatomy and physiology and repetitive exposure to the ingested material. These materials can include vegetables with high fiber content (phytobezoars), non-animal origin fats, hair (trichobezoars), or drugs such as anti-acids (pharmobezoars). Gastric bezoars frequently occur after gastric surgery. Psychiatric disorders such as trichotillomania (an irresistible urge to remove and swallow one's own hair) are frequently the underlying reason in patients without a history of gastric surgery. In this article, we presented a giant gastric trichobezoar obstructing outlet and causing closed-perforation and abscess formation of gastric fundus in a 30-year-old woman.

**Keywords:** Bezoar, trichobezoar, closed-perforation of stomach, gastric outlet obstruction

### ÖZET

Bezoarlar sindirilmemiş veya kısmen sindirilmiş gıda artığı veya yabancı maddelerin genellikle mide ve/veya ince bağırsakta birikimiyle oluşan kitlelerdir. Bezoarlar gastrointestinal sistemde nadir görülmekle beraber akut batın bulgularına sebep olabilirler. Bezoarlar gastrointestinal sistem anatomi ve fizyolojisindeki değişiklikler sonucu ve aynı maddelerin ısrarlı şekilde alımı ile oluşur. Bu materyaller yüksek fiber içerikli bitkisel besinlerin alımıyla oluşan bezoarlar (fitobezoar), sindirime uğramayan saç, tırnak, hayvansal yağ gibi maddelerin alımıyla oluşan bezoarlar (trikobezoar) ya da alınan antiasit gibi ilaçların birikimine bağlı (farmakobezoar) olarak oluşabilirler. Mide bezoarları sıklıkla gastrik cerrahi sonrası olur. En sık gastrik bezoar nedenleri geçirilmiş cerrahi olmaksızın gastroparezi gibi motilite bozukluğu ve trikotillomani (kendi saçlarını koparma ve yemeye karşı konulamayan istek duyma) gibi psikiyatrik bozukluğa bağlı olarak gelişen trikobezoar oluşumudur. Biz burada mideyi tamamen doldurarak gastrik çıkış obstrüksiyonuna yol açan ve fundus tarafında kapalı perforasyona neden olan dev trikobezoarlı genç bir kadın hastayı sunmayı amaçladık.

**Anahtar Kelimeler:** Bezoar, trikobezoar, kapalı mide perforasyonu, gastrik çıkış obstrüksiyonu

### INTRODUCTION

Bezoars are masses comprising of non-digested and/or partially digested food debris or foreign particles accumulating in the stomach or the small intestine. Bezoars usually develop in the stomach or the small intestine; however, bezoar formation in the colon is rare. These masses can be classified as bezoars that are formed because of a high-fiber diet (phytobezoars), indigestible materials such as hair, fingernails, and animal fat (trichobezoars) or accumulation of anti-acids or anti-hypertensive drugs (pharmacobezoars). The most common form in clinical practice is phytobezoars (1).

Stomach bezoars usually develop following gastric surgery. Diabetes mellitus, high fiber diet, insufficient chewing function, dental pathologies, myotonic muscular dystrophy, or cimetidine treatment may rarely be the cause. Among those patients without a history of gastric surgery, the most common underlying pathology is psychiatric disorders such as trichotillomania (1, 2).

Bezoars may be clinically asymptomatic or present with chronic abdominal pain, dyspepsia, gastric ulcers, gastrointestinal hemorrhage, perforation due to pressure necrosis, intestinal intussusception, and ileus. Adult mortality rates of up to 30% related to gastrointestinal bezoars have been reported (3).

Our aim in this paper is to present a case of giant gastric trichobezoar treated with emergency surgical intervention, thereby stressing the importance of clinical doubt for correct diagnosis before complications arise because bezoars can be asymptomatic or present with nonspecific symptoms.

### CASE PRESENTATION

A 30-year-old female patient, five days after premature birth and while under follow-up in the Obstetrics and Gynecology Clinic was checked for the need for surgery due to abdominal pain, nausea, and hematemesis. The vital signs were stable and within the normal limits. The body temperature was 37.2°C. There was mild abdominal distention with epigastric tenderness and guarding. The laboratory findings were normal except for a white blood cell count of 13200/mm<sup>3</sup> and a CRP finding of 95 mg/L. Abdominal

<sup>1</sup>Clinic of General Surgery, İstanbul Training and Research Hospital, İstanbul, Turkey

<sup>2</sup>Clinic of Radiodiagnosis, İstanbul Training and Research Hospital, İstanbul, Turkey

#### Address for Correspondence Yazışma Adresi

#### Bünyamin Gürbulak

Clinic of General Surgery, İstanbul Training and Research Hospital, İstanbul, Turkey

Phone: +90 212 414 20 00

e-mail: bgurbulak@gmail.com

Received / *Geliş Tarihi:* 29.12.2014

Accepted / *Kabul Tarihi:* 25.01.2015

Available Online Date /

*Çevrimiçi Yayın Tarihi:* 06.07.2015

©Copyright 2015

by Turkish Surgical Association

Available online at

[www.ulusalcerahidergisi.org](http://www.ulusalcerahidergisi.org)

©*Telif Hakkı* 2015

*Türk Cerrahi Derneği*

*Makale metnine*

[www.ulusalcerahidergisi.org](http://www.ulusalcerahidergisi.org)

*web sayfasından ulaşılabilir.*

computerized tomography (CT) showed presplenic abscess formation and a giant intragastric mass totally occluding the stomach (Figures 1, 2). Detailed patient history revealed a long history of trichophagia and trichotillomania. Emergency surgical intervention was planned with the prediagnosis of complicated gastric bezoar. Laparotomy revealed a mass formation at the gastric fundus having caused closed perforation. When the abscess was drained after exploring the perforation site through sharp and blunt dissection; trichobezoar filling the entire stomach could be observed (Figure 3). The giant trichobezoar mass was removed from the stomach through an anterior gastrotomy, which extended longitudinally from the site of perforation at the fundus. Pressure ulcers at the gastric antrum and the angular notch could also be observed through the gastrotomy. After the debridement of the borders of the perforation, the gastrotomy incision was repaired using double sutures. On inspection, the bezoar mass was a hairball with a smooth surface having taken the shape of the stomach and the hair strands could only be removed by tearing (Figure 4). Oral feeding was started on the postoperative fifth day. The patient was referred to a psychiatrist. Depressive behavioral disorder was diagnosed accompanying trichophagia and treatment was planned. The patient was discharged from the hospital on postoperative day 10 with no complications.

#### DISCUSSION

Bezoars are masses of non-digested food particles and fibrous materials in the gastrointestinal system (GIS). They can be found anywhere in GIS, although they most frequently form in the stomach and the small intestine (3, 4).

Among bezoars, phytobezoars are the most common and the best known group. Phytobezoars are reported to be developing in up to 70% of adults having undergone gastric surgery (3). The main cause in the pathophysiology of bezoars after gastric surgery is large masses of food rapidly passing to the duodenum before being digested because of decreased acid-pepsin secretion or pyloric dysfunction. Diabetic gastroparesis, pathologies such as chronic gastritis causing decreased gastric acidity and mucus secretion, and the resulting impairment of digestion and motility are other major causes of phytobezoar formation (4). Phytobezoars can also form in patients with chewing dysfunction or dental problems because of excess consumption of high fiber food such as citrus fruits, fresh beans, fig, and fruit seeds (5). For patients without a history of abdominal surgery, phytobezoars are responsible for less than 2% of the cases of small intestinal obstruction (6).

Trichobezoars are formed by oral ingestion of mostly human hair and rarely animal fur and/or wool and filaments from furniture (6). However, the mechanism for the formation of trichobezoars is obscure. According to the most popular hypothesis, bezoars originate from strands of hair in the gastric folds combining with mucus and food particles and growing in size. However, this hypothesis fails to explain why hair strands hold on to the stomach in the first place (7). Trichobezoars are usually found in young female patients with mental retardation and/or psychiatric disorders such as trichotillomania or trichophagia. Trichobezoars are usually accompanied by psychiatric disorders such as obsessive compulsive personality disorder, pica, anorexia nervosa, or as in our case, depressive behavioral disorder.

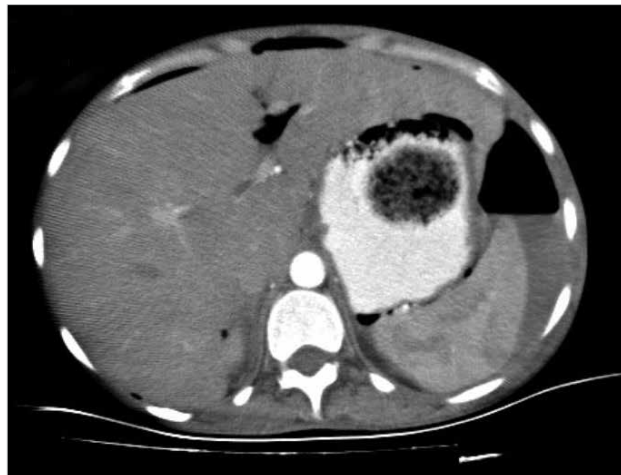

Figure 1. A giant mass that fills the lumen of the stomach with abscess formation between the stomach and spleen

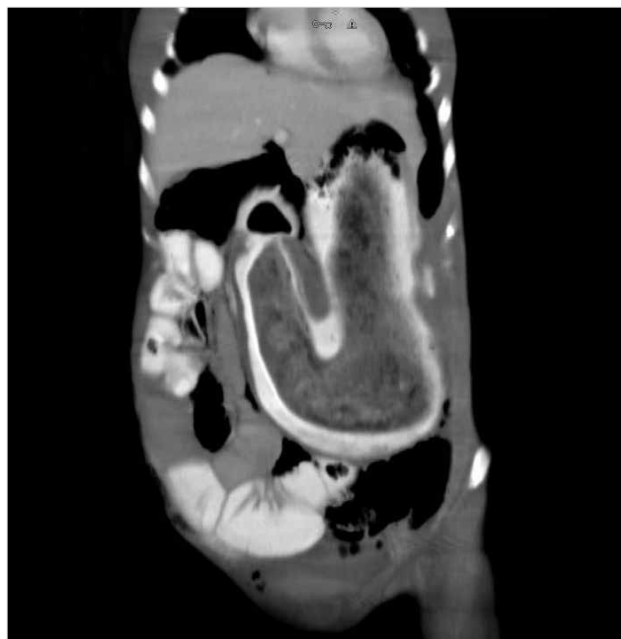


Figure 2. Computerized tomography appearance in the sagittal sections of the giant mass that fills the stomach lumen

Gastrointestinal system bezoars can be asymptomatic and incidentally diagnosed as well as presenting with gastrointestinal hemorrhage, ulcers, perforation, or intestinal obstruction (8). Stomach bezoars can cause nonspecific symptoms such as epigastric tenderness and dyspepsia or result in nausea and vomiting because of gastric outlet obstruction or abscess formation because of closed perforation.

Because the treatment of complicated GIS bezoars includes surgical intervention, a correct preoperative diagnosis of bezoar is essential, which itself requires clinical doubt. In addition to detailed patient history and careful physical examination, upper GIS endoscopy and radiological tests such as abdominal X-ray, ultrasound, or abdominal CT are helpful in diagnosis. Among these methods, upper GIS endoscopy and abdominal CT with contrast are the most reliable diagnostic tools (9). Upper GIS endoscopy is especially useful in determining the type of bezoar in cases with gastric bezoars. In addition to its diagnostic use, endoscopy has been used therapeutically in

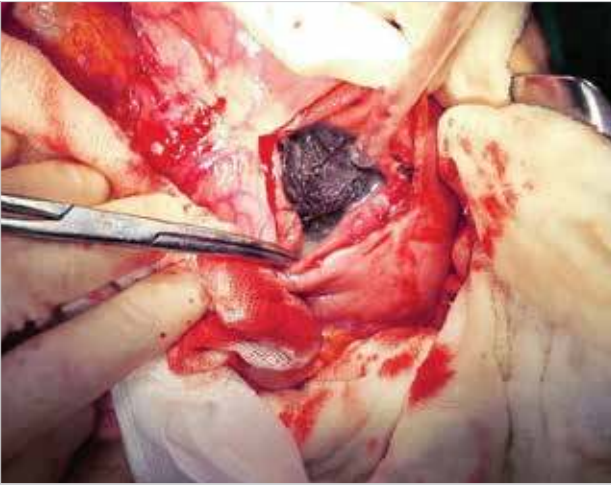

Figure 3. The trichobezoar in the gastric lumen reached via anterior gastrotomy



Figure 4. The giant trichobezoar in the shape of the stomach

the management of bezoars. Endoscopic treatment options involving the removal of gastric trichobezoars after crumbling them by baskets, snare, and lithotripter forceps have been unsuccessful (10). Phytobezoars, on the other hand, can be treated medically with motility stimulating, enzymatic, pro-kinetic, and mucolytic agents as well as endoscopically by fragmenting them with snares and forceps.

In abdominal CT scans, bezoars appear in GIS as well demarcated, oval masses with air bubbles in them. According to the localization of the bezoar mass in the GIS lumen, proximal segments are dilated and distal segments in normal caliber (9).

For our patient who was evaluated for abdominal pain, nausea, and hematemesis, intragastric mass in the abdominal CT and a history of trichophagia were alerting signs for gastric trichobezoar. Because of the abscess pouch in the CT scan

near the fundus, in front of the spleen, and having air fluid levels suggesting a closed perforation, a decision for emergency surgical intervention without prior endoscopy was made.

## CONCLUSION

Gastrointestinal bezoars can be silent until they become complicated and symptomatic. In patients with chronic abdominal pain with no signs of malignancy in laboratory and radiological tests, medical history should be elaborated and for those with a positive history of psychiatric disorders or trichophagia, bezoar should be suspected.

**Informed Consent:** Written informed consent was obtained from patient who participated in this case.

**Peer-review:** Externally peer-reviewed.

**Author Contributions:** Concept - B.G.; Design - B.G., K.B.; Supervision - B.G., Ö.S.; Funding - B.G., Ö.S., T.R.; Materials - B.G.; Data Collection and/or Processing - B.G., Ö.S., M.Y.; Analysis and/or Interpretation - B.G., Ö.S., T.R., K.B., M.Y.; Literature Review - B.G., Ö.B., T.R., K.B., M.Y.; Writer - B.G., Ö.S.; Critical Review - B.G., Ö.S., T.R., K.B., M.Y.; Other - B.G., Ö.S., T.R.

**Conflict of Interest:** No conflict of interest was declared by the authors.

**Financial Disclosure:** The authors declared that this study has received no financial support.

**Hasta Onamı:** Yazılı hasta onamı bu olguya katılan hastadan alınmıştır.

**Hakem Değerlendirmesi:** Dış bağımsız.

**Yazar Katkıları:** Fikir - B.G.; Tasarım - B.G., K.B.; Denetleme - B.G., Ö.S.; Kaynaklar - B.G., Ö.S., T.R.; Malzemeler - B.G.; Veri toplanması ve/veya işlemesi - B.G., Ö.S., M.Y.; Analiz ve/veya yorum - B.G., Ö.S., T.R., K.B., M.Y.; Literatür taraması - B.G., Ö.B., T.R., K.B., M.Y.; Yazıyı yazan - B.G., Ö.S.; Eleştirel inceleme - B.G., Ö.S., T.R., K.B., M.Y.; Diğer - B.G., Ö.S., T.R.

**Çıkar Çatışması:** Yazarlar çıkar çatışması bildirmemişlerdir.

**Finansal Destek:** Yazarlar bu çalışma için finansal destek almadıklarını beyan etmişlerdir.

## REFERENCES

- Gurses N, Ozkan K. Bezoars analysis of seven cases. *Z Kinderchir* 1987; 42: 291-292.
- Edelstein MM, Freed E, Wexler M. Diospyrobezoar of the jejunum in a post gastrectomy patient. *Arch Surg* 1971; 103: 765-766.
- Wadlington WB, Rose M, Holcomb GW. Complication of trichobezoars: A 30 year experience. *South Med J* 1992; 85: 1020-1022.
- Byrme WJ. Foreign bodies, bezoars and caustic ingestion. *Gastrointest Endosc Clin North Am* 1994; 4: 99-144.
- Tsou JM, Bishop PR, Nowicki MJ. Colonic sunflower seed bezoar. *Pediatrics* 1997; 99: 896-897.
- Granot E, Fich A, Ayalon A, Manny J, Winograd I, Schwartz J, et al. An epidemic of persimmon bezoars in Israel. *Isr J Med Sci* 1984; 20: 167-169.
- Calabuig R, Navarro S, Carrió I, Artigas V, Monés J, Puig LaCalle J. Gastric emptying and bezoars. *Am J Surg* 1989; 157: 287-290.
- Cohen LJ, Stein DJ, Simeon D, Spadaccini E, Rosen J, Aronowitz B, et al. Clinical profile, comorbidity and treatment history in 123 hairpullers: A survey study. *J Clin Psychiatr* 1995; 56: 319-326.
- Rippolles T, Garcia-Aquayo J, Martines M. Gastrointestinal bezoars: Sonographic and CT characteristics. *AJR Am J Roentgenol* 2001; 177: 65-69.
- Wang YG, Seitz U, Li ZL, Soehendra N, Qiao XA. Endoscopic management of huge bezoars. *Endoscopy* 1998; 30: 371-374.