

Metaplastic carcinoma of the breast: A rare carcinoma with chondroid metaplasia

Arzu Taşdemir¹, Arzu Oğuz², Dilek Ünal³, Ömer Tuna⁴

ABSTRACT

Metaplastic breast carcinoma accounts for less than 1% of breast malignancies. Huvos et al. first introduced the term metaplastic carcinoma in 1974. It is usually seen together with poorly differentiated ductal carcinoma of the breast. Within its mesenchymal components, undifferentiated connective tissue cells, fibroblasts, osteoblasts and chondroblasts can be found. Metaplastic breast carcinoma is an aggressive disease with a poor prognosis. In this report, a case of a 45-year-old female patient who underwent segmental mastectomy with a diagnosis of metaplastic carcinoma of the breast is presented.

Key Words: Metaplastic carcinoma, chondroid metaplasia, s100

INTRODUCTION

Metaplastic carcinoma of the breast (MCB) accounts for less than 1% of all breast cancers. Metaplastic carcinomas are divided into several subtypes according to the phenotypic appearance of the tumor. These tumors are ductal carcinomas that may also contain nonglandular epithelial cells such as squamous cells, spindle cells, and mesenchymal cells like carcinosarcoma. They are often associated with poorly differentiated ductal carcinoma (1). In this article, a 45-year-old female patient who underwent segmental mastectomy for metaplastic carcinoma of the breast is presented.

CASE PRESENTATION

A 45-year-old female patient presented to our clinics with a mass in her left breast that steadily progressed in size. The ultrasonography revealed a relatively well-circumscribed solid mass of 5 cm size located in the upper-middle quadrant, which was diagnosed as fibroadenoma, and she underwent segmental mastectomy. Macroscopic examination of the segmental mastectomy showed a tumoral mass of 2.8x2.5x2 cm in size, regular bordered, beige colored on the cross-sectional face, which contained areas of necrosis. The microscopic examination of the tumor showed areas of necrosis containing high-grade (according to the Bloom Richardson grading system; histological grade: 3, nuclear grade: 2, mitotic grade: 3, the final grade: 3) invasive ductal carcinoma areas and scattered mesenchymal chondroid areas (Figure 1, 2). Tumor borders were regular, showing an expansive growth pattern. Large areas of necrosis were observed in the infiltrating component, and there were no calcifications. The estrogen (ER), and progesterone (PR) receptors were negative, 3+ membranous staining was obtained with CerbB - 2 (HER2) (Figure 3). The Ki-67 proliferation index was evaluated as over 50% (+3). In the immunohistochemical staining, chondroid differentiation areas stained positive for s100 (Figure 4). The patient was reported as metaplastic carcinoma (high grade invasive ductal carcinoma showing chondroid metaplasia).

There were no complications in the postoperative period. The patient was recommended axillary dissection and oncologic treatment and was lost to follow-up after 2 months. Informed consent was obtained from the patient.

DISCUSSION

Metaplastic carcinomas of the breast coexist with malignant epithelial and malignant mesenchymal tissue components. They are divided into several subtypes according to the components they contain. According to 2003 classification of World Health Organization these types are divided into two sub-groups: purely epithelial carcinomas and mixed epithelial/mesenchymal metaplastic carcinoma (2). Pure epithelial carcinomas contain squamous cell carcinoma, adenocarcinoma with spindle cell metaplasia, adenosquamous carcinoma, and mucoepidermoid carcinoma; while mixed epithelial/me-

¹Clinic of Pathology,
Kayseri Training Hospital,
Kayseri, Turkey

²Clinic of Oncology,
Kayseri Training Hospital,
Kayseri, Turkey

³Clinic of Radiation Oncology,
Kayseri Training Hospital,
Kayseri, Turkey

⁴Clinic of General Surgery,
Kayseri Training Hospital,
Kayseri, Turkey

*This case was presented at the
20th National Cancer Congress
(19-23 April 2013,
Antalya, Turkey)*

Address for Correspondence Dr. Arzu Taşdemir

Clinic of Pathology, Kayseri
Training Hospital, Kayseri, Turkey
Phone: +90 352 225 60 30
e-mail:
atasdemir@erciyes.edu.tr

Received: 09.05.2013

Accepted: 09.07.2013

Online Available Date: 14.11.2013

©Copyright 2014 by Turkish
Surgical Association

Available online at
www.ulusalcerahidergisi.org

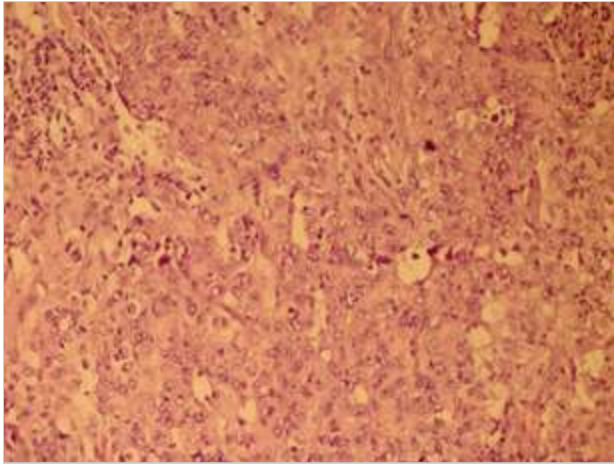


Figure 1. Invasive ductal carcinoma foci with high nuclear and histologic grade and mitotic figures, HE x40

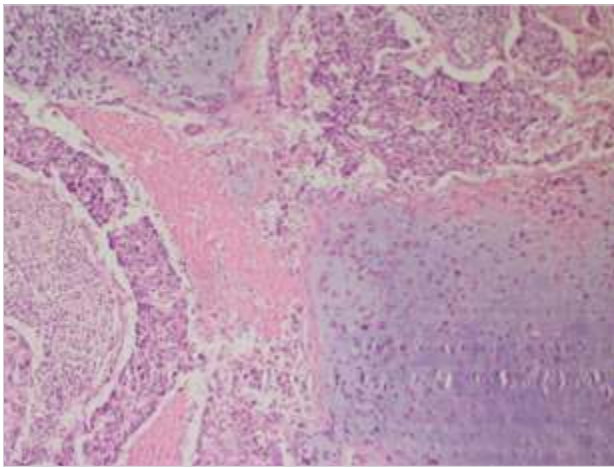


Figure 2. Chondroid metaplasia foci within the tumor, HE x20

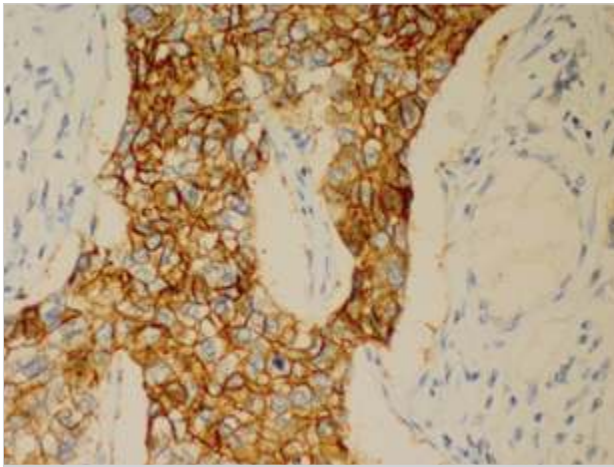


Figure 3. 3+ membranous staining in HER2 immunohistochemical staining, HER2 x40

senchymal metaplastic carcinomas are defined as carcinoma with chondroid metaplasia, carcinoma with osseous metaplasia, matrix-producing carcinoma and carcinoma. Our case was carcinoma with chondroid metaplasia and belonged to the mixed epithelial/mesenchymal metaplastic carcinoma group. In this group generating matrix, in addition to invasive ductal carcinoma heterologous mesenchymal elements such

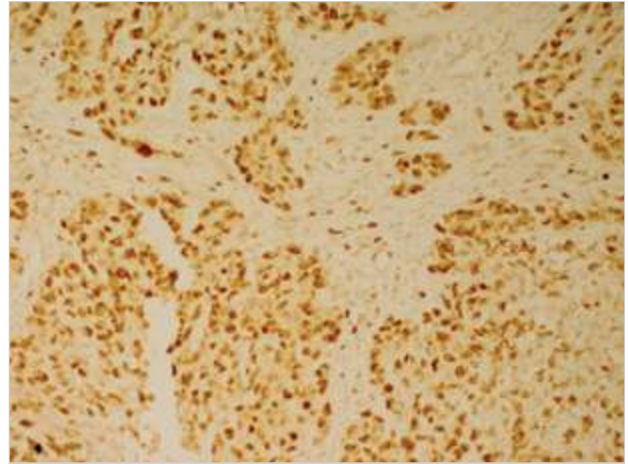


Figure 4. s100 immunohistochemical positivity in chondroid differentiation fields, s100x40

as chondroid and osseous are also present. In our case, high-grade invasive ductal carcinoma was accompanied by areas of chondroid metaplasia. If mesenchymal components accompanying the tumor is malignant then the term carcinosarcoma should be used.

Metaplastic carcinomas of the breast are observed in the 5th decade like invasive ductal carcinomas (2, 3). The youngest patient who has been previously published in the literature is 26 years old (3). Our patient was 45 years old. Metaplastic carcinomas present with a fairly large tumor size and the tumor size may vary between 1.4 to 9.5 cm (mean 3.7 cm) (3-6). In our case, the tumor size was 2.8x2.5x2 cm, which was consistent with the literature.

There are no specific findings in either mammography or ultrasonography (7). In our case, the solid mass located in the upper-middle quadrant of the left breast in 3cm diameter was diagnosed as fibroadenoma due to the relatively well-circumscribed appearance on ultrasonography. Progression of fibroadenoma and phyllodes tumor into metaplastic carcinoma have been previously reported (2).

Histopathologically benign chondroid areas are seen besides areas of invasive ductal carcinoma and immunohistochemically these chondroid areas stain strong positive with s100, and positive coexpression with cytokeratin may be observed. In our case, strong staining was obtained with s100. In breast carcinomas, with immunohistochemical staining ER is positive in 75%, PR in 55%, and HER2 in 25%, whereas metaplastic carcinomas often stain negatively for ER and PR receptors in epithelial and mesenchymal areas (8). However, in invasive ductal carcinoma areas receptors can be positively stained. Toumi et al. (9) in their review of the literature, found positive staining with ER in 12%, with PR in 10%, and with HER2 in 56%. The group with negative staining for HER2 is accepted as triple-negative tumor group. In our case, negative staining was obtained for ER and PR receptors, both in invasive ductal carcinoma and in chondroid metaplasia areas. In high grade invasive ductal carcinoma areas 3+ membranous positive staining was obtained with HER2.

The treatment modality that is more effective is controversial, due to the rarity of the disease. Although it is reported that in selected cases, results of breast conserving treatment are comparable to results of modified radical mastectomy, inclination to apply modified radical mastectomy increases due to the large size of the tumor and the local recurrence rate of 35-62% for the first 2-5 years (3, 5).

The axillary lymph node metastasis rate is reported as 19-25%, and distant metastasis rate as 21% in metaplastic carcinoma containing chondro-osseous elements.

In the study by Huvos et al. (10) the rate of axillary lymph node metastasis increases to 56% in metaplastic carcinoma showing spindle and squamous metaplasia. Axillary dissection was recommended to our patient, and she was lost to follow-up after 2 months of uncomplicated period.

CONCLUSION

Metaplastic carcinomas of the breast draw attention with the differences in their clinical course and pathological heterogeneity.

Informed Consent: Informed consent was obtained from the patient.

Peer-review: Externally peer-reviewed.

Author Contributions: Concept - A.T.; Design - A.T.; Data Collection and/or Processing - A.T., A.O., D.Ü., Ö.T.; Analysis and/or Interpretation - A.T., A.O., D.Ü.; Writer - A.T.

Conflict of Interest: No conflict of interest was declared by the authors.

Financial Disclosure: The authors declared that this study has received no financial support.

REFERENCES

1. Rose PP. Carcinoma with metaplasia. In: Rosen's Breast Pathology, Lippincott-Williams-Wilkins. 2001.p.425-454.
2. Fattaneh A, Tavassoli PD. WHO Pathology Genetics Tumours of the Breast and Female Genital Organs. Lyon 2003.p.40-41.
3. Dave G, Cosmatos H, Do T, Lodin K, Varshney D. Metaplastic carcinoma of the breast: A retrospective review. *Int J Radiat Oncol Biol Phys* 2006; 64: 771-775. [\[CrossRef\]](#)
4. Rayson D, Adjei AA, Suman VJ, Wold LE, Ingle JN. Metaplastic breast cancer: Prognosis and response to systemic therapy. *Ann Oncol* 1999; 10: 413-419.[\[CrossRef\]](#)
5. Chao TC, Wang CS, Chen SC, Chen MF. Metaplastic carcinoma of the breast. *J Surg Oncol* 1999; 71: 220-225. [\[CrossRef\]](#)
6. Kuo SH, Chen CL, Huang CS, Cheng AL. Metaplastic carcinoma of the breast analysis of eight Asian patients with special emphasis on two unusual cases presenting with inflammatory type breast cancer. *Anticancer Res* 2000; 20: 2219-2222.
7. Bilgen IG, Memiş A, Üstün EE, Zekiöglu O, Özdemir N. Metaplastic carcinoma of the breast: Clinical, mammographic, and sonographic findings with histopathologic correlation. *AJR* 2002; 178: 1421-1425. [\[CrossRef\]](#)
8. Esses KM, Hagmaier RM, Blanchard SA, Lazarchick JJ, Riker AI. Carcinosarcoma of the breast: two case reports and review of the literature. *Cases J* 2009; 2: 15. [\[CrossRef\]](#)
9. Toumi Z, Bullen C, Tang AC, Dalal N, Ellenbogen S. Metaplastic breast carcinoma: a case report and systematic review of the literature. *Pathol Int* 2011; 61: 582-588. [\[CrossRef\]](#)
10. Huvos AG, Lucas JC, Foote FW. Metaplastic breast carcinoma. R are form of mammary cancer. *N Y State J Med* 1973; 73: 1078-1082.