



# Symptomatic duodenal lipoma with endoscopic snare polypectomy

Ismail Yaman<sup>1</sup>, Hayrullah Derici<sup>1</sup>, Serpil Paksoy<sup>2</sup>

## ABSTRACT

Duodenal lipomas are extremely rare benign tumors. 90% arise from the submucosa and is usually localized in the second portion. They are usually asymptomatic and are detected incidentally during endoscopy or surgery. Appearance of symptoms are related to lesion size, those greater than four centimeters frequently may cause intussusception, obstruction or bleeding. A 59-year-old woman presented with complaints of abdominal fullness in the upper quadrants after meals, and heartburn symptoms. She had been under treatment for iron deficiency anemia during the last five months. The upper gastrointestinal endoscopy revealed a mobile, 4x2 cm polypoid mass extending from the second portion of the duodenum to the third portion, with a regular mucosa and wide pedicle. Saline and epinephrine was injected to polyp base and "snare" polypectomy was performed. Patient's complaint of fullness in the upper part of the abdomen declined after polypectomy and the treatment of anemia was discontinued after a month, with normal blood count values in the fourth month.

**Key Words:** Endoscopy, lipoma, polyps, duodenum

## INTRODUCTION

Gastrointestinal (GI) lipomas are rare, benign, slow-growing tumors and are usually single (1-3). Only 4% of gastrointestinal lipomas are located in the duodenum (1, 4). Ninety percent of duodenal lipomas arise from the submucosa and are usually localized in the second portion (2, 5). They are usually asymptomatic and discovered incidentally during endoscopy or surgery (2, 6). They can be directly visualized on upper GI endoscopy and often have a characteristic appearance (6, 7). Although endoscopic features support the diagnosis, appearance and superficial endoscopic forceps biopsies are not sufficient for a definitive diagnosis due to their submucosal location (3, 6-8). Computer tomography, magnetic resonance imaging and endoscopic ultrasonography can provide important information for differential diagnosis (4, 5, 8).

Symptoms are related to the size of the lesion; those larger than four centimeters often present with intussusception, obstruction or bleeding (1, 4, 7, 9). Symptomatic duodenal lipomas require treatment and the current treatment of choice is endoscopic resection (1, 2, 4, 7, 8). "Snare" polypectomy can be safely used in lipomas that have not grown extensively or those with a pedicle (2, 7).

In this report, a case of large and symptomatic duodenal lipoma located at the second portion, which was treated by "snare" polypectomy was presented.

## CASE PRESENTATION

A 59-year-old woman had complaints of ongoing upper abdominal fullness after meals and heartburn for the last three months. She was positive for fecal occult blood examination and on upper GI endoscopy a four centimeter in size giant polyp was detected in the second portion of the duodenum, and she was referred to our center. Her past medical history revealed diabetes mellitus, hypercholesterolemia, and she had been receiving medical therapy due to iron deficiency anemia. On physical examination, there were no pathologic findings except epigastric tenderness. Laboratory values were normal except Hgb: 9.7 g/dL, Hematocrit: 29.8%, MCV: 75.4 fl. Abdominal ultrasonography and colonoscopy were normal. On upper GI endoscopy (Pentax EG-290) antrum was hyperemic. A 4x2 cm mobile, polypoid mass with a wide pedicle was extending from the second portion of the duodenum to the third portion, and was covered with regular mucosa. The stalk of the polypoid mass was in the second portion, and the tip portion was replaced in the second portion by grasping with a forceps for several times (Figure 1). The mass was grasped with an oval 30 mm disposable standard "snare", and it was decided that polypectomy would be suitable due to the lesion's being mobile and pediculated. Saline with epinephrine was injected to the base of the polyp and neck elevation was observed. The patient who underwent polypectomy was discharged uneventfully after one day of observation, and was started on proton pump inhibitor treatment due to antral gastritis. On histopathologic examination, a submucosal lipoma was detected in the duodenum (Figure 2). Informed consent was obtained from the patient. The complaint of up-

<sup>1</sup>Department of General Surgery, Balıkesir University Faculty of Medicine, Balıkesir, Turkey

<sup>2</sup>Department of Pathology, Balıkesir University Faculty of Medicine, Balıkesir, Turkey

## Address for Correspondence İsmail Yaman

Department of General Surgery,  
Balıkesir University Faculty of  
Medicine, Balıkesir, Turkey  
Phone: +90 266 245 44 25  
e-mail:  
ismailyaman35@gmail.com

Received: 24.01.2013  
Accepted: 19.07.2013

©Copyright 2014  
by Turkish Surgical Association  
Available online at  
www.ulusalcerahidergisi.org

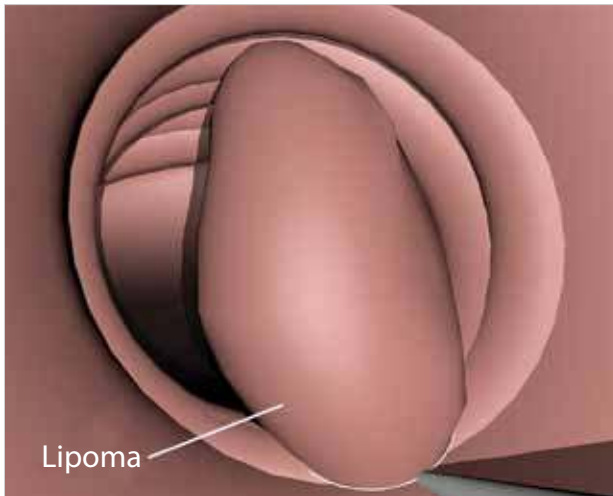


Figure 1. Reduction of the tip of the lipoma into the second portion

per abdominal fullness regressed after polypectomy, and the treatment for anemia was discontinued after one month. The patient is being followed-up with negative stool occult blood tests and normal complete blood count values in the fourth post-procedure month.

#### DISCUSSION

Duodenal lipomas are extremely rare, benign tumors (2-4, 6, 7). A study that involved 1200 duodenoscopies, reported only 2 patients with duodenal lipoma (7). They are usually asymptomatic and are discovered incidentally during endoscopy or surgery (1, 2, 6, 8). Symptoms are generally related to the size of lipomas, and dyspepsia, epigastric fullness after meals, intestinal obstruction, or iron deficiency anemia due to occult or massive hemorrhage can be observed especially in duodenal lipomas larger than four centimeters (3, 7-9). It is reported that 75% of duodenal lipomas that are larger than four centimeters are symptomatic (9). Huang et al. (6) stated that the two cases with duodenal lipoma in their series had complaints of fullness after meals although the tumor size was less than three cm in both patients.

Ninety percent of duodenal lipomas arise from the submucosa (2, 6). The typical endoscopic image is a yellowish, ovoid polypoid lesion covered by normal mucosa (6, 9). When the lesion is compressed with biopsy pickups, it is observed that the tumor is soft and compressible, and the overlying mucosa is mobile (4). As the lipoma grows, the traction force of the intestinal content and peristaltic movement may cause erosion and ulceration of the mucosa, and can create a pedicle (4). Although endoscopic view supports the diagnosis, it is generally insufficient in making a definitive diagnosis since the tumor is submucosal, and forceps biopsies are generally inadequate for similar reasons (3, 6-9). The definitive diagnosis is made after tumor excision and histopathologic examination (8). Computed tomography, magnetic resonance imaging and/or endoscopic ultrasonography can be used before tumor excision (4, 6). Especially endoscopic ultrasonography may be useful in providing information on the nature of the mass, the layer it originates from and the depth of invasion (6).

Malignant transformation of gastrointestinal lipomas has not been reported (9). They require treatment if the duodenal li-

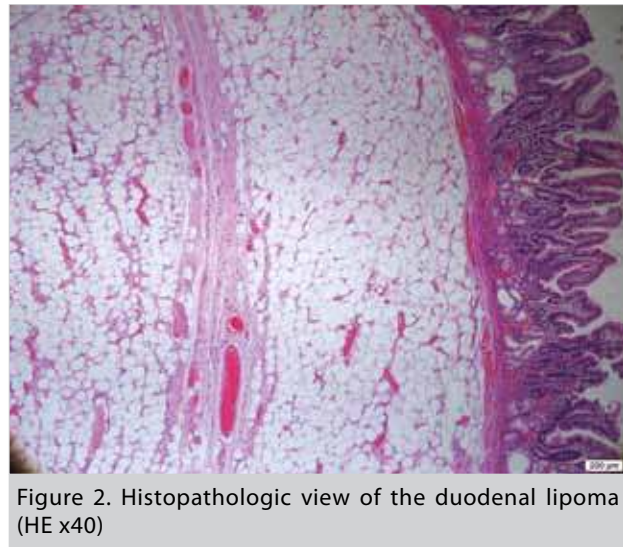


Figure 2. Histopathologic view of the duodenal lipoma (HE x40)

pomas detected on endoscopy are large, could not be distinguished from malignant masses or if they are symptomatic (7-9). Currently, the recommended treatment is endoscopic removal (1, 2, 4). Endoscopic techniques for removal of gastrointestinal lipomas include "snare" polypectomy, "endoloop", "unroofing", subtotal resection and submucosal dissection (2, 6, 7). In the "endoloop" technique, an "endoloop" is placed to the base and then polypectomy is performed. By the "unroofing" technique, the mucosa overlying the polypoid mass is excised and the lipoma that is protruding into the lumen is excised. In subtotal resection, the polypoid mass is not removed completely but only a fraction is resected. In submucosal dissection technique, surrounding submucosa is reached by using special devices and a wide excision with negative mucosal margins is performed. The most important factors in the decision whether the mass can be resected endoscopically and the preferred technique are the location, and size of the lesion, the thickness of the stalk, and the physician's experience (2). Endoscopic therapy can be difficult in the distally located lesions, since the second part of the duodenum is narrow and angular (1). Large lipomas create additional risk factors in terms of perforation and bleeding (1, 6). It is reported that endoscopic resection can be successfully applied even at lipomas larger than four cm (4, 6). It is stated that in lipomas larger than four cm. the risk of perforation is less in the "endoloop" technique that provides base security with the "endoloop", and the "unroofing" technique that does not extend to the base, as compared to "snare" polypectomy. On the other hand, snare polypectomy is reported as a safe method in even lipomas with large sizes as long as they are pedunculated (2, 6, 7, 10). Murata (10) and Blanchet (9) have reported uncomplicated "snare" polypectomy of pedunculated, duodenal, submucosal lipomas up to four and five cm, respectively. Thick stalk and wide base increase the risk of invagination of the muscularis propria and serosa into the stalk, thus increasing the risk of perforation (2, 6). It may be attempted to evaluate this condition by moving the lipoma after closing the "snare" and when in doubt an endoscopic ultrasonography can be used (2, 6). Submucosal injection of saline with epinephrine may assist in the removal of large lesions by separation of the lipoma from the underlying muscle layer, thus reducing the risk of perforation and bleeding (2). Despite the distally located, large polypoid mass in our patient, a "snare" polypectomy

was applied because the lesion was pedicled, mobile, and the stalk was elevated after submucosal injection. The pre-procedure iron deficiency anemia was considered to be related to the polyp because she was negative for occult blood in the stool, with normal complete blood count tests after polypectomy.

### CONCLUSION

In conclusion, duodenal lipomas rare, usually asymptomatic and benign tumors. They may become symptomatic when they reach a larger size. Endoscopic resection is the treatment of choice in symptomatic duodenal lipomas.

---

**Informed Consent:** Written informed consent was obtained from patient who participated in this case.

**Peer-review:** Externally peer-reviewed.

**Author Contributions:** Concept - İ.Y.; Design - İ.Y.; Supervision - H.D.; Funding - İ.Y., H.D., S.P.; Materials - İ.Y., H.D., S.P.; Data Collection and/or Processing - İ.Y.; Analysis and/or Interpretation - İ.Y., H.D., S.P.; Literature Review - İ.Y., S.P.; Writer - İ.Y.; / Critical Review - H.D.; Other - İ.Y., H.D., S.P.

**Conflict of Interest:** No conflict of interest was declared by the authors.

**Financial Disclosure:** The authors declared that this study has received no financial support.

### REFERENCES

1. Chang CW, Chu CH, Shih SC, Chen MJ, Yang TL, Chang WH. Duodenal polypoid lipoma with bleeding. *Am J Surg* 2010; 200: 49-50. [\[CrossRef\]](#)
2. Aydin HN, Bertin P, Singh K, Arregui M. Safe techniques for endoscopic resection of gastrointestinal lipomas. *Surg Laparosc Endosc Percutan Tech* 2011; 21: 218-222. [\[CrossRef\]](#)
3. Chen HT, Xu GQ, Wang LJ, Chen YP, Li YM. Sonographic features of duodenal lipomas in eight clinicopathologically diagnosed patients. *World J Gastroenterol* 2011; 17: 2855-2859.
4. Sou S, Nomura H, Takaki Y, Nagahama T, Matsubara F, Matsui T, et al. Hemorrhagic duodenal lipoma managed by endoscopic resection. *J Gastroenterol Hepatol* 2006; 21: 479-481. [\[CrossRef\]](#)
5. Chen HT, Xu GQ, Wang LJ, Yu WH, Zhou YF, Li YM. The diagnosis and treatment of duodenal lipoma. *Zhonghua Nei Ke Za Zhi* 2010; 49: 125-128.
6. Huang WH, Peng CY, Yu CJ, Chou JW, Feng CL. Endoloop-assisted unroofing for the treatment of symptomatic duodenal lipomas. *Gastrointest Endosc* 2008; 68: 1234-1236. [\[CrossRef\]](#)
7. Tung CF, Chow WK, Peng YC, Chen GH, Yang DY, Kwan PC. Bleeding duodenal lipoma successfully treated with endoscopic polypectomy. *Gastrointest Endosc* 2001; 54: 116-117. [\[CrossRef\]](#)
8. Kadaba R, Bowers KA, Wijesuriya N, Preston SL, Bray GB, Kocher HM. An unusual cause of gastrointestinal bleeding: duodenal lipoma. *Case Rep Gastroenterol* 2011; 5: 183-188. [\[CrossRef\]](#)
9. Blanchet MC, Arnal E, Paparel P, Grima F, Voiglio EJ, Caillot JL. Obstructive duodenal lipoma successfully treated by endoscopic polypectomy. *Gastrointest Endosc* 2003; 58: 938-939. [\[CrossRef\]](#)
10. Murata A, Osoegawa T, Ijyu M, Kanayama K, Tanaka M, Nakamura K. Pedunculated duodenal lipoma treated with endoscopic polypectomy with a detachable snare. *Fukuoka Igaku Zasshi* 2008; 99: 131-135.