

Incidental biliary cystadenoma mimicking liver metastasis in a gastric cancer patient

Pınar Yazıcı¹, Ünal Aydın²

ABSTRACT

Biliary cystadenoma represents a rare benign cystic hepatic neoplasm with premalignant potential. The diagnosis is usually difficult, and imaging methods may not be possible to clarify the pathology. It can be hard to determine, particularly in patients with a previous cancer history that has high metastatic potential in the liver. We presented a 53-year-old man with a newly diagnosed liver mass that was suspicious for metastasis 2 years after gastric cancer surgery and histological analysis confirmed the diagnosis of biliary cystadenoma.

Key Words: Gastric cancer, liver mass, biliary cystadenoma

INTRODUCTION

Biliary cystadenoma represents a rare benign cystic hepatic neoplasm with premalignant potential (1). The diagnosis is usually difficult, due to the similar clinical presentation as those of simple hepatic cysts. In addition, infected hepatic cysts, pyogenic abscess, degenerated liver tumor, Caroli disease, and post-traumatic or hemorrhagic cyst should be considered in the differential diagnosis. Radiological diagnostic methods for differentiating biliary cystadenoma from other malignant hepatic lesions may not be conclusive (2). Although this concern is not very important for the treatment approach to the management of focal liver lesions suspicious for biliary cystadenoma, it should be checked twice in a patient with a history of gastric cancer surgery, considering probable liver metastasis. Nevertheless, liver metastasis from gastric cancer is rarely cured, even by resection, with a 5-year survival rate of 11% (3). We presented a patient with gastric cancer which was complicated with a newly diagnosed liver mass that histological analysis confirmed the diagnosis of biliary cystadenoma.

CASE PRESENTATION

A 53-year-old man was admitted to our clinic due to the detection of a new liver lesion, which was suspected for metastasis. His surgical history was notable for a gastric cancer treated with total gastrectomy and esophagojejunostomy 2 years ago. The histopathological examination revealed a moderate to poorly differentiated 'intestinal-type' gastric adenocarcinoma infiltrating the muscularis propria. Resection margins and 27 lymph nodes were free of tumor (T2, N0, M0). In the routine clinic visit in the follow-up, laboratory investigations revealed a mild elevation in cancer antigen 19-9 (CA 19-9) level (49.2 U/L, normal range ≤ 24), and Doppler ultrasonography of the liver was performed. It demonstrated a new liver mass 25 x 17 mm in size that was located next to the left branch of the portal vein, showing central hyperechogenicity and cystic margins. A follow-up positron emission tomography was recommended, and this confirmed a hypermetabolic focus in segment IV A of the left hepatic lobe, suspicious for metastatic disease (maximum standardized uptake value: 5.7) (Figure 1, 2). Informed consent was obtained, and he underwent explorative laparotomy.

Intraoperative ultrasonography findings demonstrated a 23-mm mass located between segment IVB and III, with evidence of venous invasion. With regard to these findings, left lateral hepatectomy was performed under selective intermittent inflow occlusion, delineating the resection line. No intraoperative or postoperative complication was observed, and the patient was discharged on postoperative day 5. Histopathological examination revealed benign biliary cystadenoma of the liver. There was no recurrence after 18 months of follow-up.

¹Clinic of General Surgery, Şişli Etfal Training and Research Hospital, İstanbul, Turkey

²Clinic of General Surgery, İzmir University Medical Park Hospital, İzmir, Turkey

Address for Correspondence

Pınar Yazıcı

e-mail: drpinaryazici@gmail.com

Received: 07.08.2014

Accepted: 08.09.2014

Available Online Date: 26.11.2014

©Copyright 2016

by Turkish Surgical Association

Available online at

www.ulusalcerahidergisi.org

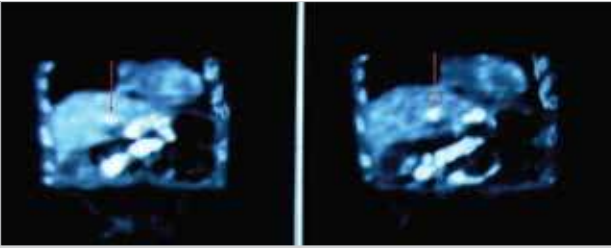


Figure 1. Hepatic mass (16 mm) located in the left lobe (arrow)

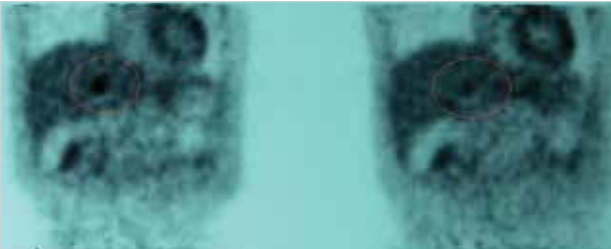


Figure 2. ¹⁸F-fluorodeoxyglucose positron emission tomography, demonstrating metabolic hyperactivity of the hepatic nodule in the left lobe (red halo)

DISCUSSION

Biliary cyst tumors (cystadenoma or cystadenocarcinoma) account for 5% of all solitary cystic liver lesions. Although the initial diagnosis is usually made with abdominal imaging methods, they are not usually diagnostic despite being useful to characterize the lesion. Differential diagnoses include multiloculated or complicated biliary cysts, atypical hemangiomas, and hamartomas (4). It is hard to decide whether it is a new metastatic focus or another primary tumor, in the liver based on imaging or gross appearance, in a patient with a history of gastric cancer surgery. In our patient, elevated CA 19-9 level was considered as a marker of recurrence or metastatic disease.

Biliary cystadenomas are preoperatively misdiagnosed in 50% to 70% of cases, thus resulting in delayed and inaccurate treatment (5). The risk of recurrence is high if inadequate treatment is performed (6). Hence, the correct diagnosis is crucial. The preoperative radiological diagnostic accuracy may be as low as 30% for biliary cystadenoma, and therefore, a high index of suspicion is indicated (7). In the present case, Doppler ultrasound revealed a newly developed hypovascular liver mass containing cystic components and that was in close proximity to vascular structures and the lesion. Positron emission tomography also confirmed this lesion with increased metabolic activity. A history of gastric cancer surgery caused a diagnostic challenge for this patient and primarily raised the suspicion of metastatic liver disease. Although a histological examination usually offers the best differentiation, fine needle aspiration biopsy may not be helpful for the differential diagnosis of cystic liver tumors. Because the lesion was both single and easily accessible, instead of biopsy, we advocated surgical resection.

Complete surgical excision of the biliary cystadenoma is the optimal treatment approach to reduce the risk of both recur-

rence, with a rate of 10% (8, 9), and malignant transformation (5). Considering the malignant potential, radical resection remains the treatment of choice in patients with cystadenoma. In this patient, the main origin of the liver tumor was primarily considered metastatic due to a previous history of gastric cancer. Since the liver mass was small-sized, single, and appropriate for R0 resection, left lateral segmentectomy was performed.

CONCLUSION

This case emphasizes the infrequent manifestation of biliary cystadenoma, which can mimic metastatic liver disease in patients with previous gastric cancer. The prognosis for these two entities is very different, and accordingly, the proper diagnosis is important. However, diagnostic imaging methods may not be helpful. Hepatic resection and histological examination remain necessary to rule out metastasis in cystic tumors of the liver.

Informed Consent: Written informed consent was obtained from patient who participated in this case.

Peer-review: Externally peer-reviewed.

Author Contributions: Concept - Ü.A.; Design - P.Y., Ü.A.; Supervision - Ü.A.; Funding - P.Y.; Materials - P.Y.; Data Collection and/or Processing - P.Y.; Analysis and/or Interpretation - P.Y., Ü.A.; Literature Review - P.Y.; Writer - P.Y.; Critical Review - Ü.A.

Conflict of Interest: No conflict of interest was declared by the authors.

Financial Disclosure: The authors declared that this study has received no financial support.

REFERENCES

1. Tsiftsis D, Christodoulakis M, de Bree E, Sanidas E. Primary intrahepatic biliary cystadenomatous tumors. *J Surg Oncol* 1997; 64: 341-346. [\[CrossRef\]](#)
2. Wahba R, Kleinert R, Dieplinger G, Bangard C, Drebber U, Hölscher AH, et al. Mucinous cystic neoplasm or non-parasitic liver cyst? - A challenging diagnosis. *Hepatogastroenterology* 2013; 60: 585-589.
3. Saiura A, Umekita N, Inoue S, Maeshiro T, Miyamoto S, Matsui Y, et al. Clinicopathological features and outcome of hepatic resection for liver metastasis from gastric cancer. *Hepatogastroenterology* 2002; 49: 1062-1065.
4. Devaney K, Goodman ZD, Ishak KG. Hepatobiliary cystadenoma and cystadenocarcinoma. A light microscopic and immunohistochemical study of 70 patients. *Am J Surg Pathol* 1994; 18: 1078-1091. [\[CrossRef\]](#)
5. Simo KA, Mckillop IH, Ahrens WA, Martinie JB, Iannitti DA, Sindram D. Invasive biliary mucinous cystic neoplasm: a review. *HPB (Oxford)* 2012; 14: 725-740. [\[CrossRef\]](#)
6. Emre A, Serin KR, Ozden I, Tekant Y, Bilge O, Alper A, et al. Intrahepatic biliary cystic neoplasms: Surgical results of 9 patients and literature review. *World J Gastroenterol* 2011; 17: 361-365. [\[CrossRef\]](#)
7. Choi BI, Lim JH, Hanetal MC. Biliary cystadenoma and cystadenocarcinoma: CT and sonographic findings, *Radiology* 1989; 171: 57-61.

8. Vogt DP, Henderson JM, Chmielewski E. Cystadenoma and cystadenocarcinoma of the liver: a single center experience. *J Am Coll Surg* 2005; 200: 727-733. [\[CrossRef\]](#)
9. Pillai SA, Velayutham V, Perumal S, Ulagendra PS, Lakshmanan A, Ramaswami S, et al. Biliary cystadenomas: A case for complete resection. *HPB Surg* 2012; 2012: 501705.