



# Iatrogenic Zenker's diverticulum perforation: A conservatively treated case

Tuncer Babür

## ABSTRACT

Zenker's diverticulum is the most common type of diverticulum in the esophagus. Most patients are elderly. Typical symptoms are regurgitation, dysphagia, halitosis and chronic cough. The most common treatments are open surgical diverticulectomy with cricopharyngeal myotomy or diverticulopexy. Most instances of esophageal perforation are iatrogenic. Rapid diagnosis and therapy provide the best chance for survival. If diagnosed early, cervical esophageal perforations can be treated conservatively if there are no signs of systemic sepsis. In this case report a conservatively treated cervical esophageal diverticulum perforation is presented.

**Key Words:** Zenker's diverticulum, esophageal injury, esophageal perforation

## INTRODUCTION

Pharyngoesophageal diverticulum (Zenker's diverticulum) is the most frequent diverticulum of the esophagus. It is acquired, and not a real but a pulsion diverticulum (1). It is generally seen among people above the age of 60, and it is thought that this situation occurs as a result of the loss of tissue elasticity and decreased muscle tonus (2). Esophagus perforations include iatrogenic perforations, spontaneous perforations and trauma (3). The mortality rate of non-operative treatment of esophagus perforations is 20-38% (4). On the other hand, this rate may come close to zero in well-selected patients (3). The criterion proposed by Cameron et al. (5) for non-operative treatment is a contained leak in a stable patient without sepsis, pleural or peritoneal cavity communication. We aimed at reporting on the treatment of a Zenker's diverticulum perforation that coincidentally developed in a patient who was operated on due to acute abdomen.

## CASE PRESENTATION

A thirty-five-year-old female patient presented to our emergency outpatient clinic with complaints of abdominal pain and distention. She had been having problems for approximately 10 days. Her personal and family histories were unremarkable. On physical examination, the lower right quadrant was tender. Her leukocyte count was: 8400, urinalysis was normal, with CRP: 74 mg/dL, sedimentation: 60 mm/hour. The abdominal ultrasound showed a hypochoic lesion, 95x35 mm in size, and a loculated collection was detected in the pericecal site on abdominal computerized tomography. The gynecological consultation was normal. The diagnosis of acute abdomen was made based on these findings. In the exploration, a plastroned appendicitis with partial infiltration of the sigmoid colon was identified. The sigmoid colon was freed, a drain was placed in the Douglas' pouch, the abdomen was closed and a nasogastric tube was inserted in the patient. The tube came out by itself on the first post-operative day. On the second post-operative day the leukocyte count was 9800, and CRP: 208 mg/dL. She complained of throat ache, swallowing difficulty, vomiting and a swelling in the left side of the neck. A subcutaneous crepitation on the left side of the neck was identified. In the thoracic tomography scan, soft tissue emphysema in the neck and upper mediastinum, asymmetrical expansion and contour irregularity in the left wall of the upper esophagus in the cervicothoracic site and a Zenker's diverticulum perforation were detected (Figure 1). Subcutaneous air was seen on chest x-ray. Considering a potential Zenker's diverticulum perforation secondary to the tube, the oral feeding was discontinued and the decision was taken to follow up the patient considering the good overall status. Contained contrast leak was observed with barium chest x-ray (Figure 2). In the endoscopic examination performed on post-operative day 6, a diverticulum containing purulent material, approximately 4-5 cm in size, covered with inflammatory bands and plaques was observed (Figure 3). The crepitations regressed. Oral feeding was started on post-operative day 9. The endoscopic examination performed on the 11<sup>th</sup> post-operative day showed that the purulent material regressed to a great extent, the diverticulum wall was erythematous and edematous, and there were islands of normal mucosa (Figure 4). The clinical and laboratory values of the patient returned to normal limits on post-operative day 13, and she was discharged to be controlled at the outpatient clinic.

Clinic of General Surgery,  
Ministry Health Kartal Yavuz  
Selim State Hospital, Istanbul,  
Turkey

This study was presented at the  
18<sup>th</sup> National Surgical Congress  
as an poster, 23-27 May 2012,  
Izmir, Turkey

## Address for Correspondence Tuncer Babür

Clinic of General Surgery,  
Ministry Health Kartal Yavuz  
Selim State Hospital, Istanbul,  
Turkey  
Phone: +90 532 162 17 75  
e-mail: tuncerbabur@yahoo.com

Received: 18.03.2012  
Accepted: 02.11.2012  
Online Available Date:  
28.05.2013

©Copyright 2014 by Turkish  
Surgical Association

Available online at  
www.ulusalcerahidergisi.org

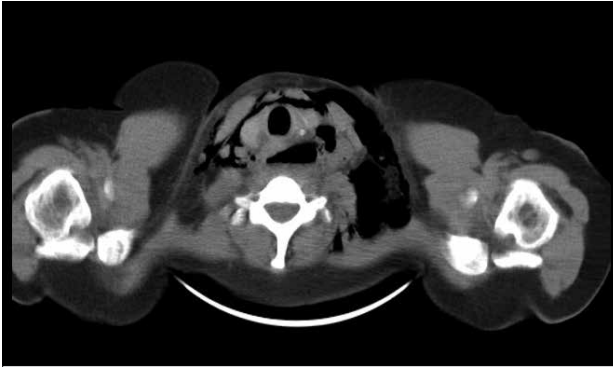
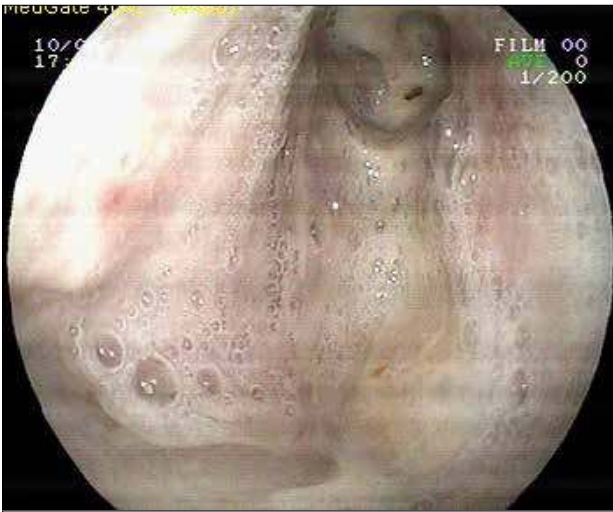

Figure 1. Diverticulum on thorax tomography

Figure 3. Endoscopic view on postoperative 6<sup>th</sup> day

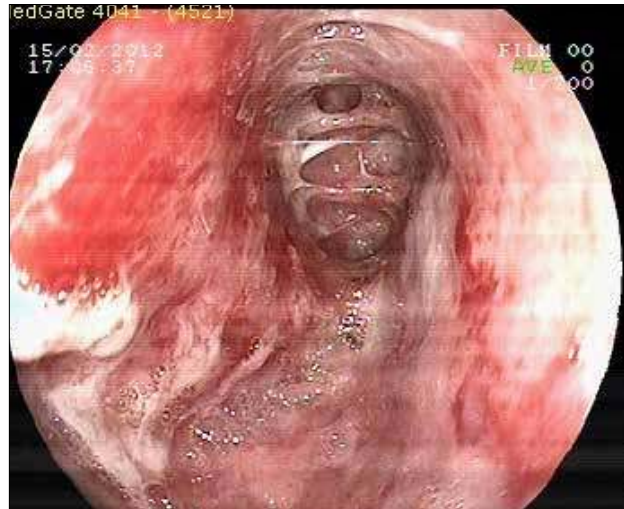
## DISCUSSION

The prevalence of Zenker's diverticulum among general population is 1-11/100.000 (6). It is generally seen among people above the age of 60-70, and it is rarely seen before the age of 40, whereas our case was 35 years old (7). It is more frequent among men, yet our patient was female. It is located posterior in the midline and often extends to the left. Since it is a pulsion diverticulum, it contains only the mucosa layer of the esophagus. The reason for its development is controversial and the essential reason is the high pressure emerging in the hypopharynx (8). Patients generally present to the clinic due to complaints of difficulty in swallowing solid or liquid food, the feeling of something being stuck in the cervical site, regurgitation, cough and halitosis (8). Our patient did not have any complaints in the pre-operative period. As the pouch is enlarged, the symptoms become more severe. The most frequent symptoms include concomitant chronic aspiration and recurrent respiratory tract infections. One of the most important complications of Zenker's diverticulum is aspiration that especially occurs at night, and may cause pulmonary abscess (1). Other complications include perforation, bleeding and carcinoma. In our patient, an iatrogenic perforation developed. There is also the risk of squamous cell carcinoma within the diverticulum (0.3%) (8).

There are not many clinical examination findings. Pharyngeal pouches can be diagnosed easily by using barium x-rays that indicate the margins of the pouch very well. Barium x-rays

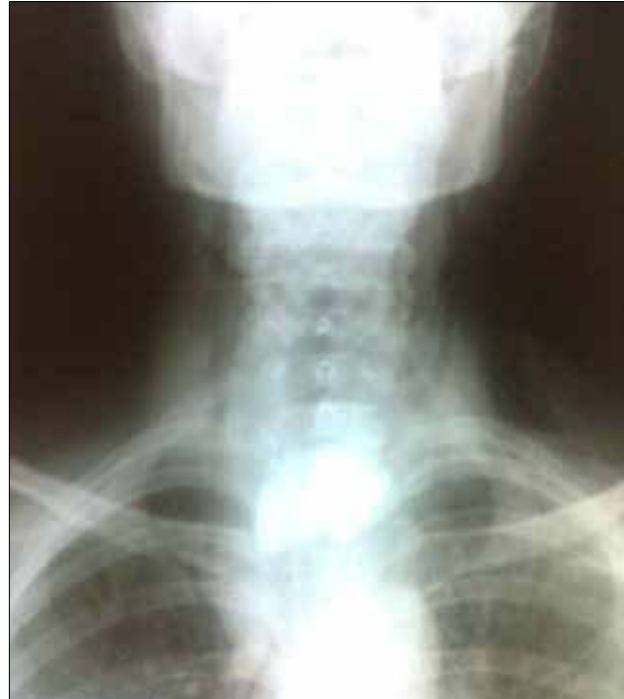

Figure 2. Cervical involvement on contrast X-ray

Figure 4. Endoscopic view on postoperative 11<sup>th</sup> day

demonstrate an immobile filling defect in the images obtained at different periods. The loss of regularity of contours in the inner side of the pouch should raise suspicion of carcinoma (7). The barium x-ray image of our patient showed contrast material accumulation within the pouch. Endoscopic examination is not routine due to the risk of perforation. We performed esophagoscopy in our patient at the diagnostic stage and in the aftermath in order to control the treatment. Computerized neck tomography, neck ultrasonography and esophageal manometric examinations are studies that are less preferred. The cervical tomography of our patient revealed the perforated diverticulum with irregular contours as well as subcutaneous emphysema. Endoscopic procedures are the most frequent cause of iatrogenic esophagus perforations, and the cricopharyngeal area is the most often injured site. In our case, a nasogastric tube-related perforation was observed. Subcutaneous emphysema is often seen in cervical perforations (1).

In our case, subcutaneous emphysema was identified in the clinical examination, thoracic tomography scan and direct pulmonary x-ray. Morbidity and mortality rates increase as the perforation advances towards the thorax. The chance for survival is 94% among patients with cervical esophagus perforation, 60% in patients with thoracic esophagus perforation and 71% in patients with abdominal esophagus perforation (3). The mortality rate of non-operative treatment of esophagus perforations is 20-38% however, this rate may come close to zero in well-selected patients (4). The criterion proposed by Cameron et al. (5) for non-operative treatment is a contained leak in a stable patient without sepsis, pleural or peritoneal cavity communication. We decided to treat the perforation in our case conservatively, since it was in the cervical region and the overall condition of the patient was good. The oral feeding was discontinued, fluids and antibiotics were administered intravenously. Recovery was seen in the clinical results, the emphysema regressed and CRP began to decrease. The patient started oral intake on the ninth post-operative day, and was discharged without any problems on the 13<sup>th</sup> post-operative day. The development of signs and symptoms related to sepsis during non-operative treatment requires emergency surgical treatment. The other indications for surgical intervention include pneumothorax, mediastinal emphysema and respiratory failure.

#### CONCLUSION

Zenker's diverticulum is quite rare. It is the most frequently seen diverticulum of the esophagus, and is treated with cricopharyngeal myotomy and diverticulotomy or diverticulopexy.

Majority of esophagus perforations are iatrogenic. Non-operative treatment should be considered as an alternative for se-

lected patients with cervical esophagus Zenker's diverticulum perforation.

**Informed Consent:** Written informed consent was obtained from patient who participated in this case.

**Peer-review:** Externally peer-reviewed.

**Conflict of Interest:** No conflict of interest was declared by the authors.

**Financial Disclosure:** The authors declared that this study has received no financial support.

#### REFERENCES

1. Townsend CM, Beauchamp RD, Evers BM, Mattox KL. Sabiston Textbook of Surgery. 17th ed. Saunders, 2004: 1104-1108.
2. van Overbeek JJ. Pathogenesis and methods of treatment of Zenker' diverticulum. *Ann Otol Rhinol Laryngol* 2003; 112: 583-593. [\[CrossRef\]](#)
3. Bufkin BL, Miller JJ Jr, Mansour KA. Esophageal perforation: Emphasis on management. *Ann Thorac Surg* 1996; 61: 1447-1451. [\[CrossRef\]](#)
4. Altörjay A, Kiss J, Vörös A, Bohák A. Nonoperative management of esophageal perforations. Is it justified? *Ann Surg* 1997; 225: 415-421. [\[CrossRef\]](#)
5. Cameron JL, Kieffer RF, Hendrix TR, Mehigan DG, Baker RR. Selective nonoperative management of contained intrathoracic esophageal disruptions. *Ann Thorac Surg* 1979; 27: 404-408. [\[CrossRef\]](#)
6. Fırat Ö. Zenker diverticulum. *Güncel Gastroenteroloji* 2010; 14: 134-137.
7. Teke Z, Bostancı EB, Aksoy E, Ulaş M, Dalgıç T, Atalay F, et al. Surgical treatment of Zenker diverticulum. *Ulusal Cer Derg* 2010; 26: 73-78.
8. Akın M, Anadol AZ, Kurukahvecioğlu O, Bostancı H, Tezel E, Çiftçi Ç. Zenker diverticulum: Case series. *Yeni Tıp Dergisi* 2008; 25: 86-88.