



Giant colon lipoma

Ismail Yaman¹, Hayrullah Derici¹, Gülen Demirpolat²

ABSTRACT

Colon lipomas are rare, non-epithelial tumors. They are generally smaller than two centimeters and asymptomatic, they are incidentally diagnosed and do not require treatment. Large and symptomatic colon lipomas are rather rare. Its differential diagnosis is generally made by histopathological examination of the resected specimen. A fifty-year-old female patient presented with the symptoms of abdominal pain, swelling in the abdomen and loss of weight. During colonoscopy, there was a submucosal mass of 8x6 cm, which almost completely obstructed the lumen in the hepatic flexure and was covered by a mucosa that was sporadically ulcerated and necrotic in nature. In magnetic resonance imaging, an ovoid mass with a diameter of 8.5 cm at its widest dimension was detected, which had signal intensity similar to that of adipose tissue. Since the patient was symptomatic and differential diagnosis could not be made, she underwent laparoscopic right hemicolectomy. A submucosal lipoma was detected on histopathological examination of the specimen. The patient was discharged without any problems on post-operative day 7. Definitive diagnosis of lipomas before surgery is challenging; they may be mistaken for malignancy, especially if the lesion is large and ulcerated. For large and symptomatic colon lipomas, surgery is required to both prevent complications and rule out malignancy.

Keywords: Colon, lipoma, colonoscopy

INTRODUCTION

Colon lipomas are rare, benign, non-epithelial tumors (1). Their frequency is reported as 0.035-4.4%. Approximately 90% of them originate from the submucosa, while 10% arise from subserosa (2-5). Lipomas are generally small, asymptomatic and are located in the cecum and ascending colon (6, 7). Such lipomas are diagnosed incidentally and do not require treatment (4). On the other hand, they may rarely result in symptoms such as abdominal pain, hemorrhage, changes in bowel movements and loss of weight, especially if they are larger than 2 cm (3). In spite of developments in imaging methods and endoscopic interventions, definitive diagnosis is difficult in the preoperative period. Since a differential diagnosis from malignancy cannot be made in cases of large colon lipomas, large-scale surgeries may be conducted and generally, definitive diagnosis can only be made after histopathological examination of the resected specimen (1, 2, 6, 7).

In this study, a case of hepatic flexure colonic lipoma characterized by being large and symptomatic is presented.

CASE PRESENTATION

A fifty-six-year-old female patient presented to our outpatient clinic with symptoms of abdominal pain and distension, which had been continuing for one year with an increase in the past three months, as well as loss of weight by 8 kg in the last three months. Her routine laboratory values were within normal ranges. She did not have any problem in her personal and family histories. According to her physical examination, no signs other than a slight distention in the entire abdomen were encountered. Her abdominal ultrasonography was normal. She had antral erosive gastritis on gastroscopy. During colonoscopy, a submucosal mass of 8x6 cm that almost completely obstructed the lumen at the hepatic flexure with extension into the transverse colon was observed. It was covered by a mucosa that was partially ulcerated and necrotic in nature (Figure 1a, b). Button-hole-like biopsies were collected from the area around the ulcerated mucosa and intact mucosa to be able to access the mass. The biopsy result was reported as regenerated mucosa containing ulceration. The upper abdominal computerized tomography (CT) showed a well-delineated, ovoid mass adjacent to the transverse colon (external compression). In magnetic resonance imaging (MRI) of the upper abdomen, an ovoid mass was present at the proximal transverse colon with a diameter of 8.5 cm at its widest dimension, which had signal intensity similar to that of adipose tissue (Figure 2). The findings were in favor of lipoma. Since the mass had large dimensions, almost completely blocked the colon, the patient was symptomatic, the mucosa covering the mass seemed irregular and necrotic in colonoscopy and the diagnosis could not be histologically ascertained, the patient was planned for surgery. She underwent laparoscopic right hemicolectomy. The

¹Department of General Surgery, Balıkesir University Faculty of Medicine, Balıkesir, Turkey

²Department of Radiology, Balıkesir University Faculty of Medicine, Balıkesir, Turkey

Address for Correspondence Dr. İsmail Yaman

Balıkesir Üniversitesi Tıp Fakültesi, Genel Cerrahi Anabilim Dalı, Balıkesir, Türkiye
Phone: +90 266 245 44 25
e-mail: ismailyaman35@gmail.com

Received: 18.02.2012

Accepted: 16.07.2012

Online Available Date:
28.05.2013

©Copyright 2015

by Turkish Surgical Association

Available online at
www.ulusalcerrahidergisi.org

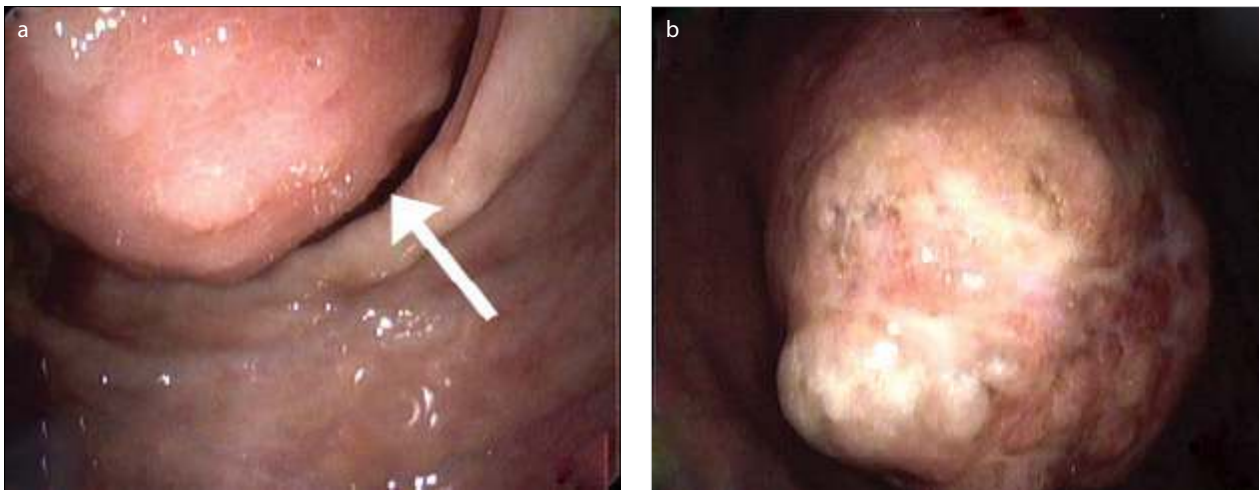


Figure 1. a,b. (a) Colonoscopic view of the mass, the arrow is directed to the lumen, (b) Colonoscopic view of the mass, ulcerated lesion

pathologic examination revealed a submucosal lipoma, which was covered by a mucosa that appeared to have areas of ulcer and necrosis. The patient did not develop any problems following surgery and was discharged on post-operative day 7.

DISCUSSION

Colon lipomas are rare, slow-growing, non-epithelial benign tumors of the gastrointestinal system (1, 3, 6). Bauer et al. (4) originally described this entity. It is observed more frequently among women, in the fifth and sixth decades (4, 5, 7, 8). 70-90% is located in the right colon. The other sites are transverse colon including both flexures, descending colon, sigmoid colon and rectum in decreasing order (7, 8). It is generally single; however, multiple lipomas may be seen in 6-25% of cases (1-3). Our patient was comparable to the literature in terms of age, sex, having a single mass and location in submucosa whereas lesion site differed.

Colon lipomas are generally small and asymptomatic (1-5). For that reason, they are incidentally identified during imaging studies, colonoscopy, surgery or autopsy (1, 2, 7). They trigger symptoms once they reach large sizes, especially when they are larger than 2 cm (1, 2, 5, 7). Only 25% of them are symptomatic and the most frequent symptoms include abdominal pain, rectal bleeding and changes in bowel movements (1, 2, 4, 9). Our patient presented with symptoms of colic-like abdominal pain and abdominal distension. The lipoma in our case had a diameter of 8.5 cm at its widest dimension. Our case is one of the rare cases in the literature, since the lipoma diameter was larger than 8 cm.

For clinicians, the diagnosis of colon lipomas in the pre-operative period is challenging (8). A definitive diagnosis can generally be made following an intervention (1, 2, 6, 7). The imaging methods may aid in diagnosis; however, the signs are generally not specific (1). Barium x-ray may demonstrate signs of well-delineated, radiolucent, oval filling defect and "constriction-contusion" secondary to peristalsis (1, 6, 8). Ultrasonography shows a hyperechoic lesion with no internal vascularity (7). Endoscopic ultrasonography is a complementary study and it shows the spread into muscularis propria (7). As a characteristic sign in CT, an intraluminal mass with regular,

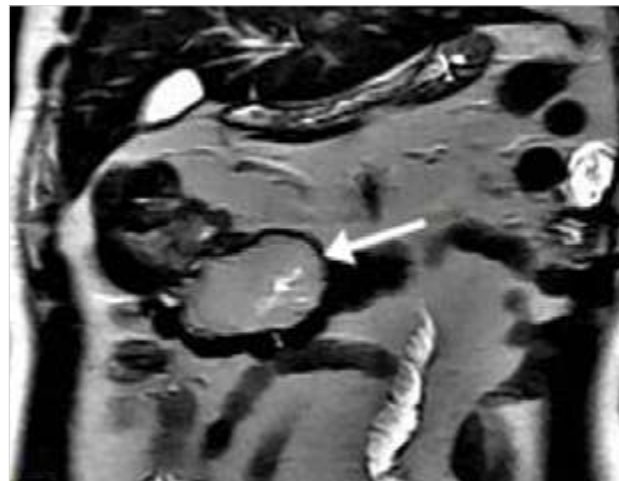


Figure 2. Magnetic resonance imaging view of the lesion, arrow pointing the mass

ovoid and sharp borders at a homogeneous fat density may be described (6-8). In MRI, the signal intensity of adipose tissue and suppression of signal in fat-suppressed sequences may be seen; therefore, MRI may be especially beneficial in the detection of lipomas (1, 7). The abdominal ultrasonography result of our patients was normal. According to her CT scan, an ovoid and well-delineated mass that was interpreted as being adjacent to the transverse colon was present. The MRI scan detected a mass with a diameter of 8.5 cm at its widest dimension, which had signs consistent with lipoma.

In colonoscopy, lipomas are generally seen as yellowish polyps that are flat, have a pedicle or a large base, which are covered by a smooth mucosa (6). Typically, cushion sign (a cushion-like collapse once the biopsy forceps is pressed down), tent sign (a tent-like appearance once the covering mucosa is lifted with a forceps) and exposed fat sign (yellowish fat exposed at the biopsy site) may be seen (1, 2, 9). In that respect, colonoscopy is reliable for the diagnosis of classical lipomas; however, diagnosis is difficult in cases of atypical callous or ulcerated lesions (2, 7). It is not possible to rule out malignancy in such types of lipomas and a definitive diagnosis can be made in the post-operative period following a pathological examination of the resected segment (1, 2, 6, 7). Our patient had a mass with a

superficially necrotic mucosa, which obstructed the colon almost entirely, which had ulcerations in various sites and which was hard in nature in many sections. The result of the biopsies was reported as ulcerated, regenerated mucosa and no definitive diagnosis could be made in the pre-operative period.

Endoscopic removal or surgical intervention is recommended for the treatment of colon lipomas, depending on the lipoma diameter, presence of a pedicle, suspicion of malignancy, as well as association with the muscular and serosa layers (2, 3). It is reported that colonoscopic removal of lipomas is a reliable therapeutic method especially in those that originate in the submucosa and grow towards the lumen, have pedicles and are especially smaller than 2 cm (3, 6). To be able to understand the association between lipoma and muscularis propria and serosa, it is recommended that endoscopic ultrasonography should be performed (1). Jiang et al. (2) examined this issue in five aspects and recommended that endoscopic removal would not be appropriate in the following cases: a) lipoma is larger than four cm, sessile or has a limited pedicle, b) malignancy is suspected, c) intussusception is present, d) it involves the muscular layer or serosa, e) it cannot be radically removed at colonoscopy. Although there are publications in the literature reporting that lipomas with wide pedicles and large diameters may also be endoscopically removed, it should be kept in mind that the risk of perforation and bleeding in such types of lipomas is high (1, 2, 9, 10). For surgical treatment, several interventions may be implemented ranging from local excision to segmental resection and hemicolectomy depending on if a definitive diagnosis can be made in the pre-operative period (1-3, 5, 7, 8). If the diagnosis can be verified in the pre-operative period, the size of surgery may be restricted and adequate treatment through enucleation or local excision may be ensured (6, 7). If the diagnosis is suspicious or there are complications such as intussusception, large-scale surgeries such as hemicolectomy or subtotal colectomy may be necessary (3). Even though surgery can be performed via conventional laparotomy and mini-laparotomy, laparoscopic colon surgery is recommended if the conditions are suitable (7). Since the mass in our patient had large dimensions, did not have an appropriate pedicle and the mucosa on the mass had foci of ulceration and necrosis, it was considered that an endoscopic removal procedure would not be appropriate and the decision for surgery was taken. Since the diagnosis could not be ascertained and malignancy could not be ruled out in the pre-operative period, the patient underwent laparoscopic right hemicolectomy.

CONCLUSION

Colon lipomas are rare, benign, non-epithelial tumors. Definite diagnosis of lipomas before surgery is challenging; they may be mistaken for malignancy, especially if the lesion is large and ulcerated. For large and symptomatic colon lipomas, surgery is required to both prevent complications and rule out malignancy.

Peer-review: Externally peer-reviewed.

Author Contributions: Study concept and design - İ.Y., H.D.; Acquisition of data - İ.Y., H.D., G.D.; Analysis and interpretation of data - İ.Y., H.D., G.D.; Preparation of the manuscript - İ.Y.

Conflict of Interest: No conflict of interest was declared by the authors.

Financial Disclosure: The authors declared that this study has received no financial support.

REFERENCES

1. Mnif L, Amouri A, Masmoudi MA, Mezghanni A, Gouiaa N, Boudawara T, et al. Giant lipoma of the transverse colon: a case report and review of the literature. *Tunis Med* 2009; 87: 398-402.
2. Jiang L, Jiang LS, Li FY, Ye H, Li N, Cheng NS, et al. Giant submucosal lipoma located in the descending colon: a case report and review of the literature. *World J Gastroenterol* 2007; 13: 5664-5667.
3. Dandin Ö, Balta A.Z, Sücüllü İ, Yücel E, Yıldırım Ş. A rare cause of abdominal pain and anemia: giant colonic lipoma. *Kolon Rektum Hast Derg* 2011; 21: 116-119. [\[CrossRef\]](#)
4. Küçük Ü, Özer E, Anuk T. Rectal submucosal lipoma: case report. *Türk Patoloji Dergisi* 2009; 25: 47-49.
5. Sabancı Ü. Colo-colic invagination causing acute abdomen: A case with lipoma. *Kolon Rektum Hast Derg* 2007; 17: 151-153.
6. Zhang X, Ouyang J, Kim YD. Large ulcerated cecal lipoma mimicking malignancy. *World J Gastrointest Oncol* 2010; 2: 304-306. [\[CrossRef\]](#)
7. Arora R, Kumar A, Bansal V. Giant rectal lipoma. *Abdom Imaging* 2011; 36: 545-547. [\[CrossRef\]](#)
8. Erkan N, Çalıřkan C, Vardar E. Lipoma of the large intestine: a clinicopathological review of six cases. *Balkan Med J* 2010; 27: 6-10.
9. Martin P, Sklow B, Adler DG. Large colonic lipoma mimicking colon cancer and causing colonic intussusception. *Dig Dis Sci* 2008; 53: 2826-2827. [\[CrossRef\]](#)
10. Morimoto T, Fu KI, Konuma H, Izumi Y, Matsuyama S, Ogura K, et al. Peeling a giant ileal lipoma with endoscopic unroofing and submucosal dissection. *World J Gastroenterol* 2010; 16: 1676-1679. [\[CrossRef\]](#)