



# A rare cause of acute abdomen in a young patient: Cecal volvulus

Yiğit Mehmet Özgün

## ABSTRACT

Cecal volvulus is an uncommon cause of intestinal obstruction and acute abdomen. Previous laparotomy and pregnancy may increase the predisposition to cecal volvulus. Delays in diagnosis cause serious outcomes. Treatment of the disease depends on the patient's status. In this case, a 23 year old woman with no previous history of laparotomy presented with acute abdomen. Immediate laparotomy was done and a cecal volvulus was encountered. There was no perforation or faecal contamination. Right hemicolectomy and end-to-side ileotransversostomy were performed on the patient and she was discharged uneventfully on the sixth postsurgical day.

**Keywords:** Cecum, volvulus, intestinal obstruction, acute abdomen

## INTRODUCTION

Acute cecal volvulus is an emergent surgical pathology that may progress to acute fulminant presentation through strangulation and perforation (1). Since cecal volvulus, which constitutes less than 1% of intestinal obstructions, causes closed loop obstruction, delay in diagnosis leads to high morbidity and mortality rates (2, 3). Apart from the anatomic mobility of cecum, which may be seen in 10-20% of the population in cadaver studies, factors such as previous surgeries and pregnancy may also result in cecal volvulus (4).

## CASE PRESENTATION

A twenty-three-year-old female patient was referred to our hospital's emergency service, she had been under follow-up for lower right quadrant pain, nausea and vomiting for 3 days at another institution. Her blood pressure was 100/60 mm-Hg, heart rate: 80/min, and temperature: 38.4°C. There was a palpable mass in the right lower quadrant of the abdomen causing asymmetry, as well as signs of peritonitis in that quadrant. She did not have diffuse peritonitis and there were a few air fluid levels corresponding to small intestine on direct abdominal x-ray. The leukocyte count was  $22.7 \times 10^3/\mu\text{L}$ , Hb: 12.9 g/dL, neutrophil:  $8.8 \times 10^3/\mu\text{L}$  and her biochemical parameters were normal. The abdominal ultrasonography revealed her appendix lumen diameter as 11 mm, with wall thickening and free intra-abdominal fluid. The patient was planned for an emergent surgery with the preliminary diagnosis of perforated and plastron appendicitis with abscess. During the exploration performed via Mc Burney incision, it was seen that the cecum was dilated and gangrenous, and serosanguineous fluid was present in the abdomen (Figure 1). Since a resection may be required, the Mc Burney incision was closed, and a median laparotomy was performed. A cecum volvulus with impairment of terminal ileum mesentery was observed (Figure 2). The cecum and terminal ileum appeared non-viable and necrotic. A right hemicolectomy was performed together with 60-cm segment of the terminal ileum. The remaining ileum was decompressed, and it was seen that blood flow was sufficient at both ends. Since there was no perforation and fecal contamination within the abdomen, an end-side ileotransversostomy was performed. The patient was started on oral feeding on post-operative day 4 and she was discharged on day 6 without any problems.

## DISCUSSION

The frequency of cecal volvulus has been reported as one in 2.8-7.1 million per year, and it constitutes 1-1.5% of all bowel obstructions and 25-40% of all cases with colon volvulus (1). Generally, it develops due to a congenital incomplete dorsal mesenteric fixation of the cecum. It may also develop as a complication of left hemicolectomy, cholecystectomy, gastric resections, incarcerated femoral hernia repair, appendectomy, kidney transplantation, nephrectomy and several laparoscopic procedures (4). Pregnancy causes the cecum to migrate significantly, thereby creating a predisposition to volvulus. Our patient was a young female patient who did not have a previous history of pregnancy or past surgeries.

The diagnosis of cecal volvulus is generally non-specific; however, it may manifest as localized abdominal pain, distension and painful mass in the right lower quadrant. Radiology is important in the diagnosis of cecal volvulus. Radiologic signs indicating such a diagnosis include a coffee-bean appearance in

Clinic of General Surgery, Mardin State Hospital, Mardin, Turkey

**Address for Correspondence**  
Yiğit Mehmet Özgün

Mardin Devlet Hastanesi, Genel Cerrahi Kliniği, Mardin, Türkiye  
Phone: +90 482 213 52 29  
e-mail: dryigitozgun@gmail.com

Received: 02.01.2012

Accepted: 05.04.2012

Online Available Date:  
28.05.2013

©Copyright 2015

by Turkish Surgical Association

Available online at

www.ulusalcerahidergisi.org

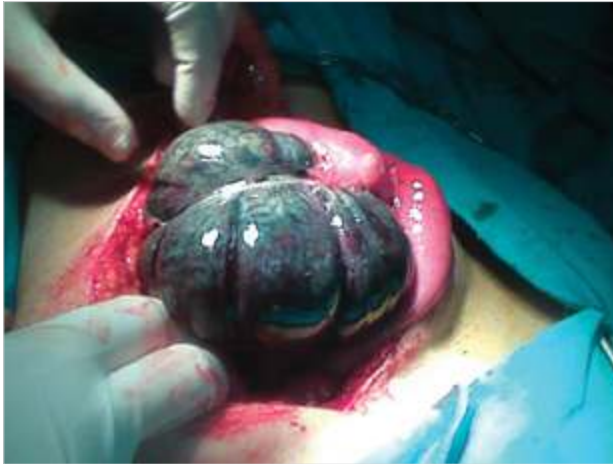

Figure 1. Cecal volvulus with gangrene

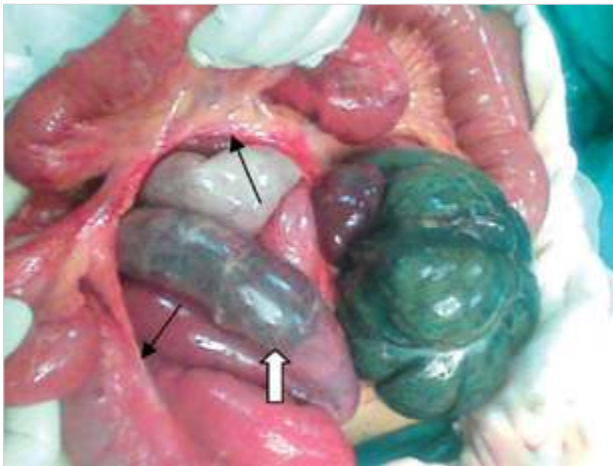


Figure 2. Ileal meso with destruction (black arrows) and ischemic ileal segment (white arrow)

the upper left quadrant on direct abdominal x-ray (in only 30% of cases), bird beak appearance in contrast x-ray and computerized tomography (CT). The coffee bean, bird beak and whirl signs on abdominal CT, the obstructed appearance of cecal mesentery and an appendix seemingly full of gas are pathognomonic for cecal volvulus (1, 4, 6).

In our case, the patient's clinical condition was poor; therefore, the decision was taken to perform emergency surgery as a result of laboratory and ultrasonographic evaluations. No advanced studies such as CT were performed. CT may result in delay in both diagnosis and treatment; however, it may guide pre-operative evaluations and the decision for correct incision. As in this case, it may be beneficial to use pre-operative abdominal CT to differentiate cecal volvulus and make a correct decision about incision especially in patients who have signs suggesting plastron appendicitis. O'mara et al. (5) presented a cecal volvulus series of 50 patients where they reported that patients generally presented with non-specific acute abdomen symptoms, more than half of these patients

were not diagnosed pre-operatively, and there was significant delay in diagnosis in 25% of patients (5).

Non-operative treatment options such as ingestion of barium enema and colonoscopic decompression, which are used for sigmoid volvulus, are not recommended for the treatment of cecal volvulus due to high rates of failure and perforation (1, 6). Treatment for acute cecal volvulus treatment without intestinal ischemia includes controversial therapies such as distortion, cecopexy and cecostomy as well as tube cecostomy, where the possibility of recurrence reaches 40% and mortality rate amounts to 18% (4, 6, 7). If intestinal viability is controversial, or if it is necrotic with gangrene or perforation then resection is necessary. The decision for primary anastomosis or ileostomy following resection is generally taken based on the patient's overall condition and degree of contamination (4, 6, 7). The risk of recurrence is eliminated via right hemicolectomy and it is therefore recommended for the treatment of cecal volvulus without gangrene (3). Since our patient was young, was hemodynamically stable, and did not have perforation or fecal contamination an anastomosis was performed following resection.

#### CONCLUSION

Cecal volvulus should be taken into consideration in young patients presenting as acute appendicitis along with significant leukocytosis and no past surgeries. In this manner, accurate pre-operative preparation and decision for incision type can be made. If gangrene is present in cecal volvulus, resection is a necessity. In stable patients without perforation and fecal contamination, right hemicolectomy and primary anastomosis is the choice of treatment according to many authors.

**Peer-review:** Externally peer-reviewed.

**Conflict of Interest:** No conflict of interest was declared by the author.

**Financial Disclosure:** The author declared that this study has received no financial support.

#### REFERENCES

1. Consorti ET, Liu TH. Diagnosis and treatment of caecal volvulus. *Postgrad Med J* 2005; 81: 772-726. [\[CrossRef\]](#)
2. Browne N. Cecal volvulus in adolescence presenting as recurring visits for abdominal pain. *West J Emerg Med* 2010; 11: 202-204.
3. Hasdemir AO, Kordon Ö, Çakmaz R, Türkeli V, Çöl C. Acute right colonic volvulus: case report. *Türkiye Acil Tıp Dergisi* 2009; 9: 134-137.
4. Scott CD, Trotta BM, Dubose JJ, Ledesma E, Friel CM. A cruel twist: post-operative cecal volvulus. *Ulus Travma Acil Cerrahi Derg* 2008; 14: 158-162.
5. O'Mara CS, Wilson TH Jr, Stonesifer GL, Cameron JL. Curr. Cecal volvulus: analysis of 50 patients with long-term follow-up. *Surg* 1980; 37: 132-136.
6. Madiba TE, Thomson SR. The management of cecal volvulus. *Dis Colon Rectum* 2002; 45: 264-267. [\[CrossRef\]](#)
7. Eng M, Ravindra K. Cecal volvulus following laparoscopic nephrectomy and renal transplantation. *JLS* 2009; 13: 612-615. [\[CrossRef\]](#)