

Diagnostic value of terminal ileum biopsies in patients with abnormal terminal ileum mucosal appearance

Mehmet Velidedeoğlu, A. Enes Arıkan, A. Kağan Zengin

ABSTRACT

Objective: To investigate the necessity of obtaining routine ileal biopsy during colonoscopy in the patients with abnormal terminal ileum mucosal appearance if the inflammatory bowel disease is not considered.

Material and Methods: A retrospective analysis was performed for 57 patients who were referred to a private hospital for colonoscopy between January 2008 and February 2009, in whom terminal ileum intubation was achieved and an abnormal appearance was observed.

Results: There were 33 men and 24 women; the mean age was 44.12 ± 11.42 years. In 22 patients, the abnormality was ulcers and/or erosions. In 10 patients, there were mucosal nodularity and in 24, the finding was erythema. The time to reach to ileum from cecum was 28.78 ± 24.30 s. The mean length of the examined ileum was 12.93 ± 6.05 cm. There was no difference between groups according to distance covered in the ileum for diagnostic yield, but going further than 2 cm was important.

Conclusion: There should be no need to obtain routine biopsy in patients with abnormal terminal ileum mucosa appearance, when inflammatory bowel disease is not considered. In these patients, histopathology also reveals non-specific ileitis. Furthermore, in these patients, the macroscopic pathological diagnosis overlaps the histopathology, and it has a low diagnostic yield and lower clinical significance.

Keywords: Colonoscopy, terminal ileum, biopsy

INTRODUCTION

Since Nagasako, et al. (1) have reported a successful ileal intubation, ileoscopy became an important complement to colonoscopy, particularly in patients with inflammatory bowel disease, diarrhea, malignant lymphoma of small bowel, and cytomegalovirus ileitis (2-4). In some cases, ileal biopsy is an absolute and only way to diagnose inflammatory small bowel disease (2, 4-12). However, it is rarely used (only in 5% of colonoscopy examinations) in clinical practice (13, 14) because of a difficulty in the intubation of the ileocecal valve, requirement of extra time, and not being worthwhile for performing on all patients (14). Complete examination in a colonoscopy report is required by quality assurance. Although the only certain way to prove that a complete examination was performed is to obtain an ileal biopsy, current guidelines of American Society for Gastrointestinal Endoscopy (ASGE) suggests photography and endoscopic visualization of cecal landmarks, including the triradiate fold, appendiceal orifice, and ileocecal valve in colonoscopy reports (3, 15). In some studies, there was a significant contrast between the photograph observers at the point of recognizing the cecal landmarks (16, 17). In case of uncertainty for cecal viewing, the lips of the ileocecal valve or to intubate the terminal ileum would be required.

Ileoscopy procedure improves and maintains endoscopic skills and does not markedly affect the overall endoscopy time; however, it has a risk of iatrogenic prion transmission that may lead to variant Creutzfeldt-Jacob disease (18-23). As the diagnostic yield of routinely acquired ileal biopsy is too low (the detection rate of significant pathology is between 2% and 7% in unselected patients), £ 240 for obtaining and analyzing tissue samples will be unacceptable (7, 18, 19, 24, 25). At present, only capturing a photo of the ileal villi, not obtaining biopsy is an alternative way as an evidence of completing the procedure. Further, there should be no need for obtaining routine biopsy in patients with abnormal terminal ileum mucosal appearance if the inflammatory bowel disease is not considered. Thus, in these patients, the macroscopic pathological diagnosis overlaps the histopathology (20). The aim of the study is to investigate the necessity of routine terminal biopsy in patients with abnormal terminal ileum mucosal appearance if the inflammatory bowel disease is not considered.

MATERIAL AND METHODS

This study was a retrospective analysis of the patients who were referred to a private hospital for colonoscopy between January 2008 and February 2009, in whom terminal ileum (TI) intubation was achieved and an abnormal appearance was observed. There were 57 patients aged 18 years or more. All patients

Department of General Surgery,
İstanbul University Cerrahpaşa
Faculty of Medicine, İstanbul,
Turkey

Address for Correspondence

Mehmet Velidedeoğlu
İstanbul Üniversitesi Cerrahpaşa Tıp
Fakültesi, Genel Cerrahi Anabilim
Dalı, İstanbul, Türkiye
Phone: +90 212 414 30 00
e-mail:
mvelidedeoğlu@yahoo.com

Received: 19.04.2014

Accepted: 21.12.2014

Available Online Date: 09.04.2015

©Copyright 2015

by Turkish Surgical Association

Available online at

www.uluscerrahidergisi.org

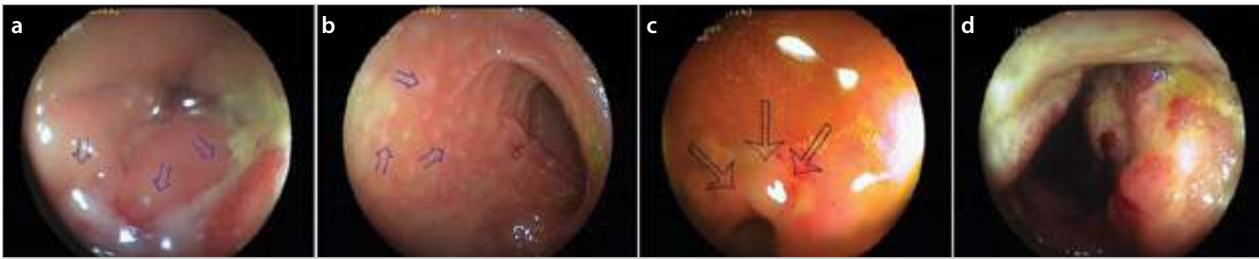


Figure 1. a-d. Macroscopic findings of an abnormal mucosal appearance observed in ileoscopy
 Arrows indicate the detected lesions during endoscopy in each picture. Inflammation and ulcerated lesions of Crohn's disease (a). Lymphoid hyperplasia (non-specific ileitis) (b). Aphthous ulcers observed in ulcerative colitis with backwash ileitis (c). Ileal tuberculosis (d)

Table 1. Indications for colonoscopy and their properties

Indication	No. of patients	Diagnostic yield	Clinically significant
Diarrhea*	19	6	1
Rectal bleeding	14	1	0
Rectal mucous discharge	3	0	0
Abdominal pain	14	0	0
Abdominal bloating	10	0	0
Constipation	6	1	0

*The patient with clinically significant diagnostic yield end-up with ileal tuberculosis

underwent ileocolonoscopy under conscious sedation with intravenous 2-5 mg midazolam and 20–50 mg pethidine together. Bowel preparation was achieved using oral 90 mL Fleet Phospho-soda (sodium dihydrogen phosphate and disodium phosphate dodecahydrate solution) and enema. The same endoscopist performed all ileocolonoscopy examinations. Total colonoscopy together with TI intubation, photography, and biopsy was completed in all enrolled patients. Furthermore, data was obtained from medical records and computerized endoscopy database. The clinical symptoms, indications, and findings of the procedure, pathology reports of colonic, and TI samples were recorded. The symptoms of the patients having abnormal histopathological findings were reviewed to investigate how such findings change the management of the clinician.

An endoscopic procedure was considered as abnormal when one or more of the following criteria were observed: ileitis (erythema, fragility, granularity, erosions, and/or ulcers), aphthous ulcers or erosions, nodular or erythematous mucosa, and polypoid lesions. Abnormal findings leading to a new diagnosis are accepted as clinically important.

Colonoscopy was performed using Fujinon EPX-2500 (Fujifilm, USA) video colonoscopies with the single-handed technique. The cecum was identified by a combination of transillumination and visual identification. After the TI was intubated, the colonoscope was advanced into the TI as far as possible. The time to reach the ileum from the cecum and the length of the examined ileum segments were recorded. TI intubation was then measured while withdrawing the colonoscope by calculating the distance covered by the tip of colonoscope from the

farthest point in the ileum to the ileocecal valve. There were no complications associated with ileoscopy.

This study was performed according to World Medical Association's Declaration of Helsinki in 1995 (as revised in Tokyo 2004); a written informed consent was obtained from all patients.

Statistical Analysis

Values associated with continuous variables were denoted as mean±standard deviation and analyzed by Student's t-test. For non-continuous variables, Pearson's chi-square test was performed for significance. It was accepted as significant if the p-value was <0.05.

RESULTS

Fifty-seven patients met the requirements for this study. There were 33 (58%) men and 24 (42%) women; the mean age was 44.12±11.42 years (range, 18-76 years). The mean age was 42.92±11.4 years for females and 45±11.52 years for males. Some patients had more than one indication. The most common indication was diarrhea, present in 22 (39%) patients. Other indications were rectal bleeding (16 patients, 28%), mucoid rectal discharge (3 patients, 5%), abdominal pain (15 patients, 26%), abdominal bloating (10 patients, 18%), and constipation (3 patients, 5%). Macroscopic abnormalities revealed by ileoscopy included ulcers, aphthous ulcers or erosions, nodular or erythematous mucosa, and polypoid lesions. Further, in 22 (39%) of these cases, the abnormality was ulcers and/or erosions. In 10 (18%) cases, there were mucosal nodularity, and in 24 (42%) patients, the finding was erythema (Figure 1). Lesions and diagnostic yield is shown in Table 1. Polypoid lesions were observed in one (2%) case. The time to reach the ileum from the cecum was 28.78±24.30 seconds (range, 2-120 seconds). During ileal intubation, the closest point was 2 cm, and the farthest point in the ileum was 30 cm from the ileocecal valve. The mean length of the examined ileum was 12.93±6.05 cm. There was no difference between each groups according to distance covered in the ileum for diagnostic yield (p=0.086), but going further than 2 cm was significant (p=0.013). Moreover, clinical significance was observed between the groups in terms of the distance covered in the ileum (p=0.655) (Table 2).

DISCUSSION

The patients having diarrhea for more than six months with an unknown etiology, such as Crohn's disease, in which the ileum is affected, are candidates for capsule endoscopy;

Table 2. Diagnostic yield and clinical significance in each group according to distance covered in ileum

Distance covered in ileum	Number of patients	Diagnostic yield (and location*)	Number of clinically significant patients	Clinically significant diagnosis
0–2 cm	1	1 (E)	0	
3–5 cm	7	1 (E)	0	
6–14 cm	27	4 (E, E, E, E)	0	
15 cm and above	22	2 (5 th , 15 th cm)	1	Ileal tuberculosis

*Distance covered after terminal intubation in centimeters. E: entrance level (first 2 cm)

however, ileal biopsy is not possible in this procedure (26). Complete enteroscopy may overcome this issue. However, therapeutic procedures require patience and advanced skill of the endoscopist (27). In this aspect, ileoscopy, as an adjunct to colonoscopy, is critically important in patients considering inflammatory bowel disease or diarrhea, otherwise there is no exact benefit of ileoscopy for unselected patients as the requirement of extra time and cost for histopathological evaluation was considered (7, 9, 11, 12, 14). However, in accordance with recommendations by ASGE, a complete examination of the colon in all colonoscopies for the quality assurance can be achieved by the visualization and photodocumentation of the cecum, whereas these may not be convincing in all patients. Therefore, obtaining the biopsy of the terminal ileum is the most certain and objective way, indicating that a complete colonoscopy was performed (1, 2, 4, 28, 29). A study evaluating the patients with colon cancer mostly in the cecum or ascending colon revealed that those patients had a normal colonoscopy report within the previous three years. Because of not reaching the cecum, possibly the tumors were missed (30).

Regardless of the symptom or clinical indication, the diagnostic yield of ileal biopsy in patients having abnormal macroscopic appearance remains controversial. A study detected clinically significant pathology only in 8.8% of the patients having macroscopic abnormalities (31), whereas positive macroscopic findings on ileoscopy were found to be clinically significant for changing the treatment strategy in half of the patients in a recently published study (29). In contrast, in this study, in 49 of the 57 patients (86%) with positive macroscopic findings on ileoscopy, there were non-specific histological findings not believed to be clinically significant, including non-specific inflammation (mostly chronic nonspecific ileitis, active or not), lymphoid hyperplasia, and low grade mucosal damage. A clinically significant histopathology was present only in one (2%) patient who had ileal tuberculosis. Further, four patients were diagnosed with Crohn's disease and four with backwash ileitis; however, these diagnoses were not significant (Figure 1). Because even these histopathological results belonged to ileal specimens, the same diagnosis could be determined by examining the colonic biopsies in the same patients. Therefore, ileal biopsies did not provide any additional

information. Apart from the clinical significance, Crohn's disease was considered in one patient according to the macroscopic findings, which was later confirmed by histopathology. Backwash ileitis was diagnosed in seven patients; in four of them, the diagnosis was correct according to histopathology. However, in one of them, the diagnosis was tuberculosis. In two patients, inflammatory bowel disease was diagnosed according to the histopathological results; however, endoscopic diagnosis revealed non-specific ileitis.

As the ileum has a smaller diameter, tortuous structure, and excessive mobility, gentle manipulation and a high control of insufflation is required to avoid perforation; thus, it is possible in rare cases of diverticula. Similarly, excessive air insufflation of the cecum as a result of persistent attempts for intubating may cause small-bowel ileus (32-35). However, no complications occurred associated with ileoscopy. Although it is reported that ileoscopy could be accomplished within 3-4 min in 79% patients (18), our results revealed a sharp shorter intubation time as an average of 28.178±24.30 s. More than 750 procedures are accepted to be enough to achieve 85% success rate for intubating terminal ileum (19); however, we reached this ratio at a lesser number of procedures. Although there are past published reports explaining the procedure time and median length of the examined ileum (20, 36), the question how far the endoscopist is required to proceed after terminal ileal intubation has never been asked and argued before. After discovering an ileal lesion, generally biopsy is taken and no further steps are taken if a normal mucosa is observed. The possibility of a second and more important lesion further that may lead a new diagnosis or change the treatment remains uncertain. In this study, ileum length of 2 cms were mostly (71.92%) detected; however, the most diagnostic yield (four of the eight) was observed in five patients whose 6–14 cm of ileum from the ileocecal valve were examined. In this group, all abnormal findings were observed at the entrance of the terminal ileum, and thus, they were not beneficial. The abnormal findings in 0–2-cm and 3-5 cm groups were observed at the entrance of the ileum as well. However, only one case was diagnosed as ileal tuberculosis, which had a clinically significant diagnostic yield, amongst four patients in whom more than 15 cm of the ileum from the ileocecal valve was examined. In this group, two patients had their first lesions at the entrance of the ileum, at 25th cm in one patient, and at 20th cm in another. However, the second lesions did not play any role in deciding diagnosis and treatment because both lesions had no diagnostic yield. In one of the two patients having diagnostic yield in this group, the lesion was at 5th cm, therefore, going 15 cm further did not provide any benefit. So far, it appeared that going further after discovering a lesion was not very beneficial. In contrast to the ileal tuberculosis case, which had a clinically significant diagnostic yield, an ulcer was observed in the entrance of the ileum, which had no pathologically verified value. The diagnosis was conducted by evaluating a second lesion at 15th cm.

CONCLUSION

Our results indicate that routine ileoscopy is a safe, easy to perform, and objective evidence that a complete examination of the colon is performed, without markedly prolonging

the total procedure and causing any extra cost; furthermore, it maintains the skills of the endoscopist. However, there should be no need to obtain routine biopsy in the patients with abnormal terminal ileum mucosal appearance if the inflammatory bowel disease is not considered. Thus, in these patients, the macroscopic pathological diagnosis overlaps with histopathology, and it has a low diagnostic yield and a lower clinical significance. Further, the abnormal findings that lead to a diagnostic yield were mostly observed at the entrance of the ileum in our patients. Although examining the entrance and not forcing to go further, particularly if lesion is detected in the ileum was not the primary aim, it seemed adequate. However, future randomized prospective trials are required in higher number of patients having abnormal ileal mucosal appearance for assessing the diagnostic value of ileum biopsies, how far the endoscopist is required to go forward, and the frequency of a second or third lesion, and if it has a clinically significant diagnostic yield or not considering the low patient number in this study.

Ethics Committee Approval: Because this is a retrospective study, no ethical approval was sought.

Informed Consent: Written informed consent was obtained from patient who participated in this study.

Peer-review: Externally peer-reviewed.

Author Contributions: Concept - M.V., A.K.Z., A.E.A.; Design - M.V., A.K.Z.; Supervision - A.K.Z., M.V.; Funding - M.V.; Materials - M.V.; Data Collection and/or Processing - M.V.; Analysis and/or Interpretation - M.V.; Literature Review - A.E.A.; Writer - M.V., A.K.Z.; Critical Review - M.V., A.K.Z.

Conflict of Interest: No conflict of interest was declared by the authors.

Financial Disclosure: The authors declared that this study has received no financial support.

REFERENCES

- Nagasako K, Yazawa C, Takemoto T. Biopsy of the terminal ileum. *Gastrointest Endosc* 1972; 19: 7-10. [\[CrossRef\]](#)
- Savaş B, Bektaş M, Perçinel S, Tüzün A, Ensarı A, Çetinkaya H, ve ark. İnflamatuvar barsak hastalığında histopatolojik kriterlerin klinik semptomatolojiye ilişkisi. *Akademik Gastroenteroloji Dergisi* 2008; 7: 24-9.
- Ege B, Bozkaya H, Leventoğlu S, Gülen M, Menteş B. Kaliteli kolonoskopi değerlendirme kriterlerine uygun kolonoskopi uygulaması. *Kolon Rektum Hast Derg* 2013; 23: 118-23.
- Ersoy O, Arslan S. Kronik ishaller hastaya yaklaşım. *Türkiye Tıp Dergisi* 2004; 11: 194-203.
- Lepinski SM, Hamilton JW. Isolated cytomegalovirus ileitis detected by colonoscopy. *Gastroenterology* 1990; 98: 1704-1706.
- Tribl B, Turetschek K, Mostbeck G, Schneider B, Stain C, Potzi R, et al. Conflicting results of ileoscopy and small bowel double-contrast barium examination in patients with Crohn's disease. *Endoscopy* 1998; 30: 339-344. [\[CrossRef\]](#)
- Zwas FR, Bonheim NA, Berken CA, Gray S. Diagnostic yield of routine ileoscopy. *Am J Gastroenterol* 1995; 90: 1441-1443.
- Geboes K. The strategy for biopsies of the terminal ileum should be evidence based. *Am J Gastroenterol* 2007; 102: 1090-1092. [\[CrossRef\]](#)
- Gonvers JJ, Bochud M, Burnand B, Froehlich F, Dubois RW, Varder JP. 10. Appropriateness of colonoscopy: diarrhea. *Endoscopy* 1999; 31: 641-646. [\[CrossRef\]](#)
- Geboes K, Ectors N, D'Haens G, Rutgeerts P. Is ileoscopy with biopsy worthwhile in patients presenting with symptoms of inflammatory bowel disease? *Am J Gastroenterol* 1998; 93: 201-206. [\[CrossRef\]](#)
- Batres LA, Maller ES, Ruchelli E, Mahboubi S, Baldassano RN. Terminal ileum intubation in pediatric colonoscopy and diagnostic value of conventional small bowel contrast radiography in pediatric inflammatory bowel disease. *J Pediatr Gastroenterol Nutr* 2002; 35: 320-323. [\[CrossRef\]](#)
- Zwas FR, Bonheim NA, Berken CA, Gray S. Ileoscopy as an important tool for the diagnosis of Crohn's disease: a report of seven cases. *Gastrointest Endosc* 1994; 40: 89-91. [\[CrossRef\]](#)
- Church JM. Complete colonoscopy: how often? And if not, why not? *Am J Gastroenterol* 1994; 89: 556-560.
- Ansari A, Soon SY, Saunders BP, Sanderson JD. A prospective study of the technical feasibility of ileoscopy at colonoscopy. *Scand J Gastroenterol* 2003; 38: 1184-1186. [\[CrossRef\]](#)
- Rex DK, Petrini JL, Baron TH, Chak A, Cohen J, Deal SE, et al. Quality indicators for colonoscopy. *Gastrointest Endosc* 2006; 63(Suppl 4): S16-28. [\[CrossRef\]](#)
- Marshall JB, Brown DN. Photodocumentation of total colonoscopy: how successful are endoscopists? Do reviewers agree? *Gastrointest Endosc* 1996; 44: 243-248. [\[CrossRef\]](#)
- Rex DK. Still photography versus videotaping for documentation of cecal intubation: a prospective study. *Gastrointest Endosc* 2000; 51: 451-459. [\[CrossRef\]](#)
- Kundrotas LW, Clement DJ, Kubik CM, Robinson AB, Wolfe PA. A prospective evaluation of successful terminal ileum intubation during routine colonoscopy. *Gastrointest Endosc* 1994; 40: 544-546. [\[CrossRef\]](#)
- Cherian S, Singh P. Is routine ileoscopy useful? An observational study of procedure times, diagnostic yield, and learning curve. *Am J Gastroenterol* 2004; 99: 2324-2329. [\[CrossRef\]](#)
- Iacopini G, Frontespezi S, Vitale MA, Villotti G, Bella A, d'Alba L, et al. Routine ileoscopy at colonoscopy: a prospective evaluation of learning curve and skill-keeping line. *Gastrointest Endosc* 2006; 63: 250-256. [\[CrossRef\]](#)
- Peden AH, Head MW, Ritchie DL, Bell JE, Ironside JW. Preclinical vCJD after blood transfusion in a PRNP codon 129 heterozygous patient. *Lancet* 2004; 364: 527-529. [\[CrossRef\]](#)
- Wroe SJ, Pal S, Siddique D, Hyare H, Macfarlane R, Joiner S, et al. Clinical presentation and pre-mortem diagnosis of variant Creutzfeldt-Jakob disease associated with blood transfusion: a case report. *Lancet* 2006; 368: 2061-2067. [\[CrossRef\]](#)
- Llewelyn CA, Hewitt PE, Knight RS, Amar K, Cousens S, Mackenzie J, et al. Possible transmission of variant Creutzfeldt-Jakob disease by blood transfusion. *Lancet* 2004; 363: 417-421. [\[CrossRef\]](#)
- Borsch G, Schmidt G. Endoscopy of the terminal ileum. Diagnostic yield in 400 consecutive examinations. *Dis Colon Rectum* 1985; 28: 499-501. [\[CrossRef\]](#)
- McMillan S, Sharma P, Grabham J. Terminal ileal biopsy is unnecessary to confirm complete colonoscopy. *Gut* 2006; 55(Suppl 11): A259.
- Ersoy O, Bayraktar Y. Gastroenterolojide yeni görüntüleme yöntemi: kapsül endoskopi. *Hacettepe Tıp Dergisi* 2004; 35: 212-215.
- Semrad CE. Small bowel enteroscopy: territory conquered, future horizons. *Curr Opin Gastroenterol* 2009; 25: 110-5. [\[CrossRef\]](#)
- Carter MJ, Lobo AJ, Travis SP. Guidelines for the management of inflammatory bowel disease in adults. *Gut* 2004; 53(Suppl 5): V1-16. [\[CrossRef\]](#)

29. Yoong KK, Heymann T. It is not worthwhile to perform ileoscopy on all patients. *Surg Endosc* 2006; 20: 809-811. [\[CrossRef\]](#)
30. Haseman JH, Lemmel GT, Rahmani EY, Rex DK. Failure of colonoscopy to detect colorectal cancer: evaluation of 47 cases in 20 hospitals. *Gastrointest Endosc* 1997; 45: 451-455. [\[CrossRef\]](#)
31. Jeong SH, Lee KJ, Kim YB, Kwon HC, Sin SJ, Chung JY. Diagnostic value of terminal ileum intubation during colonoscopy. *J Gastroenterol Hepatol* 2008; 23: 51-55. [\[CrossRef\]](#)
32. Grobmyer SR, Gollub MJ, Shia J, Guillem JG. Ileal diverticulitis: clinical and radiographic presentation. *Dig Dis Sci* 2004; 49: 498-502. [\[CrossRef\]](#)
33. Korman LY, Overholt BF, Box T, Winker CK. Perforation during colonoscopy in endoscopic ambulatory surgical centers. *Gastrointest Endosc* 2003; 58: 554-557. [\[CrossRef\]](#)
34. Woltjen JA. A retrospective analysis of cecal barotrauma caused by colonoscope air flow and pressure. *Gastrointest Endosc* 2005; 61: 37-45. [\[CrossRef\]](#)
35. Malki SA, Bassett ML, Pavli P. Small bowel obstruction caused by colonoscopy. *Gastrointest Endosc* 2001; 53: 120-121. [\[CrossRef\]](#)
36. Bhasin DK, Goenka MK, Dhavan S, Dass K, Singh K. Diagnostic value of ileoscopy: a report from India. *J Clin Gastroenterol* 2000; 31: 144-146. [\[CrossRef\]](#)