

Non-recurrent nerve from the vagus antero-medially located in the carotid sheath

Emin Gürleyik

ABSTRACT

Non-recurrent inferior laryngeal nerve (ILN) arising from the vagus nerve is a rare anatomic variation. The vagus descends vertically in the cervical neurovascular bundle, between and posterior to common carotid artery (CCA) and internal jugular vein (IJV). The vagus has also some anatomic variations. We present a case of two coincident anatomic variations both ILN and the vagus nerve. A patient with multinodular goiter was surgically treated with total thyroidectomy. Both two ILNs were identified, fully exposed and preserved along their cervical courses. We found that the right non-recurrent ILN directly arises from cervical vagal trunk, and enters the larynx at usual point after a short transverse course parallel to the inferior thyroid artery. The vagus nerve, easily exposed after dissection of the right lobe of the thyroid gland, is located medially to the CCA. We discovered the association of non-recurrent ILN and medially located vagus nerve in the same patient. Non-recurrent nerve and medially located vagus nerve in the cervical neurovascular bundle are two different variations. The coincidence of right non-recurrent ILN arising from cervical part of the vagus medial to the CCA in the same patient is a very interesting feature. The safety of thyroid operations is dependent on proper identification, dissection and full exposition of ILN. The safe procedure requires complete knowledge on the anatomy of neural structures including all their anatomic variations.

Keywords: Thyroid, vagus, recurrent nerve, variation, thyroidectomy

INTRODUCTION

The security of thyroid surgery may be affected by anatomical variations of the recurrent laryngeal nerve (RLN). A thyroid surgeon must know anatomy of the inferior laryngeal nerve (ILN) including its anatomic variations. A rare variation like non-recurrent nerve increases complication rate of thyroid operations (1-8). RLN is a branch of the vagus nerve which is normally located in the cervical neurovascular bundle posterior to the carotid artery and the jugular vein. The vagus nerve has also some anatomic variations which affect normal location of the nerve. The association of right non-recurrent nerve and varied location of cervical part of the vagus nerve is an extremely rare occurrence.

In this case report, a right non-recurrent ILN arising from cervical part of the vagus nerve with unusual location in the neurovascular bundle is presented in a surgically treated goiter case.

CASE PRESENTATION

Informed consent was obtained from a patient with goiter who has an indication of thyroid surgery. Serum TSH and FT4 levels, and ultrasound images established the diagnosis of euthyroid multinodular thyroid enlargement with multiple hypoechoic solid nodules (largest one is 16 mm in diameter) in the right lobe and also multiple hypoechoic solid nodules (largest one is 36 x 25 mm) in the left lobe. Follicular neoplasm was the pathological diagnosis after fine needle aspiration cytology from the dominant nodule of the right lobe.

Total resection of the thyroid was surgical treatment in this patient. We identified inferior thyroid artery and left ILN with usual lateral approach. The right RLN was not found at usual position. The dissection was advanced in upward direction that a non-recurrent ILN was identified and exposed near the Berry ligament. The non-recurrent nerve shows a parallel course with the inferior thyroid artery. The nerve is followed until its origin. It has arisen from the trunk of cervical vagus nerve which was located anterior-medial position to common carotid artery (CCA) (Figure 1). The length of the non-recurrent ILN from the vagus to laryngeal entry was approximately 4 cm. Total thyroidectomy was performed after complete anatomical identification of both (left recurrent and right non-recurrent) ILNs. The postoperative period was uneventful. The patient was discharged at second postoperative day without any complication.

Department of General Surgery,
Düzce University Faculty of
Medicine, Düzce, Turkey

Address for Correspondence

Emin Gürleyik

Düzce Üniversitesi Tıp Fakültesi,
Genel Cerrahi Anabilim Dalı,
Düzce, Türkiye
Phone: +90 380 542 13 90
e-mail:
egurleyik@yahoo.com

Received: 18.08.2014

Accepted: 25.09.2014

Available Online Date: 19.06.2015

©Copyright 2015
by Turkish Surgical Association
Available online at
www.ulusalcerrahidergisi.org

DISCUSSION

The safe thyroid surgery depends on the surgical identification and exposure of the RLN. This nerve has anatomic variations. Non-recurrent nerve is a rare variation with prevalence of equal or below 1% (1, 3-8). The non-recurrent nerve originates from the vagus, and has transverse course toward laryngeal entry point. The vagus nerve is generally located in the cervical neurovascular bundle, between and posterior to CCA and internal jugular vein (IJV). Some variations of cervical course of the vagus nerve have also been described. Our patient is a rare example of the association of both ILN and vagus nerve variations; non-recurrent course of right ILN and anterior-medial course of the vagus nerve in the carotid sheath.

Main anatomical features of our patient are right non-recurrent ILN and medially located vagus nerve. We think that two variations in a patient is extremely unusual. The association of location (medially to CCA) variation of the right vagus trunk and anatomic variation (non-recurrent course) of ILN is once reported in the literature (9). Toniato et al. (9) have reported medially located vagus nerve to the carotid artery associated with non-recurrent laryngeal nerve. They have mentioned that the medially located vagus nerve to the carotid artery could be a "pilot light" for non-recurrent nerve. They have commented that this is the first reported case in the literature (9). The coincidence of two variations of these two nerves in the same case deserves a distinct attention.

The variation as non-recurrent nerve increases the risk of nerve palsy. If RLN is not identified at its normal anatomy during surgery, surgeon must consider a non-recurrent nerve. Safe complete exposure of the nerve avoids vocal cord palsy. During thyroid surgery, the nerve is more superficial and vulnerable near Berry ligament. Therefore, the non-recurrent nerve should be followed from its origin from the vagus until its laryngeal entry. When we cannot find right RLN with usual lateral approach after identification of inferior thyroid artery, we discovered non-recurrent nerve by careful dissection near Berry ligament. We followed non-recurrent nerve until its origin from vagal trunk. This dissection permits us to also observe varied location of the vagus medial and anterior to CCA.

In normal anatomy, the cervical part of the vagus nerve passes vertically down the neck within the carotid sheath, lying between and just posterior to CCA and IJV. The vagus nerve shows a high propensity to change its topographical relationship with the CCA during early fetal life; from primitive ventral course to final dorsal course (10). This anatomic observation points out that some topographical variations of the vagus nerve may occur in adults. At thyroidectomy operation the vagus is not usually visible and not detected during thyroïd lobe dissection. According to anatomic variation of the cervical course of the vagus nerve as in our patient, the nerve (medially located to the artery in the carotid sheath) may easily be detected and seen in the operation field after medial retraction of the thyroid lobe.

Intraoperative neuromonitoring (IONM) was not used in this operation. IONM can be helpful to find recurrent nerve, especially nerve with anatomical variation. IONM is a useful tool to better understand the anatomy and physiology of the

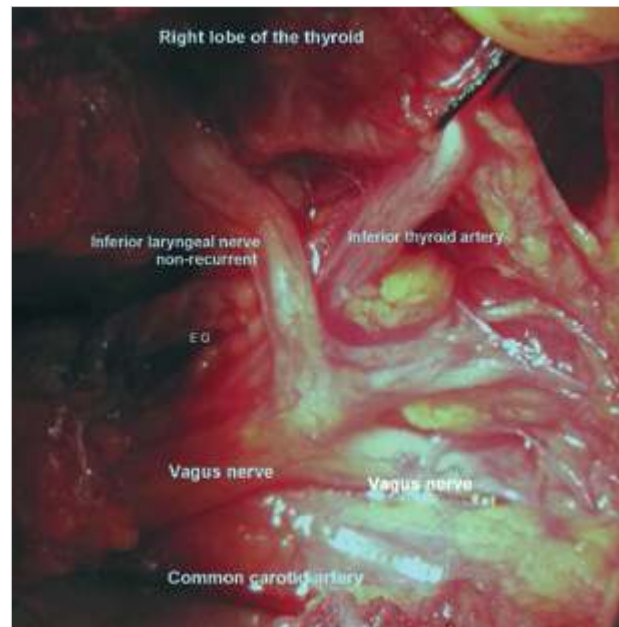


Figure 1. The right non-recurrent inferior laryngeal nerve arises directly from cervical vagus trunk. The vagus trunk is medially and superficially located to the common carotid artery

ILN (11). The standardized technique of IONM involves vagal nerve stimulation which is useful for detecting non-recurrent ILN (12). Intraoperative monitoring involving vagal stimulation provides reliable electrophysiologic intraoperative verification of the presence of the non-recurrent ILN (13). Negative signal after pre-dissection vagus stimulation may show non-recurrent nerve. Therefore, IONM may prevent or reduce complication rate of nerve palsy in case of the presence of anatomical variations.

CONCLUSION

Non-recurrent nerve and medially located vagus nerve in the cervical neurovascular bundle are two different variations. The coincidence of right non-recurrent nerve arising from cervical part of the vagus medial to the CCA is a very interesting feature. The association of two anatomic variations of both nerves has occurred in the same patient. The safety of thyroid operations may be provided by identification, dissection and full exposition of ILN. This dissection requires complete knowledge on the anatomy of the ILN including all neural anatomic and topographical variations.

Informed Consent: Written informed consent was obtained from patient who participated in this case.

Peer-review: Externally peer-reviewed.

Conflict of Interest: No conflict of interest was declared by the author.

Financial Disclosure: The author declared that this study has received no financial support.

REFERENCES

1. Mahmodlou R, Aghasi MR, Sefhervand N. Identifying the non-recurrent laryngeal nerve: preventing a major risk of morbidity during thyroidectomy. *Int J Prev Med* 2013; 4: 237-240.
2. Wang CC, Wu CH. Non-recurrent inferior laryngeal nerve identification during robotic thyroidectomy. *J Laryngol Otol* 2014; 128: 199-202. [\[CrossRef\]](#)

3. Gurleyik E, Dogan S, Gunal O, Pehlivan M. The rare coincidence: non-recurrent laryngeal nerve pointed by a Zuckerkandl's tubercle. *Case Rep Med* 2012; 2012: 143049. [\[CrossRef\]](#)
4. Docimo G, Avenia N, Ragusa M, Gili S, Parmegiani D, Casalino G, et al. Non recurrent inferior laryngeal nerve: our surgical experience. *Clin Ter* 2009; 160: 347-349.
5. Calzolari F, Misso C, Monacelli M, Lucchini R, Sanguinetti A, D'ajello M, et al. Non-recurrent inferior laryngeal nerves and sympathetic-inferior laryngeal anastomotic branches: 6 years' personal experience. *Chir Ital* 2008; 60: 221-225.
6. Page C, Monet P, Peltier J, Bonnaire B, Strunski V. Non-recurrent laryngeal nerve related to thyroid surgery: report of three cases. *J Laryngol Otol* 2008; 122: 757-761. [\[CrossRef\]](#)
7. Gurleyik E. Three variations of the laryngeal nerve in the same patient: a case report. *J Med Case Rep* 2011; 5: 266. [\[CrossRef\]](#)
8. Li X, Wang Z, Lu X, Li J, Huang Y, Huang J, et al. Non-recurrent laryngeal nerve related to thyroid surgery: a report of 5 cases and literature review. *Med Sci Monit* 2010; 16: 71-75.
9. Toniato A, Merante Boschini I, Pagetta C, Casalide E, Pelizzo M. A "pilot light" of the right non-recurrent laryngeal nerve. *Acta Otorhinolaryngol Ital* 2010; 30: 107-109.
10. Miyake N, Hayashi S, Kawase T, Baik Hwan C, Murakami G, Fujiyama M, et al. Fetal anatomy of the human carotid sheath and structures in and around it. *Anat Rec* 2010; 293: 438-445. [\[CrossRef\]](#)
11. Donatini G, Carnaille B, Dionigi G. Increased detection of non-recurrent inferior laryngeal nerve during thyroid surgery using systematic intraoperative neuromonitoring. *World J Surg* 2013; 37: 91-93. [\[CrossRef\]](#)
12. Dionigi G, Kim HY, Wu CW, Lavazza M, Ferrari C, Leotta A, et al. Vagus nerve stimulation for standardized monitoring: technical notes for conventional and endoscopic thyroidectomy. *Surg Technol Int* 2013; 23: 95-103.
13. Kamani D, Potenza AS, Cernea CR, Kamani YV, Randolph GW. The nonrecurrent laryngeal nerve: Anatomic and electrophysiologic algorithm for reliable identification. *Laryngoscope* 2015; 125: 503-508. [\[CrossRef\]](#)