

Endometriosis within the sigmoid colon/extragenital endometriosis

Turan Acar¹, Nihan Acar¹, Salih Can Çelik¹, Neşe Ekinci², Ercüment Tarcan¹, Emir Çapkınoğlu¹

ABSTRACT

Endometriosis is the presence of endometrial glands and stroma outside the uterine cavity. Although it is common in women in the reproductive age, intestinal endometriosis is extremely rare and may lead to serious clinical problems. In this article, we present two rare cases of endometriosis localized in the sigmoid colon lumen. The first case is a 45 year-old female complaining of rectal bleeding for 6 months. A polypoid lesion with suspicion of malignancy, 3-4 cm in size was identified at colonoscopy. Laparoscopic anterior resection was performed since it was not suitable for colonoscopic polypectomy. The pathology examination revealed extragenital endometriosis. The second case is a 36 year-old female admitted for lower abdominal pain and rectal bleeding for the last 3 months. She was diagnosed with sigmoid diverticulitis. The patient's symptoms regressed with medical treatment, but due to early and multiple recurrent episodes it was decided to perform an elective laparoscopic anterior resection. The pathology report stated diverticulosis coli and intraluminal endometriosis. Intestinal endometriosis should be considered as part of the differential diagnosis in female patients of the reproductive age who present with constipation, gastrointestinal bleeding, nausea, vomiting, cramp-like abdominal pain, diarrhea and pelvic pain. In these patients, resection and anastomosis of the effected bowel segment is accepted as the choice of treatment.

Keywords: Extragenital endometriosis, laparoscopy, anterior resection, sigmoid colon

INTRODUCTION

Endometriosis is defined as the presence of endometrial glands and stroma outside the uterine cavity (1). It was first defined by Recklinghausen in 1896, and was described in more detail later in 1921 by Sampson. The incidence is reported to be 15% in childbearing age, while it can be found in approximately 50% of infertile women (2). It is more frequent in pelvic organs, and its location outside the pelvis is referred to as extragenital or extrapelvic disease. Extragenital endometriosis can affect all organs, mainly the bowel and the urinary tract (3). Barnes defined lung endometriosis in 1953, while in 1921 Judd described endometriosis in the bladder. The first laparoscopic approach to intestinal endometriosis has been reported in 1980 (4). In this article, we reported 2 patients with endometriosis of the sigmoid colon lumen who underwent laparoscopic anterior resection.

CASE PRESENTATION

Our first case was a 45-year-old female who presented to our hospital with rectal bleeding for approximately 6 months. Her past medical and surgical history was uneventful. G3P3Y3, all normal spontaneous vaginal birth, and she was on menopause for three years. Her physical examination was normal and there was no palpable mass on rectal examination. The colonoscopy showed a 3-4 cm in diameter, polypoid lesion in the sigmoid colon that suggested malignancy. The biopsy result was reported as hyperplastic polyp. Laparoscopic anterior resection was performed due to the patient's ongoing bleeding since the polyp was not suitable for colonoscopic polyp excision. The pathology result was reported as extragenital endometriosis (Figure 1, b). There were no complications in the postoperative period, and she was discharged on the seventh day. The patient is being followed up for seven months with no further complaints.

Our second case was a 36-year-old female patient who presented to the emergency room with rectal bleeding and abdominal pain for about 3 months. Her past medical and surgical history was uneventful. G1P1Y1, who gave birth by cesarean section in 2004, and was having regular menstrual cycles. Evaluations revealed diverticulitis of the sigmoid colon. Her symptoms regressed with medical treatment, but recurred in the early period following treatment. The abdominal computed tomography obtained when the symptoms recurred showed signs of localized peritonitis. The patient was started on intravenous antibiotics, but her complaints did not regress. The patient was scheduled for elective surgery due to early recurrence of complaints that did not regress, also taking her age into account. On exploration, the sigmoid colon was adhered to the anterior abdominal wall with a closed perforation in that area. The patient underwent laparoscopic anterior resection. The pathology report stated diverticulosis coli

¹Clinic of General Surgery, İzmir Katip Çelebi University Atatürk Training and Research Hospital, İzmir, Turkey

²Clinic of Pathology, İzmir Katip Çelebi University Atatürk Training and Research Hospital, İzmir, Turkey

Address for Correspondence

Turan Acar
e-mail:
drturanacar1982@gmail.com

Received: 15.05.2014
Accepted: 05.09.2014
Available Online Date:
10.07.2015

©Copyright 2015
by Turkish Surgical Association
Available online at
www.uluscerrahidergisi.org

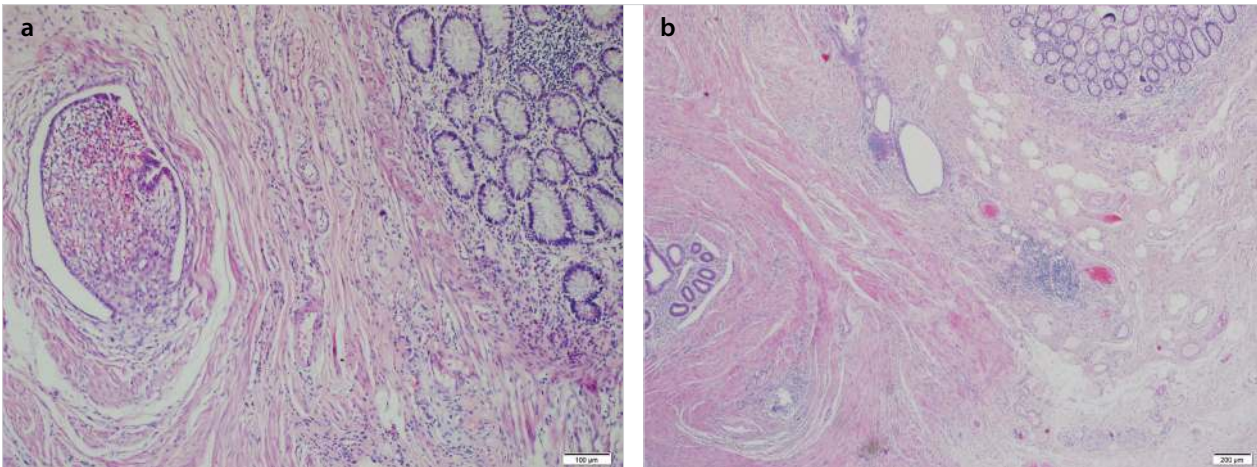


Figure 1. a, b. Endometrial glands and endometrial stroma within muscularis propria, colonic wall. x100 and x40, HE

and intraluminal endometriosis. There were no postoperative complications, and she was discharged on the eighth postoperative day. She is being followed up for seven months with no further complaints.

Informed consent was obtained from both patients. Consents were also obtained to perform scientific studies.

DISCUSSION

Endometriosis is defined as the histologic presence of endometrial glands and stroma outside the uterine cavity (1). The most accepted theory is retrograde spread as proposed by Sampson, which refers to propagation of endometrial cells in the peritoneal cavity through the fallopian tubes during menstruation followed by dissemination to other areas. Endometriosis is detected more frequently in the genital organs and pelvic peritoneum, and rarely in the gastrointestinal system, lung, bladder, greater omentum, surgical scars, mesentery, kidneys, the skin and nasal cavity (5). The most common site affected within the gastrointestinal tract is the rectosigmoid junction, followed by the ileum and the appendix (6). Intestinal endometriosis is usually asymptomatic. However; gastrointestinal bleeding, nausea, vomiting, crampy abdominal pain, diarrhea, constipation, and intussusception may also occur. Symptoms are not helpful in the diagnosis alone. The common complaint in our cases was rectal bleeding. It can lead to narrowing of the lumen and subsequent obstruction by creating intestinal inflammation and fibrosis in time. Therefore, intestinal obstruction and perforation may occur. Majority of patients with intestinal endometriosis is diagnosed with laparoscopy or laparotomy. In our cases, the diagnosis could not be made with pre-operative diagnostic tests. Diagnoses of the patients were based on pathological examination of the sigmoid colon that was removed laparoscopically.

Endometriosis usually involves the serosa or subserosal layer, although it sometimes can involve all layers of the colon. Ultrasound, computed tomography, magnetic resonance imaging and colonoscopy could help establish the diagnosis according to the localization of the pathology. The findings may vary depending on the day of the menstrual cycle, the ratio of stromal and glandular elements, and the amount of bleeding and inflammatory response in the surrounding tissue. They may appear as cystic, solid, or both solid and cystic lesions. In patients

with intestinal endometriosis, the diagnosis is often difficult and delayed since the presentation may be confused with several diseases including malignancies. Although fine-needle biopsy is helpful in diagnosis, generally histopathologic evaluation of surgically excised material is required for definitive diagnosis (7). Medical treatment consisting of non-steroidal anti-inflammatory drugs, oral contraceptives, and GnRH analogues can be used before surgical treatment. Although symptomatic improvement is detected in most patients, the recurrence rate is very high after cessation of treatment. Therefore, surgery should be the first choice treatment in especially young patients and those with severe symptoms. The recurrence rate after total excision is very low (8). Laparoscopic approach to extragenital endometriosis of the bowel was first reported in 1980. Advanced laparoscopic procedures have replaced laparotomy for colectomy, and became the gold standard for surgical treatment (9, 10). The morbidity rate of laparoscopic surgery is much less as compared to that of laparotomy. Similarly, we performed laparoscopic colon resection in our patients and observed that their postoperative pain scores as well as pulmonary problems and wound infection rates were lower, and their returning to daily activities was shorter as compared to patients with laparotomy.

CONCLUSION

Intestinal endometriosis should be kept in mind as part of differential diagnosis in female patients of reproductive age who present with constipation, gastrointestinal bleeding, nausea, vomiting, crampy abdominal pain, diarrhea and pelvic pain. In such patients, resection and anastomosis of the affected bowel segment is accepted as the best treatment option, if possible by laparoscopy.

Informed Consent: Written informed consent was obtained from patients who participated in this case.

Peer-review: Externally peer-reviewed.

Author Contributions: Concept - T.A., N.A., S.C.Ç., E.Ç., E.T., N.E.; Design - T.A., N.A., S.C.Ç., E.Ç., E.T., N.E.; Supervision - T.A., N.A., S.C.Ç., E.Ç., E.T., N.E.; Funding - N.A., T.A.; Materials - S.C.Ç., N.E.; Data Collection and/or Processing - T.A., S.C.Ç.; Analysis and/or Interpretation - T.A., E.T.; Literature Review - T.A., N.A.; Writer - T.A., N.A.; Critical Review - E.T., N.E.

Conflict of Interest: No conflict of interest was declared by the authors.

Financial Disclosure: The authors declared that this study has received no financial support.

REFERENCES

1. Nezhat F, Shamsirsaz A, Yildirim G. Pelvic pain, endometriosis, and the role of the gynecologist. In: Altcheck A and Deligdisch L eds. *Pediatric, Adolescent and Young Adult Gynecology*. 1st ed. New Jersey: Wiley- Blackwell, 2009: 174-194. [\[CrossRef\]](#)
2. Erdem M, Erdem A, Göl K, Yıldırım M. Cesarean scar endometriosis: Case report. *Türkiye Klinikleri J Gynecol Obst* 1992; 2: 15-16.
3. Ali T, Mohammed F, Hoford R, Maharaj D, Sookhoo S. Extrapelvic endometriosis presenting as unusual swellings of the buttock and thigh. *West Indian Med J* 2001; 50: 328- 330.
4. Nezhat C, Hajhosseini B, King LP. Robotic-assisted laparoscopic treatment of bowel, bladder, and ureteral endometriosis. *JSL* 2011; 15: 387-392. [\[CrossRef\]](#)
5. Bergvist A. Extragenital endometriosis: a review. *Eur J Surg* 1992; 158: 7-12.
6. Remorgida V, Ferrero S, Fulcheri E, Ragni N, Martin DC. Bowel endometriosis: Presentation, diagnosis and treatment. *Obst Gynecol Surv* 2007; 62: 461-470. [\[CrossRef\]](#)
7. Erkan N, Hacıyanlı M, Sayhan H. Abdominal wall endometriomas. *Int J Gynecol Obstet* 2005; 89: 59-60. [\[CrossRef\]](#)
8. Kır Şahin F, Şahin DA, Köken G, Koşar MN, Şahin Ö. A case of endometriosis cesarian scar, and review of the literature. *İstanbul Tıp Fakültesi Dergisi* 2006; 68: 117-119.
9. Clinical Outcomes of Surgical Therapy Study Group. A comparison of laparoscopically assisted and open colectomy for colon cancer. *N Engl J Med* 2004; 350: 2050-2059. [\[CrossRef\]](#)
10. Pitkin RM, Parker WH. Operative laparoscopy: a second look after 18 years. *Obstet Gynecol* 2010; 115: 890-891. [\[CrossRef\]](#)