








Primary paraspinal lumbar hydatid disease: A known diagnosis in an unusual localization

Fatma Ceren Sarioğlu¹ , Yeliz Pekçevik¹ , Hilal Şahin¹ , Eyüp Kebapçı² , Emel Ebru Pala³ 

ABSTRACT

Hydatid disease is a parasitic infection caused by *Echinococcus granulosus*. Although the liver and lung are the most common sites of hydatid disease, it can also be seen in other organs due to migration via systemic circulation. Paraspinal lumbar hydatid disease without the involvement of other organs is extremely rare. We aimed to present the imaging and histopathological findings of a case with painful lumbar swelling that was later diagnosed as primary lumbar paraspinal hydatid disease. Hydatid disease should be considered as the differential diagnosis in patients with a lumbar paraspinal mass, particularly that containing multiple well-defined, round, small cysts, and in patients living in or traveling to endemic regions.

Keywords: Hydatid disease, intramuscular, paraspinal muscles, magnetic resonance imaging

ORCID IDs of the authors:

F.C.S. 0000-0002-6714-2367;
Y.P. 0000-0003-1421-3376;
H.Ş. 0000-0001-8726-8998;
E.K. 0000-0003-1967-2789;
E.E.P. 0000-0001-7262-1867.

Cite this paper as:

Sarioğlu FC, Pekçevik Y, Şahin H, Kebapçı E, Pala E. Primary paraspinal lumbar hydatid disease: a known diagnosis in an unusual localization. Turk J Surg 2018; 34(4): 346-348.

¹Department of Radiology, İzmir Tepecik Training and Research Hospital, İzmir, Turkey

²Department of General Surgery, İzmir Tepecik Training and Research Hospital, İzmir, Turkey

³Department of Pathology, İzmir Tepecik Training and Research Hospital, İzmir, Turkey

This study was presented at the TMRD (Turkish Society of Magnetic Resonance) 20th Congress, 21-23 May 2015, Ankara, Turkey.

Corresponding Author Yeliz Pekçevik

e-mail: yelizpekcevik@yahoo.com

Received: 25.03.2015

Accepted: 07.06.2015

©Copyright 2018
by Turkish Surgical Association

Available online at
turkjsurg.com

INTRODUCTION

Hydatid disease (HD) is a parasitic infection caused by *Echinococcus granulosus*. Although the liver (50%-70%) and lung (20%-30%) are the most common sites of HD, it can also be seen in other organs (e.g., the brain, heart, orbital, kidney, urinary bladder, and thyroid gland) due to migration via systemic circulation (1). Paraspinal HD without the involvement of other organs is extremely rare (0.5%-3%) because muscles produce lactic acid, which results in an unsuitable environment for hydatid cysts that need oxygen for growing (1, 2). The psoas muscle and lumbar paraspinal muscles are the most common locations of paraspinal HD (3-5).

We aimed to present imaging and histopathological findings of a case with painful lumbar swelling that was later diagnosed as primary lumbar paraspinal HD.

CASE PRESENTATION

A 51-year-old woman presented with swelling in the left lumbar region. The patient complained of slowly growing swelling in the lumbar region and noticed pain and tenderness since the last 1 week. Patient's medical history and physical examination and laboratory test findings were unremarkable. Ultrasonography of the patient demonstrated a mass with cystic and solid portions. Magnetic resonance (MR) imaging of the lesion (1.5 T, Achieva; Philips Medical Systems, Best, the Netherlands) showed a well-defined mass that was located in the lumbar paraspinal muscles. The mass was hypointense on T1-weighted images (Figure 1a), was hyperintense on T2-weighted images (Figure 1b), and showed only peripheral enhancement after the injection of gadolinium contrast media (Figure 1c). There was no spinal or intraspinal extension. Although the lumbar paraspinal muscle is not a common location of HD, because of imaging findings, particularly multiple well-circumscribed small cysts resembling daughter cysts, the differential diagnosis was suggested to be HD. A serological test was performed and was found to be negative for HD. The negative serology did not exclude the diagnosis, and therefore, surgical excision was considered. After complete resection of the soft tissue mass, macroscopic evaluation of the intramuscular mass with round vesicles was indicative of HD (Figure 2). Microscopic examination showed the cuticular membranes of the hydatid cysts and the outer fibrous capsule (Figure 3).

DISCUSSION

We present a case with primary lumbar paraspinal HD that had some diagnostic findings. Although the liver and lung (20%-30%) are the most common sites of HD, it can also be seen in other organs due to migration via systemic circulation (1). Paraspinal HD without the involvement of other organs is extremely rare (0.5%-3%), and the psoas muscle and lumbar paraspinal muscles are the most common locations of paraspinal HD (2, 4, 6).

Ultrasonography can be the first modality to be chosen in the diagnosis of HD. The sensitivity of ultrasonography is 95%, and if vesicular membranes are present, the sensitivity can be up to 100%. However, in the paraspinal region, it cannot evaluate the extent of the disease and relationship between

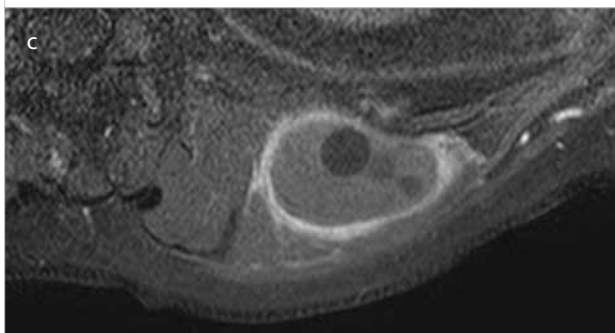
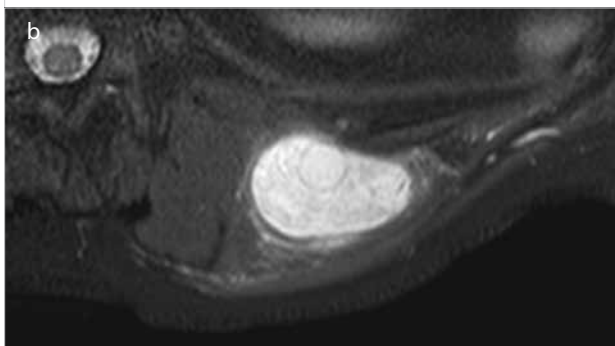
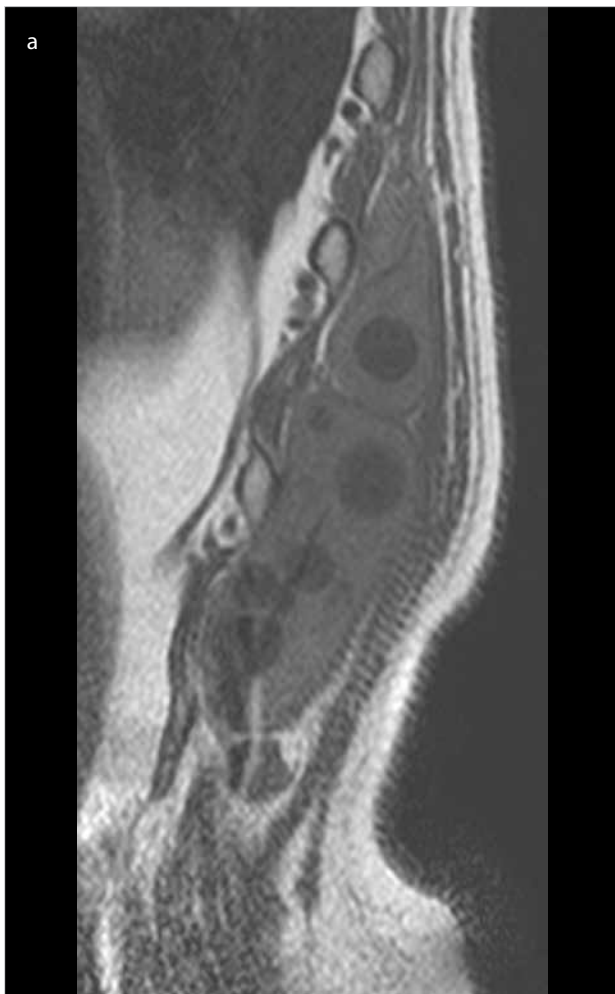


Figure 1. a-c. (a) Sagittal T1-weighted and (b) axial T2-weighted fat-suppressed images show a well-defined paraspinous mass in the left lumbar region with small, well-circumscribed, round cysts. (c) On axial post-contrast fat-suppressed T1-weighted image, the lesion shows peripheral enhancement

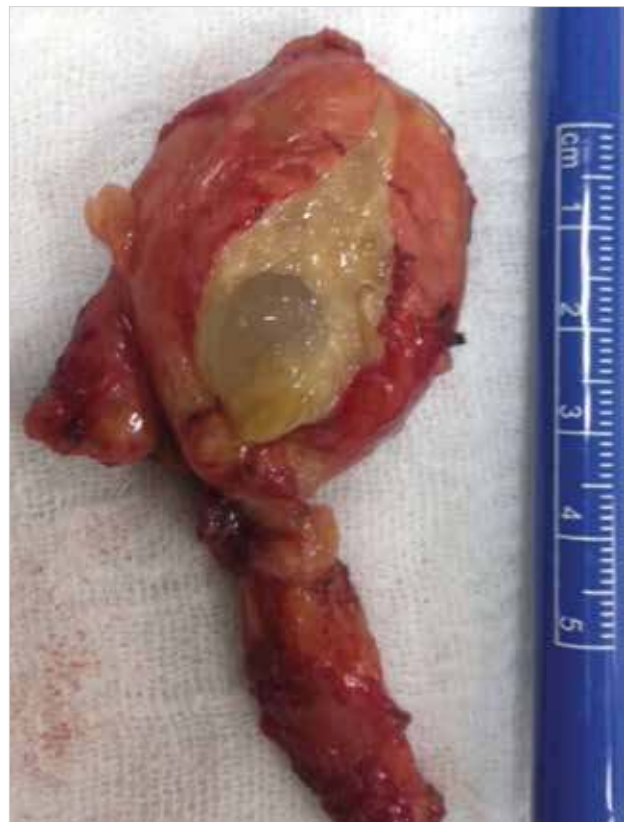

Figure 2. Macroscopic evaluation demonstrates intramuscular mass with round vesicles

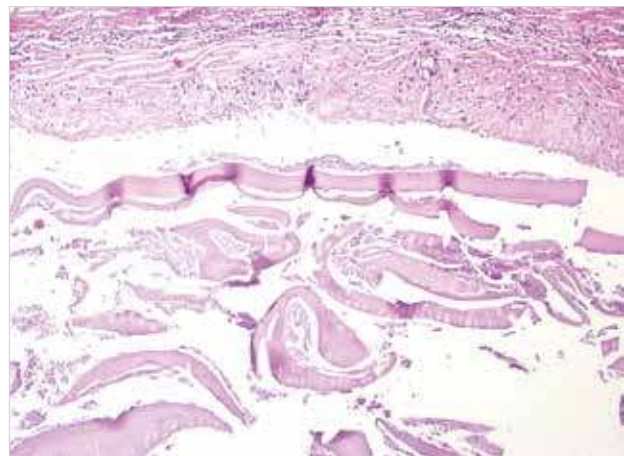


Figure 3. Photomicrograph of microscopic examination of the lesion after surgical resection (H&E x100) shows cuticular membranes of the hydatid cysts and outer fibrous capsule

the mass and the spine. Computed tomography may be performed in suspicious cases to demonstrate the presence of HD or the relationship with adjacent organs before surgery. Its sensitivity has been reported to be 85% (3, 4).

Magnetic resonance imaging can reveal most imaging findings of HD, with the exception of calcifications. Paraspinal HD is usually hypointense on T1-weighted images and hyperintense on T2-weighted images. It shows peripheral enhancement of the pseudocapsule after the intravenous injection of gadolinium contrast media (4). The most striking

finding that helps to differentiate HD from other soft tissue tumors in the paraspinal region is the presence of multiple well-defined, round cysts in the lesion (1-4). This finding was also suggestive of the presence of HD in our patient. The diagnosis can be supported by serological tests. Specific immunoglobulin G (IgG), complement fixation, and indirect fluorescent tests as well as enzyme-linked immunosorbent assay (ELISA) can be used. These tests are more sensitive in the detection of liver cysts than in the detection of cysts located in other organs (5). It is important to know that although positive serological test results are suggestive of the presence of HD, negative test results do not exclude the diagnosis (5, 6). Paraspinal HD may be treated surgically and with anti-infective drug treatment (5).

CONCLUSION

Our findings demonstrate that HD should be considered in the differential diagnosis of lumbar paraspinal masses. HD should be considered in patients with a lumbar paraspinal mass, particularly that containing multiple well-defined, round, small cysts, and in patients living in or traveling to endemic regions.

Informed Consent: Written informed consent was obtained from patient who participated in this study.

Peer-review: Externally peer-reviewed.

Author Contributions: Concept - F.C.S., Y.P., H.Ş., E.K., E.E.P.; Design - F.C.S., Y.P., H.Ş., E.K., E.E.P.; Supervision - F.C.S., Y.P., H.Ş.; Resource - F.C.S., Y.P., H.Ş., E.K., E.E.P.; Materials - F.C.S., Y.P., H.Ş., E.K., E.E.P.; Data Collection and/or Processing - F.C.S., Y.P., H.Ş.; Analysis and/or Interpretation - F.C.S., Y.P., H.Ş.; Literature Search - F.C.S., Y.P., H.Ş.; Writing Manuscript - F.C.S., Y.P.; Critical Reviews - F.C.S., Y.P., H.Ş., E.K., E.E.P.

Conflict of Interest: The authors have no conflicts of interest to declare.

Financial Disclosure: The authors declared that this study has received no financial support.

REFERENCES

1. Arkun R, Mete BD. Musculoskeletal hydatid disease. *Semin Musculoskelet Radiol* 2011; 15: 527-540. [\[CrossRef\]](#)
2. Brunetti E, Kern P, Vuitton DA. Expert consensus for the diagnosis and treatment of cystic and alveolar echinococcosis in humans. *Acta Trop* 2010; 114: 1-16. [\[CrossRef\]](#)
3. Merkle EM, Schulte M, Vogel J, Tomczak R, Rieber A, Kern P, et al. Musculoskeletal involvement in cystic echinococcosis: report of eight cases and review of the literature. *AJR Am J Roentgenol* 1997; 168: 1531-1534. [\[CrossRef\]](#)
4. Pedrosa I, Saiz A, Arrazola J, Ferreiros J, Pedrosa CS. Hydatid disease: radiologic and pathologic features and complications. *Radiographics* 2000; 20: 795-817. [\[CrossRef\]](#)
5. Sakamoto FA, Winalski CS, Golden KL, Ready JE. Painful left thigh mass. *Skeletal Radiol* 2014; 43: 61-62. [\[CrossRef\]](#)
6. Tatari H, Baran O, Sanlıdağ T, Göre O, Ak D, Manisali M, Havitçioğlu H. Primary intramuscular hydatidosis of supraspinatus muscle. *Arch Orthop Trauma Surg* 2001; 121: 93-94. [\[CrossRef\]](#)