



Colonic mucosal pseudolipomatosis: Are we aware of it?

Feyzullah Ersöz¹, Ahmet Burak Toros², Ekrem Çakar¹, Mehmet Emin Güneş¹, Serdar Çulcu¹, Serkan Sarı¹, Aziz Arı¹, Esra Paşaoğlu³, Nevra Dursun³

ABSTRACT

Objective: Colonic mucosal pseudolipomatosis is rare, and its pathogenesis is controversial. A number of mechanisms, including mechanical injury during an endoscopic procedure or chemical injury by disinfectant, seem to contribute to its pathogenesis.

Material and Methods: This retrospective study examined the colonic biopsies of 1370 patients. These biopsies were preserved at the Department of Pathology of Istanbul Training and Research Hospital between January 2012 and June 2013.

Results: We found pseudolipomatosis in 14 of 1370 colonoscopy cases (1.02%). Of these 14 patients, 8 were male and 6 were female. The male patients were between 24 and 66 years, with a mean of 39; the female patients were between 26 and 58 years, with a mean of 42.

Conclusion: Many endoscopists are unaware of the lesion, and the diagnosis is generally possible only after pathological assessment of multiple biopsies taken from suspect lesions. Here we report and discuss colonic pseudolipomatosis incidentally found in a series of patients undergoing routine colonoscopy, and we underline the endoscopic pattern and diagnostic difficulties.

Key Words: Pseudolipomatosis, colonoscopy, disinfectant, mucosal injury

INTRODUCTION

Pseudolipomatosis is a rare lesion with distinct endoscopic and histological findings. The term "colonic pseudolipomatosis" was proposed by Snover et al. (1) in 1985 and was defined as being microscopically similar to mucosal lipomatosis but not composed of adipocytes. The lesion has a low frequency in patients undergoing colonoscopy (2).

The etiology and pathogenesis of this disorder are controversial. A number of different pathogenetic mechanisms have been hypothesized for this condition, including intramucosal penetration of air by mechanical injury during insufflation, biopsy, or other procedures (3). Other authors have suggested that chemical injury by disinfectants, particularly hydrogen peroxide, contributes to the pathogenesis of these lesions (4, 5). Here we report and discuss colonic pseudolipomatosis incidentally found in a series of patients undergoing routine colonoscopy and underline the endoscopic pattern and diagnostic difficulties.

MATERIAL AND METHODS

This retrospective study examined the colonic biopsies of 1370 patients. These biopsies were preserved at the Department of Pathology of Istanbul Education and Research Hospital (Istanbul, Turkey) between January 2012 and June 2013. The data were obtained from the hospital archives. Cross sections of 5 micron-thick tissues stained with hematoxylin and embedded in paraffin were examined. Under microscopic examination, we observed vascular lacunae in the lamina propria between crypts. These lacunae had varying dimensions and were without a layer of epithelium, indicative of adipose tissue, and this made us consider them as colonic pseudolipomatosis.

This study was approved by the local Ethical Committee of the hospital.

Statistical Analysis

The simple method of ratio was used to provide percentages in this study.

RESULTS

Regarding gender, 589 (43%) of the subjects were female and 781 (57%) were male. Ages of the patients ranged between 18 and 88 years, with a mean of 44 years.

¹Clinic of General Surgery, Istanbul Training and Research Hospital, Istanbul, Turkey

²Clinic of Gastroenterology, Istanbul Training and Research Hospital, Istanbul, Turkey

³Clinic of Pathology, Istanbul Training and Research Hospital, Istanbul, Turkey

Address for Correspondence

Ahmet Burak Toros

e-mail:

aburaktoros@yahoo.com

Received: 29.08.2014

Accepted: 29.09.2014

Available Online Date: 09.04.2015

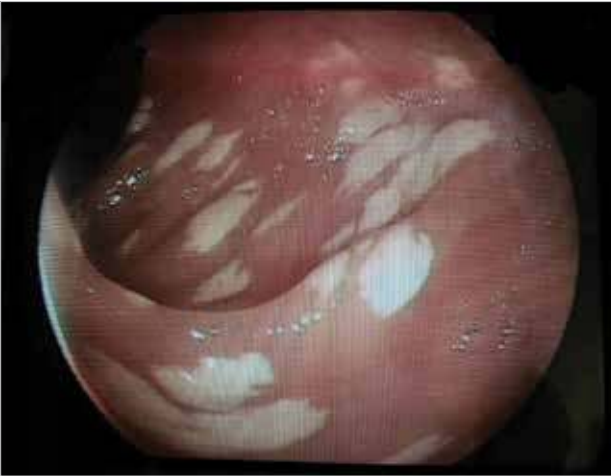

Figure 1. An endoscopic appearance of colonic pseudolipomatosis

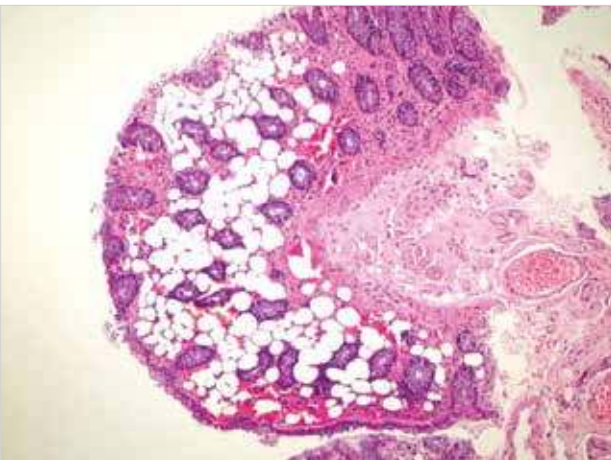


Figure 2. Vacuolar structures in the lamina propria of colonic mucosa, indicative of fatty tissue (HE x40)

Suspect lesions were slightly elevated with often multiple and sometimes confluent whitish adherent plaques in the endoscopic view (Figure 1). Multiple biopsies were taken from these lesions and pathologically assessed. We found pseudolipomatosis in 14 of 1370 colonoscopy cases (1.02%). Of these 14 patients, 8 were male and 6 were female. The male patients were between 24 and 66 years, with a mean age of 39; the female patients were aged between 26 and 58 years, with a mean of 42. Mucosal vacuolisation was characterized with empty spaces (Figure 2). Lipomas were considered in the differential diagnosis. However, in pseudolipomatosis, unlike lipocytes, the vascular structures without a nucleus were not enclosed in capsules as they were in lipomas; they were scattered between crypts in the lamina propria. There was no evidence of a true adipocyte differentiation. Although it was not immunohistochemically specific, S-100 immune dye staining for any adipose tissue was found negative in our subjects.

DISCUSSION

Mucosal pseudolipomatosis of the colon is a rare benign lesion associated with colonoscopy and usually regresses spontaneously in 3-20 months (2, 6, 7). Different endoscopy units have reported a frequency of 0.3%-1.7% among all colonoscopies performed (1, 2, 8). Our rate was found to be 1.02%.

The endoscopic appearance of colonic pseudolipomatosis is very characteristic. Lesions appear as slightly elevated whitish adherent plaques often multiple and sometimes confluent. The whitish plaques are usually preceded by the appearance of whitish foamy fluid as a result of the effervescent release of molecular oxygen. The plaques extend over several millimeters to 4 cm and can be found equally in the right or left colon (1).

This lesion, which is unfamiliar to endoscopists, must not be confused with similar lesions such as pseudomembranous colitis, colonic lipomatosis, or malakoplakia.

The pathology is characterized by the presence of intramucosal, gas trapped empty spaces ranging between 20 and 130 nanometers in the lamina propria. These empty cavities are similar to fat but differ from lipomatosis by the absence of lipids, which can be verified by fat-specific stains. Because of this gross and microscopic similarity to fat, the lesions are referred to as pseudolipomatosis (1, 9). We also followed the same pathological landmarks to refer to our lesions as pseudolipomatosis.

We did not find a clear emphasis on the gender and age of the patients with colonic pseudolipomatosis in literature. When we talk about our patient group, we can roughly conclude that lesions were seen in a patient group that was unisex and in the fourth decade of their lives.

The pathogenesis of colonic pseudolipomatosis still remains unclear, but the lesion appears to be more of a complication of endoscopy than a real pathological entity. Some authors have suggested that this results from mechanical mucosal injury such as stretching, abrasive trauma, biopsy, or overinflation of the colon during colonoscopy, leading to the penetration of the luminal gas into the bowel wall (2, 10).

Some other authors have also suggested that insufficient rinsing of endoscopes implicate an effect of disinfectants, especially hydrogen peroxide, in the pathogenesis of this lesion. These investigators concluded that residual hydrogen peroxide in the endoscope after rinsing was responsible for colitis and mucosal vacuolisation (7).

Because this was a retrospective study, we did not have enough data to decide on the mechanism of the lesion, but we do know and demonstrated that this is a rare lesion and many endoscopists are simply unaware of the term colonic pseudolipomatosis. Endoscopists can only suspect of the lesion by appearance and must take biopsies to assess the pathological diagnosis.

Our study highlights that although rare, this lesion must be kept in the mind of the endoscopist and that pathological examination will provide an exact diagnosis.

We hope to make this lesion well understood in light of current literature and underline the endoscopic pattern and the diagnostic difficulty.

CONCLUSION

Many endoscopists are unaware of the lesion, and the diagnosis is generally possible only after pathological assessment of multiple biopsies taken from suspect lesions. Here we reported and discussed colonic pseudolipomatosis incidentally found in a series of patients undergoing routine colonoscopy and underline the endoscopic pattern and diagnostic difficulty.

Ethics Committee Approval: Ethics committee approval was received for this study from the ethics committee of İstanbul Training and Research Hospital.

Informed Consent: Because this is a retrospective study, we were not able to provide patient consents.

Peer-review: Externally peer-reviewed.

Author Contributions: Concept - F.E., A.B.T.; Design - F.E., A.B.T., E.Ç., M.E.G.; Supervision - M.E.G., S.Ç., S.S., A.A.; Funding - E.Ç., M.E.G., S.Ç., S.S., A.A.; Materials - F.E., A.B.T., E.P., N.D.; Data Collection and/or Processing - E.Ç., M.E.G., S.Ç., S.S., A.A.; Analysis and/or Interpretation - F.E., A.B.T., E.P., N.D.; Literature Review - E.Ç., M.E.G., S.Ç., S.S., A.A.; Writer - F.E., A.B.T., E.P., N.D.; Critical Review - E.Ç., M.E.G., S.Ç., S.S., A.A., E.P., N.D.

Conflict of Interest: No conflict of interest was declared by the authors.

Financial Disclosure: The authors declared that this study has received no financial support.

REFERENCES

1. Snover DC, Sandstad J, Hutton S. Mucosal pseudolipomatosis of the colon. *Am J Clin Pathol* 1985; 84: 575-580.
2. Waring JP, Manne RK, Wadas DD, Sanowski RA. Mucosal pseudolipomatosis: An air pressure-related colonoscopy complication. *Gastrointest Endosc* 1989; 35: 93-94. [\[CrossRef\]](#)
3. Kim SJ, Baek IH. Colonic mucosal pseudolipomatosis: Disinfectant colitis? *Gastroenterol Nurs* 2012; 35: 208-213. [\[CrossRef\]](#)
4. Cammarota G, Cesaro P, Cazzato A, Fedeli P, Riccioni ME, Sparano L, et al. Hydrogen peroxide-related colitis (previously known as "pseudolipomatosis"): a series of cases occurring in an epidemic pattern. *Endoscopy* 2007; 39: 916-919. [\[CrossRef\]](#)
5. Lapeyre B. The 'frost sign' and the 'snow white sign': Intramucosal air injection or peroxide colitis? *Endoscopy* 2005; 37: 679. [\[CrossRef\]](#)
6. Brevet M, Chatelain D, Bartoli E, Geslin G, Delcenserie R, Braillon A, et al. Colonic pseudolipomatosis: clinical, endoscopic and pathological features in nine cases. *Gastroenterol Clin Biol* 2006; 30: 9-13. [\[CrossRef\]](#)
7. Jonas G, Mahoney A, Murray J, Gertler S. Chemical colitis due to endoscope cleaning solutions: A mimic of pseudomembranous colitis. *Gastroenterology* 1988; 95: 1403-1408.
8. Prignet JM, Carloz E, Kunkel D. Pseudolipomatose muqueuse rectosigmoidienne revelee par une diarrhee chronique. Discussion physiopathologique a propos d' un cas et revue de la litterature. *Acta Endoscopica* 1995; 25: 175-178. [\[CrossRef\]](#)
9. Whitehead R. *Mucosal biopsy of the GI tract*. 1985; Philadelphia, PA: WB Saunders.
10. Sheehan JF, Brynjolfsson G. Ulcerative colitis following hydrogen peroxide enema: Case report and experimental production with transient emphysema of colonic wall and gas embolism. *Lab Invest* 1960; 9: 150-168.