



# A new surgical approach for pilonidal sinus disease: “de-epithelialization technique”

Özgür Dandin<sup>1</sup>, Deniz Tihan<sup>2</sup>, Dursun Özgür Karakaş<sup>3</sup>, Batuhan Hazer<sup>3</sup>, Ahmet Ziya Balta<sup>4</sup>, Oğuz Uğur Aydın<sup>5</sup>

## ABSTRACT

**Objective:** In the treatment of pilonidal sinus disease different approaches are used such as conservative treatment and fasciocutaneous rotation flap. The aim of this study was to evaluate the efficacy of “de-epithelialization technique” as a new approach in pilonidal sinus disease treatment.

**Material and Methods:** Forty pilonidal sinus disease patients treated with de-epithelialization method were evaluated retrospectively. Patient age, gender, body mass index, wound healing time, visual analog scale scores, operation times, hospital stay duration, drain removal time, cosmetic satisfaction rates, complications, and recurrence rates were evaluated.

**Results:** The numbers of male and female patients in this study were 39 and 1, respectively. The median age of the patients was 25 years and the mean BMI was 26.6. The mean operating time was 43 min, and all patients were discharged 5 h after the operation. Wound healing time varied from 10 to 20 days. Median follow-up period was 9 months (4-17 months). One patient with high body mass index suffered from partial wound separation. No other complications such as infections and fluid collections (hematoma and seromas) were observed. Maximum cosmetic satisfaction rate was 90% (n=36), and no patient had a recurrence during the follow-up period.

**Conclusion:** “De-epithelialization” may be considered as a complementary and/or alternative approach to other surgical techniques such as primary closure, rhomboid excision, and Limberg flap in the treatment of pilonidal sinus disease, with acceptable cosmesis and recurrence rates.

**Keywords:** De-epithelialization, flap, natal cleft, pilonidal sinus disease, sacrococcygeal region

## Cite this paper as:

Dandin Ö, Tihan D, Karakaş DÖ, Hazer B, Balta AZ, Aydın OU. A new surgical approach for pilonidal sinus disease: “de-epithelialization technique”. Turk J Surg 2018; 34: 43-48.

<sup>1</sup>Department of General Surgery, Bursa Military Hospital, Bursa, Turkey

<sup>2</sup>Department of General Surgery, Yüksek İhtisas Training and Research Hospital, Bursa, Turkey

<sup>3</sup>Department of General Surgery, Kasımpaşa Military Hospital, İstanbul, Turkey

<sup>4</sup>Department of General Surgery, Gülhane Military Medical Academy Haydarpaşa Training Hospital, İstanbul, Turkey

<sup>5</sup>Department of General Surgery, Güven Hospital, Ankara, Turkey

## Address for Correspondence

Özgür Dandin  
e-mail: dandinozgur@gmail.com

Received: 29.05.2016

Accepted: 18.11.2016

Available Online Date: 04.01.2018

©Copyright 2018  
by Turkish Surgical Association  
Available online at  
www.turkjsurg.com

## INTRODUCTION

Pilonidal sinus disease (PSD) is a common disorder of the sacrococcygeal region (1). The incidence is reported in 6 per 100,000 individuals (2). However, the etiopathogenesis is still unclear. Further, it has recently been suggested to be an acquired disease by some authors (3, 4).

Treatment of pilonidal sinus is still controversial and different surgical methods have been applied (1, 5, 6). However, rates of complications and recurrences vary, and yet there is no consensus on a specific technique. Different surgical methods have been compared for many years. The main factors to be considered to form an ideal treatment procedure are practical surgical technique, shorter length of stay at the hospital, short recovery period, fewer postoperative complications and pain, low rates of recurrence (1). In all techniques (primary closure or flap), a cavity is created after the excision of the pilonidal cyst accompanying healthy tissue; this should be filled or closed, or else it causes is a technical problem, which is frequently encountered, and can result in complications such as “dead space”, hematoma, wound infection, and wound separation during the early postoperative period (7, 8). The main drawback is the complication of wound healing. Hypoesthesia and cosmetic problems of the sacrococcygeal region are also seen, especially in flap technique, at the late period (9). This method is defined as a flap or graft of thinned cutaneous layer (10). Aesthetic surgeons usually perform this method for mammoplasty. Basically, in this method, after de-epithelialization of the cutaneous tissue is performed, cutaneous flap and fatty tissue are inverted to create the breast protrusion (11). De-epithelialized skin grafts are used for many indications.

The aim of the study is to describe and discuss the “de-epithelialization technique” as a new approach in PSD treatment.

## MATERIAL AND METHODS

During the year 2013, at Bursa Military Hospital, Department of General Surgery, 40 patients with the diagnosis of PSD were treated with de-epithelialization method. All patients were operated by the same surgeon. In order to evaluate the technique, complicated pilonidal sinus cases, such as infective sinus, cavity abscess, recurrent disease, were excluded from the study and only uncomplicated PSDs were operated.

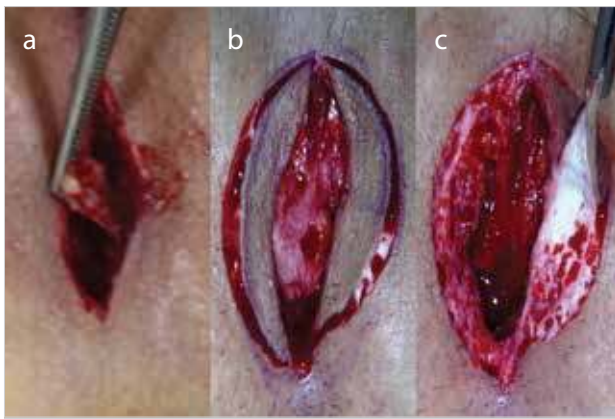


Figure 1. a-c. (a) Excision of the cyst, (b) partial thickness elliptical intradermal incision, (c) de-epithelialization by applying traction force both at 90° angle to the surface with scalpel blade

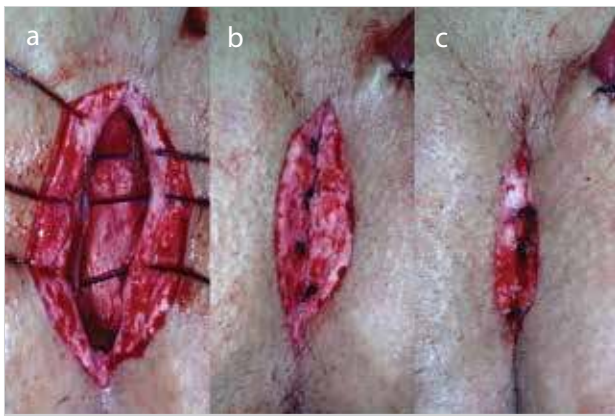


Figure 2. a-c. (a) Primary closure of free edges of the de-epithelialized skin, (b, c) inversion and primary closure of de-epithelialized wound

Patient data including gender, age, body mass index (BMI), operational time, postoperative length of hospital stay, pain score at 24 h (using a visual analog pain scale), wound healing period, postoperative complications (wound dehiscence and infection, seroma, hematoma, etc.), and recurrence were retrospectively evaluated from the hospital records. In the first-month outpatient follow-up, subjective evaluation of postoperative cosmetic results was also recorded (1 to 5; 1=worst, 5=best result). During the follow-up period, the patients were invited to the clinics by phone.

### Surgical Procedure

The patient was placed in the prone position with the buttocks taped apart for exposing the natal cleft. Subsequent to the skin disinfection via povidone iodine, 20 mL of 2%prilocaine was applied to the sacrococcygeal area around the surgical site for local anesthesia. The tract was then delineated, using a sterile solution of methylene blue, injected via a plastic cannula. Thereafter, a flat intergluteal incision of approximately 5 cm in length and till the postsacral fascia in depth was performed. Pilonidal cyst and tract were exposed and excised with surrounding healthy fatty tissue but the surrounding cutaneous and some subcutaneous tissue were preserved (Figure 1a). An elliptical intradermal incision of partial thickness was made with a number 10 scalpel

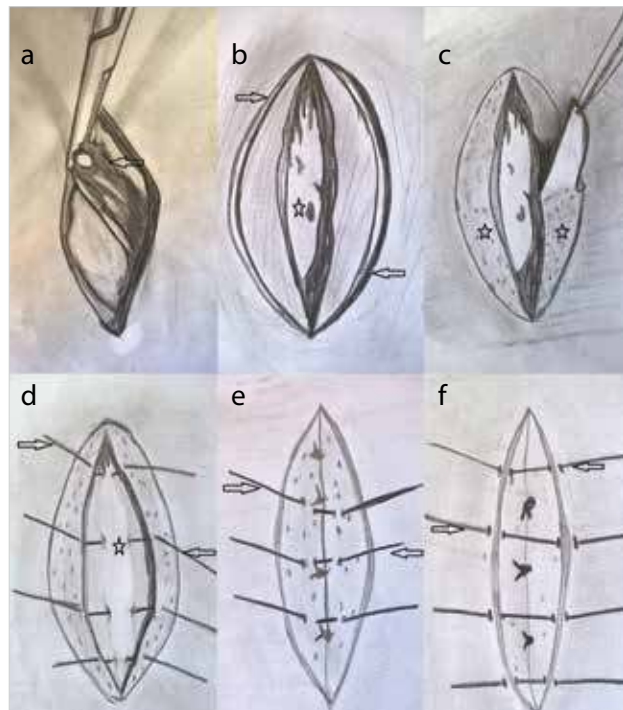


Figure 3. a-f. Drawing of the de-epithelialization technique. (a) Excision of the cyst tissue with surrounding healthy fatty tissue (arrow) and created cyst cavity (star), (b) determination of the oval shaped de-epithelialization line (arrows) with a scalpel, (c) de-epithelialized skin (stars) skin covering the cyst tissue, (d) first suturation of the free edges of de-epithelialized wound with absorbable sutures (arrows), which were fixed to the presacral fascia (star), (e) inversion and second suturation (arrows) for reciprocal overlapping with absorbable sutures (f), Primary closure of the wound with nonabsorbable sutures (arrows)

blade, limited by the upper and lower point of the intergluteal incision including sinus orifices (Figure 1b). Thus, this ellipsoid area was easily de-epithelialized by applying traction force both at 90-degree angle to the surface with the scalpel blade, similar to “peeling an orange” (Figure 1c). A Penrose drain was placed in the cavity. The drain was passed through the tract orifice. Primarily, the first suturations were performed between edge of the de-epithelialized skin, presacral fascia and the other reciprocal free edge, respectively, with 0 nonabsorbable suture sutured (Figure 2a). Subsequently, the de-epithelialized wound was inverted and sutured to cause reciprocal overlapping with 3/0 nonabsorbable sutures (Figure 2b, c). Finally, the wound was closed primarily with 3/0 nonabsorbable sutures. Thus, the cavity of excised pilonidal cyst was filled by inverting de-epithelialized skin. The drawing of the technique is shown in Figure 3a-f. Diclofenac sodium (intramuscular and/or oral) was used for postoperative analgesia.

### Statistical Analysis

Statistical Package for the Social Sciences version 20.0, (IBM Corp.; Armonk, NY, USA) computer program was used for statistical analyses. As the number of patients was 40 (<50), variables distribution was tested by Shapiro-Wilk normality test ( $p>0.05$  was accepted as the normal distribution).

Table 1. Demographic findings and characteristics of the patients

Age* (years)	25 (17-37)
Sex (M/F)	39/1
Body mass index** (kg/m <sup>2</sup> )	26.60±3.76
Operational time** (minutes)	43.02±4.73
Stay of drain* (days)	3 (2-4)
Suture removal time=wound healing time* (days)	10 (10-20)
Follow-up* (months)	9 (4-17)
Complications***	1 (2.5)
Recurrence***	0 (0)
M: male; F: female The datas are presented as *mean (range); **mean±standard deviation; ***n (%)	

Table 2. Drain removal time

Drainage tube removal time (days)	n (%)
2	11 (27.5)
3	19 (47.5)
4	10 (25)

Table 3. Suture removal (wound healing) time

Suture removal time (Wound healing time) (days)	n (%)
10	23 (57.5)
12	6 (15)
15	10 (25)
20	1 (2.5)

Table 4. Visual analogue pain scale (VAS) of the patients at 24<sup>th</sup> postoperative hour

Visual analog pain score (VAS)	n (%)
1	3 (7.5)
2	8 (20)
3	11 (27.5)
4	11 (27.5)
5	5 (12.5)
6	2 (5)

Table 5. Cosmetic satisfaction of the patients after suture removal (1 point=very bad; 5 points=excellent cosmesis)

Cosmesis score	n (%)
5	36 (90)
4	2 (5)
3	2 (5)

Continuous variables showing normal distribution were expressed as mean±standard deviation; non-parametric continuous variables were expressed as median and minimum-maximum. Categorical variables were expressed as

percentages (%). For all statistical analyses p<0.05 was accepted as significant.

## RESULTS

Forty patients were operated with this technique. Thirty-nine of all cases were male (97.5%). The median age of the patients was 25 year (17-37 years) and mean BMI was 26.6±3.76 (21-36.5). The mean operating time was 43.02±4.73 min (33-52 min) (Table 1).

All patients were operated under local anesthesia and discharged on the 5th postoperative hour. Median drainage time was 3 days (2-4 days) (Table 2). Wound healing time varied from 10 to 20 days. The sutures were removed after 10 days in 23 patients (57.5%), 12 days in six patients (30%), and 15 days in 10 patients (25%) (Table 3). In one patient, whose BMI was 36.5, the suture was removed on the 20th postoperative day. Median follow-up period was 9 months (4-17 months).

None of the patients had a recurrence, wound infection, seroma, hematoma, or complete wound separation during follow-up. There was partial wound separation in only one overweight patient with a history of hypertension. For 11 patients (27.5%), the postoperative 24-h visual analog pain scale (VAS) rating was 3, and for 11 other patients, it was 4 (Table 4). The maximum cosmetic satisfaction rate was 90% (n=36) (1 point=worst cosmesis, 5 points=best cosmesis) (Table 5). In two patients, wound cosmesis was 4 points, and in two patients, it was 3 points. We observed that de-epithelialization method provide the flattening of natal cleft in all patients.

## DISCUSSION

“de-epithelialization” is not a new surgical technique, and has been performed successfully since 1970’s in mammoplasty by plastic and reconstructive surgeons (12-14). This technique has been used for many rare indications in various specialist areas. Yoon et al. (15) used this for reconstructing oral and/or oropharyngeal defects after surgically removing the tumor. Additionally, Jun Hee Lee et al. (16) treated finger defects with exposed tendon or bone by using de-epithelialized cutaneous graft of the wound edges. Balat et al. (17) obtained satisfactory result after using de-epithelialized rhomboid flap in the treatment of vulvar cancer. In another case, a patient who had Peyronie’s disease was treated with penile reconstruction using a de-epithelialized Belman (superficial external pudendal artery) flap and the result was well (18). In a case series by Park et al. (19), bronchopleural fistulas were obliterated using a musculocutaneous flap of serratus anterior after de-epithelialization. Additionally, a right ventricle rupture related to sternal wound infection was reconstructed by utilizing de-epithelialized myocutaneous latissimus dorsi flap which is previously published (20). Gupta et al. (21) demonstrated that in the repair of hypospadias after Snodgrass urethroplasty, using a de-epithelialized flap for the extra covering of the constructed neourethra was a good option.

According to our knowledge, no study has been found in English literature reporting the use of de-epithelialization in PSD treatment so far. Thus, we decided to apply this well-known surgical procedure to PSD.

Over the years, many different techniques have been described as PSD treatment modalities. For instance, Thompson et al. (22) proposed simple removal of midline skin pits without wide excisions. Likewise, as a minimally invasive approach, therapeutic ablation of cavity epithelia with phenol or radiofrequency were suggested by some authors instead of cyst excision (5, 23, 24). Washer et al. (25) described a much more complicated flap technique (gluteal fascial advancement) as a perfect method to cure PSD. In this text, there is no consensus on the “gold standard” surgical approach. Obviously, the chosen technical method may differ with the experience of the surgeon and patient condition. Nevertheless, widely accepted prospects for an ideal PSD treatment should be based on principles such as a practical and painless technique, rapid discharge from the hospital, minimal postoperative complications, and also low rates of recurrence.

The overall success rate of phenol application varies between 67% and 95% in most reported studies (5, 23, 26). Khan et al. (27) report the recurrence rate after the primary closure technique to be 8% in their study. In their prospective randomized study, Dass et al. (28) indicated the success of the Limberg flap to be up to 100%. Recurrences were noted in 2% of patients in the case series of Yildiz et al. (29) who performed the Karydakias flap procedure.

Although the median follow-up period (9 months) is relatively short in our series, during the follow-up period, none of the patients had a recurrence. Flattening the natal cleft, which was the outcome of the de-epithelialization technique, could be the main reason of the low recurrence rate. As a matter of fact, flattening of the natal cleft and lateralization have already been described by Yildiz et al. (29) as the goal of an ideal treatment for PSD. However, the data will need to be reevaluated at the end of a longer follow-up period.

In practice, wide excision with flap reconstruction is usually performed under spinal anesthesia and the patients need to spend at least one night in the hospital (5). De-epithelialization is a less invasive method and can be performed under local anesthesia, which prevents the complications of spinal anesthesia, and allows patients to get discharged on the very same day of the procedure. Additionally, the mean operational time is found to be relatively shorter ( $43.02 \pm 4.73$  min) compared with other excisional procedures. For instance, in the randomized clinical trial by Khan et al. (27), the mean operating time in excision+primary closure group was reported as 55 min and in excision+Limberg flap group as 70 min; in the randomized study by Dass et al. (28), the mean operating time for primary closure was 44 min.

It is well-known that the presence of hematoma, seroma, and wound infection are risk factors for recurrence (30). Kirkil et al. (31) mentioned that the complication rates of drained and non-drained Limberg flap group were 17.8% and 29.6%, respectively. Käser et al. (32) reported the overall complication percentage as 49% in Limberg flap group and 12% in the excision only group. In the study of Arslan et al. (30), 19.8% seroma formation and 15.4% wound dehiscence was noted in patients treated with Karydakias flap procedure. We did not observe any wound infection, seroma, and/or hematoma formation in our

series, and only one overweight patient (BMI=36.5) had partial wound dehiscence and was treated by leaving the open part of the wound for secondary healing. It was considered that the causes of satisfactory result in the early period were reducing the cavity by inverting de-epithelialized skin graft and protecting the seroma and/or hematoma, wound infection and dehiscence caused by dead space. However, mean BMI of our study group was found to be  $26.6 \pm 3.76$ , which is mildly higher than the normal upper limit. Thus, the correlation between BMI and wound complication should be evaluated in larger series.

In their study, Kirkil et al. (31) question the efficiency of cavity drainage: they compared complication rates between drained and non-drained Limberg flap groups and found that these rates were similar. Herewith the authors claimed that routine drain usage did not affect surgical site complications in Limberg flap technique for PSD (31). We chose to use an aspiration drain in every case intending to avoid intracavitary seroma and/or hematoma, but a controlled randomized study is required to evaluate the drain's effectiveness in a better manner. In their randomized clinical trial, Akca et al. (33) remarked that median pain VAS score was 4 in excision and primary closure group and 2 in rhomboid excision and Limberg flap technique. Käser et al. (32) found 2.4 and 2.5 as mean pain score at discharge in Limberg flap group and excision only group, respectively. Dass et al. (28) pointed out the association between wound tension and increased pain VAS score and claimed that primary closure was a more painful technique. In our study, median pain VAS score was found to be 3 (range, 1-6), concordant to pain scores of other described surgical methods. However, as expected, less invasive procedures such as radiofrequency seem to cause less postoperative pain (34).

Arslan et al. (30) categorized first-postoperative-year patient satisfaction in four ratings as “excellent,” “good,” “not bad,” and “bad.” In all different flap groups (Limberg, modified Limberg, and Karydakias flap group) total “excellent” and “good” patient satisfaction ratings at the end of the first year were 74%, 78%, and 70%, respectively. In our study, 90% of all 40 patients indicated their cosmetic satisfaction rate as “excellent” (score=5). None of the patients described the cosmetic results as “bad” (score=2) or “very bad” (score=1). Better patient cosmesis was only reported in studies investigating the less invasive interventions, such as phenol application or cavity ablation (5, 34).

#### Study Limitations

We have some limitations in our study. It has a retrospective nature and a relatively short follow-up period. Further, the exclusion of complicated patients was a limitation for this study; thus, the results of de-epithelialization technique in complicated PSD cases should be further evaluated in larger randomized studies. Another limitation was the lack of prospective comparison of the reported approach with a widely common other technique; there is no control group to evaluate any new proposition. However, there are many reports of various surgical techniques such as marsupialization, Karydakias, oblique primary repair, and flap techniques in the literature. Therefore, this may not be regarded as a complete limitation.

## CONCLUSION

Healthy, fresh dermal bed with high vascularity was obtained with de-epithelialized flap. Thus, some complications such as wound separation can be prevented by providing stronger wound healing. We also planned to minimize the cavity after excision by inverting de-epithelialized tissue with this technique in PSD surgery. Moreover, de-epithelialization of skin is easy. Our new technique provides a short operation time, short duration of hospital stay, and less postoperative morbidity. The major advantage of this technique is the absence of any need for hospitalization. It allows a quicker return to daily activities and reduces costs. Furthermore, we believe that the risk of recurrence may be reduced by increasing the angle of the natal cleft during this technique. Also, this method has a satisfying aesthetic outcome.

Currently, we continue this study to see the long-term results of this technique and for comparison with other techniques. This preliminary report suggests that this new surgical approach seems to be a reasonable method in the treatment of PSD, especially in patients with uncomplicated primary disease, and is worth studying further.

**Ethics Committee Approval:** Ethics committee approval was received for this study from the ethics committee of Bursa Şevket Yılmaz Training and Research Hospital (2011-KAEK-25 2015/23-06).

**Informed Consent:** Written informed consent was obtained from patients who participated in this study.

**Peer-review:** Externally peer-reviewed.

**Author Contributions:** Concept - O.D., D.T.; Design - D.O.K.; Supervision - A.Z.B., B.H.; Resource - O.O.A.; Materials - O.D.; Data Collection and/or Processing - O.D., B.H.; Analysis and/or Interpretation - D.T.; Literature Search - O.D., D.O.K.; Writing Manuscript - D.T., B.H.; Critical Reviews - A.Z.B.; Other - O.D.

**Conflict of Interest:** No conflict of interest was declared by the authors.

**Financial Disclosure:** The authors declared that this study has received no financial support.

## REFERENCES

- Abdel-razek E. Cleft lift operation for recurrent pilonidal sinus repair; two years experience. *Egypt J Plast Reconstr Surg* 2006; 30: 7-11.
- McCallum IJ, King PM, Bruce J. Healing by primary closure versus open healing after surgery for pilonidal sinus: systematic review and meta-analysis. *BMJ* 2008; 336: 868-871. [\[CrossRef\]](#)
- Doll D, Friederichs J, Dettmann H, Boulesteix AL, Duesel W, Petersen S. Time and rate of sinus formation in pilonidal sinus disease. *Int J Colorectal Dis* 2008; 23: 359-364. [\[CrossRef\]](#)
- Tavassoli A, Noorshafie S, Nazarzadeh R. Comparison of excision with primary repair versus Limberg flap. *Int J Surg* 2011; 9: 343-346. [\[CrossRef\]](#)
- Akan K, Tihan D, Duman U, Ozgun Y, Erol F, Polat M. Comparison of surgical Limberg flap technique and crystallized phenol application in the treatment of pilonidal sinus disease: a retrospective study. *Ulus Cerrahi Derg* 2013; 29: 162-166.
- Maghsoudi H, Nezami N, Ghamari AA. Ambulatory treatment of chronic pilonidal sinuses with lateral incision and primary suture. *Can J Surg* 2011; 54: 78-82. [\[CrossRef\]](#)
- Kapan M, Kapan S, Pekmezci S, Durgun V. Sacrococcygeal pilonidal sinus disease with Limberg flap repair. *Tech Coloproctol* 2002; 6: 27-32. [\[CrossRef\]](#)
- Petersen S, Aumann G, Kramer A, Doll D, Sailer M, Hellmich G. Short-term results of Karydakis flap for pilonidal sinus disease. *Tech Coloproctol* 2007; 11: 235-240. [\[CrossRef\]](#)
- Muller K, Marti L, Tarantino I, Jayne DG, Wolff K, Hetzer FH. Prospective analysis of cosmesis, morbidity, and patient satisfaction following Limberg flap for the treatment of sacrococcygeal pilonidal sinus. *Dis Colon Rectum* 2011; 54: 487-494. [\[CrossRef\]](#)
- Draf W. Possibilities of reconstruction by de-epithelization (author's transl). *Laryngol Rhinol Otol (Stuttg)* 1981; 60: 564-570. [\[CrossRef\]](#)
- Masuoka T, Sugita A, Sekiya S, Ohmori K. Breast reconstruction with perforator-based inframammary de-epithelialized flap: a case report. *Aesthetic Plast Surg* 2002; 26: 211-214. [\[CrossRef\]](#)
- Parsons RW, Knieser M. "De-epithelization" of the dermal pedicle in a reduction mammoplasty. *Plast Reconstr Surg* 1976; 57: 619-620. [\[CrossRef\]](#)
- Trabanino CR. The spiral, or string, dissection for "de-epithelialization" in reduction mammoplasty. *Plast Reconstr Surg* 1978; 62: 806-807. [\[CrossRef\]](#)
- Wintch K. A new technique for reduction mammoplasty. *Aesthetic plastic surgery* 1978; 2: 349-355. [\[CrossRef\]](#)
- Yoon J, Yim JH, Kim EK. Simplified Designing and Insetting of the Free Flap in Reconstructing Oral and/or Oropharyngeal Defect. *J Craniofac Surg* 2015; 26: 2004-2007. [\[CrossRef\]](#)
- Lee JH, Burm JS, Kang SY, Yang WY. Full-thickness skin grafting with de-epithelization of the wound margin for finger defects with bone or tendon exposure. *Arch Plast Surg* 2015; 42: 334-340. [\[CrossRef\]](#)
- Balat O, Tercan M, Bekerecioglu M, Aydin A, Karakok M, Kutlar I. Adenoid cystic carcinoma of the vulva: conservative surgery using a de-epithelialized rhomboid flap. *Eur J Gynaecol Oncol* 2001; 22: 387-388.
- Abe S, Takami Y, Yamaguchi Y, Hata K, Yamaguchi T. Penile reconstruction with de-epithelialized superficial external pudendal artery flap. *J Urol* 1992; 147: 155-157. [\[CrossRef\]](#)
- Park JS, Eom JS, Choi SH, Kim YH, Kim EK. Use of a serratus anterior musculocutaneous flap for surgical obliteration of a bronchopleural fistula. *Interact Cardiovasc Thorac Surg* 2015; 20: 569-574. [\[CrossRef\]](#)
- Hakala T, Berg L, Berg E, Makinen K, Sipola P. Repair of right ventricular free wall defect with a de-epithelialized pedicled myocutaneous latissimus dorsi muscle flap. *Ann Thorac Surg* 2005; 80: 2360-2362. [\[CrossRef\]](#)
- Gupta AK, Sarda D, Kothari PR, Jiwane A, Kulkarni BK. Tubularized incised plate urethroplasty with de-epithelialized flap. *Afr J Paediatr Surg* 2008; 5: 8-10. [\[CrossRef\]](#)
- Thompson MR, Senapati A, Kitchen P. Simple day-case surgery for pilonidal sinus disease. *Br J Surg* 2011; 98: 198-209. [\[CrossRef\]](#)
- Dag A, Colak T, Turkmenoglu O, Sozutek A, Gundogdu R. Phenol procedure for pilonidal sinus disease and risk factors for treatment failure. *Surgery* 2012; 151: 113-117. [\[CrossRef\]](#)
- Gupta PJ. Comparative study between radiofrequency sinus excision and open excision in sacro-coccygeal pilonidal sinus disease. *Dig Surg* 2005; 22: 459-463. [\[CrossRef\]](#)
- Washer JD, Smith DE, Carman ME, Blackhurst DW. Gluteal fascial advancement: an innovative, effective method for treating pilonidal disease. *Am Surg* 2010; 76: 154-156.
- Dogru O, Camci C, Aygen E, Girgin M, Topuz O. Pilonidal sinus treated with crystallized phenol: an eight-year experience. *Dis Colon Rectum* 2004; 47: 1934-1938. [\[CrossRef\]](#)
- Khan PS, Hayat H, Hayat G. Limberg flap versus primary closure in the treatment of primary sacrococcygeal pilonidal disease: a randomized clinical trial. *Indian J Surg* 2013; 75: 192-194. [\[CrossRef\]](#)

28. Dass TA, Zaz M, Rather A, Bari S. Elliptical excision with midline primary closure versus rhomboid excision with Limberg flap reconstruction in sacrococcygeal pilonidal disease: a prospective, randomized study. *Indian J Surg* 2012; 74: 305-308. [\[CrossRef\]](#)
29. Yildiz MK, Ozkan E, Odabasi HM, Kaya B, Eris C, Abuoglu HH, et al. Karydakias flap procedure in patients with sacrococcygeal pilonidal sinus disease: experience of a single centre in Istanbul. *ScientificWorldJournal* 2013; 2013: 807027. [\[CrossRef\]](#)
30. Arslan K, Kokcam SS, Koksall H, Turan E, Atay A, Dogru O. Which flap method should be preferred for the treatment of pilonidal sinus? A prospective randomized study. *Tech Coloproctol* 2014; 18: 29-37. [\[CrossRef\]](#)
31. Kirkil C, Boyuk A, Bulbuller N, Aygen E, Karabulut K, Coskun S. The effects of drainage on the rates of early wound complications and recurrences after Limberg flap reconstruction in patients with pilonidal disease. *Tech Coloproctol* 2011; 15: 425-429. [\[CrossRef\]](#)
32. Käser S, Zengaffinen R, Uhlmann M, Glaser C, Maurer C. Primary wound closure with a Limberg flap vs. secondary wound healing after excision of a pilonidal sinus: a multicentre randomised controlled study. *Int J Colorectal Dis* 2015; 30: 97-103. [\[CrossRef\]](#)
33. Akca T, Colak T, Ustunsoy B, Kanik A, Aydin S. Randomized clinical trial comparing primary closure with the Limberg flap in the treatment of primary sacrococcygeal pilonidal disease. *Br J Surg* 2005; 92: 1081-1084. [\[CrossRef\]](#)
34. Gupta PJ. A randomized study between excision and marsupialization and radiofrequency sinus excision in sacro-coccygeal pilonidal disease. *Curr Surg* 2004; 61: 307-312. [\[CrossRef\]](#)