



# Gossypiboma mistaken for a hydatid cyst

Bahadır Osman Bozkırlı<sup>1</sup> , Rıza Haldun Gündoğdu<sup>2</sup> , Pamir Eren Ersoy<sup>3</sup> , Soner Akbaba<sup>2</sup> , Mehmet Oduncu<sup>4</sup> 

## ABSTRACT

Although considered a rare complication, gossypiboma continues to be a clinically important and probably more frequently encountered than reported situation. Here we present a case of gossypiboma that was mistaken for a hydatid cyst in the preoperative evaluation. A 34-year-old male patient with a history of Nissen fundoplication presented with a large mass palpable in the epigastrium and both the left upper and lower quadrants of the abdomen. Computed tomography was reported to show a 20×18 cm cystic mass with a collapsed germinative membrane inside it. Laparotomy, which was performed with a suggested diagnosis of type 3 hydatid cyst, revealed that the mass was caused by a 30×30 cm surgical abdominal compress. We believe gossypiboma should be kept in mind in the differential diagnosis of abdominal hydatid cysts in the presence of a former abdominal operation, especially when the result of the indirect hemagglutination test is negative.

**Keywords:** Gossypiboma, retained foreign body, hydatid cyst

## Cite this paper as:

Bozkırlı BO, Gündoğdu RH, Ersoy PE, Akbaba S, Oduncu M. Gossypiboma mistaken for a hydatid cyst. Turk J Surg 2018; 10.5152/turkjsurg.2017.3742

*This study was presented at the XVI. Annual Meeting of the European Society of Surgery, 22-24 November 2012, Istanbul, Turkey.*

<sup>1</sup>Department of General Surgery, Ankara Training and Research Hospital, Ankara, Turkey

<sup>2</sup>Department of General Surgery, Ankara Atatürk Training and Research Hospital, Ankara, Turkey

<sup>3</sup>Department of General Surgery, Güven Hospital, Ankara, Turkey

<sup>4</sup>Department of General Surgery, Samandağ Güneypark Hospital, Hatay, Turkey

## Address for Correspondence

**Bahadır Osman Bozkırlı**  
e-mail: bbozkirli@gmail.com

Received: 23.10.2016

Accepted: 31.01.2017

Available Online Date: 03.01.2018

©Copyright 2018  
by Turkish Surgical Association  
Available online at  
www.turkjsurg.com

## INTRODUCTION

Gossypiboma is the term that is used to describe a mass of cotton matrix or surgical sponge accidentally retained in the body after surgery (1). Although considered a rare complication, it continues to be a clinically important and probably more frequently encountered than reported situation (2, 3). Because of its nonspecific symptomatology and as it can stay asymptomatic for years, its diagnosis is difficult (4). It may mimic an abdominal or pelvic soft tissue tumor and on abdominal computed tomography (CT), it may be indistinguishable from an abdominal abscess (5). Thoracic gossypibomas can even be mistaken for echinococcal lesions (6).

Here we present an abdominal case of gossypiboma that was mistaken for a hydatid cyst in the preoperative evaluation.

## CASE PRESENTATION

A 34-year-old male patient was admitted to our clinic with complaints of nausea and vomiting after meals and abdominal distention that was apparent for the last 5 months. The patient had a history of Nissen fundoplication performed using open approach 10 years ago. On physical examination, there was a median laparotomy incision from the tip of the xiphoid to the umbilicus. A large mass was palpable in the epigastrium and both the left upper and lower quadrants of the abdomen. The laboratory tests, including the indirect hemagglutination test, were in normal range. Abdominal CT revealed a 20×18 cm calcified cystic mass with a collapsed germinative membrane inside it. The lesion was in close proximity to the left lobe of the liver, the stomach, and the spleen, pushing the stomach to the superior right and the spleen to the superior left (Figure 1). The esophagogastroduodenoscopy showed a non-expanding stomach with hyperemic mucosa.

Although the indirect hemagglutination test was negative, the patient was operated with a suggested diagnosis of type 3 hydatid cyst. Laparotomy revealed a large mass, filling the epigastrium and expanding into both left upper and lower quadrants of the abdomen. The pseudocapsule of the mass was impossible to dissect from the adjacent structures. When the pseudocapsule was opened, 3 L of brown-black, non-smelly liquid discharged. In the cystic cavity, there was a 30×30 cm surgical abdominal compress near the esophageal hiatus (Figure 2, 3). The compress was extracted and the cavity was washed with saline. After the insertion of a drain into the cavity, the abdomen was closed. The patient was discharged from the hospital on the second postoperative day without any problems, and he was healthy at the 5-year follow-up.

The patient gave informed consent allowing his medical information to be used in medical research and scientific papers.

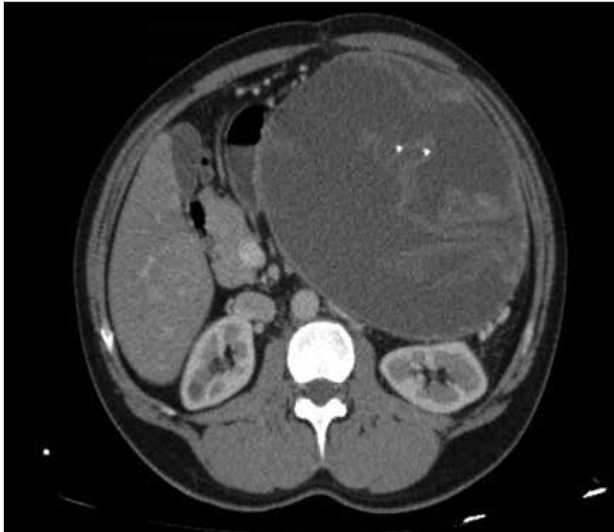


Figure 1. CT view of the calcified cystic mass

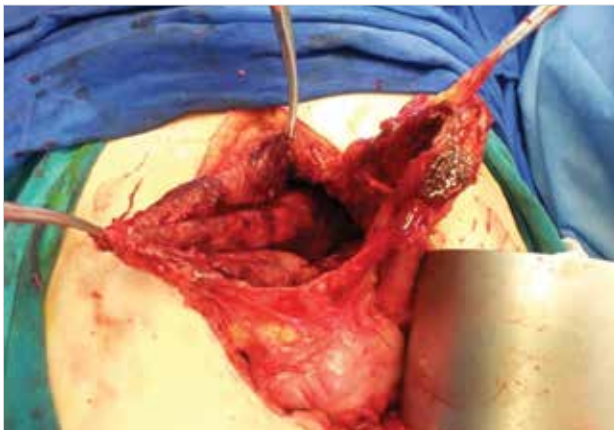

Figure 2. Cavity of the pseudocyst

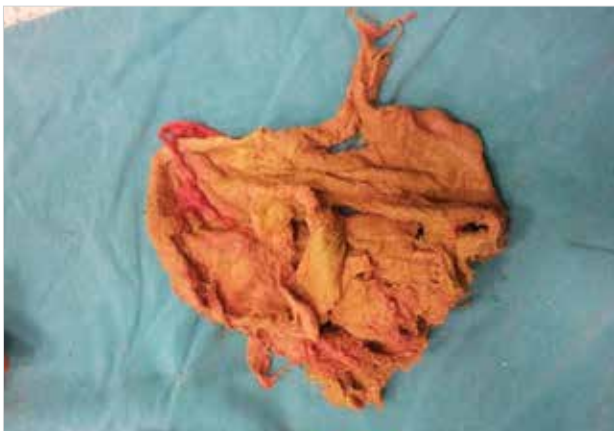


Figure 3. The extracted sponge

## DISCUSSION

The estimated incidence of gossypibomas is highly variable, ranging from one in 100 to one in 19000 cases; because many cases go unreported due to medico-legal problems, the incidence is quite difficult to predict (3, 7, 8).

There are two sorts of foreign body reactions caused by retained sponges. The first is an aseptic fibrous reaction result-

ing in adhesions, encapsulation, and granuloma formation. These patients may remain asymptomatic or present with a pseudotumor syndrome. The other sort of reaction involves exudative inflammatory reaction with abscess formation or chronic external or internal fistula formation (7).

The clinical presentation may vary according to the location of the foreign body (7). Symptoms and clinical findings are usually nonspecific and may include nonspecific abdominal pain, nausea, vomiting, and a palpable mass or intestinal obstruction (5). The symptoms may appear early during the postoperative period or the situation may remain asymptomatic for years and some cases may even never be discovered (7). The median time for the cases to be discovered is reported to be 7 years, and there are reports of foreign bodies remaining undetected for 40 years (2, 9). In our case, the patient had been asymptomatic for 10 years.

Radiographs are the most commonly used method to detect retained sponges (5). Generally surgical sponges have radiopaque markers that facilitate detection with standard radiography; however, in some institutions, sponges without these markers are still being used decreasing the chance of detection of gossypibomas by direct radiography and even by abdominal CT (10). The absence of such a marker in our case contributed to the confusion in the radiologic diagnosis.

On CT, the spongiform pattern with gas bubbles is the most characteristic sign for gossypibomas (5). As a result, early in the postoperative period, the differential diagnosis includes hematoma and abscess. However, in time, the air trapped in the foreign material is absorbed and in the absence of a radiopaque marker, as in our case, lesions appear with or without whirl-like high-density stripes (6). Differentiation from neoplasms or degenerated hydatid cysts may be difficult at this stage (6). Hydatid cysts are highlighted in the differential diagnosis of thoracic gossypibomas (6). However, to the best of our knowledge, there are only six cases of gossypiboma in the literature together with the present case to be mistaken for an abdominal hydatid cyst during preoperative evaluation (7, 11-14). All of these cases were reported from countries in which echinococcosis is endemic.

Indirect hemagglutination test, which is frequently used in combination with radiologic tests in the diagnosis of hydatid cysts, has a sensitivity varying between 60%-100% (15). Therefore, when deciding for a surgical operation with a suggested diagnosis of a hydatid cyst, we rely on the radiologic tests more than the indirect hemagglutination test.

## CONCLUSION

We believe that gossypiboma should be kept in mind in the differential diagnosis of abdominal hydatid cysts in the presence of a former abdominal operation. A negative indirect hemagglutination test may urge the surgeon to suspect the condition even if the abdominal CT suggests an echinococcal lesion. This is especially important in countries with a high incidence of hydatid cysts as these will be the countries in which the lesion is most likely to be mistaken for an echinococcal lesion.

**Informed Consent:** Written informed consent was obtained from patient who participated in this study.

**Peer-review:** Externally peer-reviewed.

**Author Contributions:** Concept - B.O.B., R.H.G., P.E.E.; Design - B.O.B., S.A., M.O.; Supervision - R.H.G., P.E.E.; Resource - R.H.G., P.E.E.; Materials - P.E.E., M.O., B.O.B.; Data Collection and/or Processing - B.O.B., P.E.E., M.O.; Analysis and/or Interpretation - B.O.B., S.A., P.E.E., R.H.G.; Literature Search - B.O.B., P.E.E., S.A., M.O.; Writing Manuscript - B.O.B., S.A., M.O.; Critical Reviews - R.H.G., P.E.E.

**Conflict of Interest:** No conflict of interest was declared by the authors.

**Financial Disclosure:** The authors declared that this study has received no financial support.

## REFERENCES

- De Campos FF, Franco F, Maximiano LF, Martinês JA, Felipe-Silva AS, Kunitake TA. An iron deficiency anemia of unknown cause: A Case Report involving gossypiboma. *Clinics* 2010, 65: 555-558. [\[CrossRef\]](#)
- Ersoy E, Ozdogan M, Kulaçoglu H, Gundogdu H. Retained foreign body in the axillary region. *East Mediterr Health J* 2008, 14: 217-219.
- Kreuter M, Eberhardt R, Wiebel M, Schulz MR, Mueller KM, Herth FJA. A 65 year old man with an Endobronchial gossypiboma after lobectomy for abscessing pneumonia. *Respiratory Care* 2010, 55: 933-936.
- Kim CK, Park BK, Ha H. Gossypiboma in abdomen and pelvis: MRI findings in four patients. *AJR Am J Roentgenol* 2007; 189: 814-817 [\[CrossRef\]](#).
- Manzella A, Filho PB, Albuquerque E, Farias F, Kaercher J. Imaging of Gossypibomas: Pictorial Review. *AJR Am J Roentgenol* 2009, 193: 94-101. [\[CrossRef\]](#)
- Karabulut n, Herek D, Kiroğlu Y. CT features of intrathoracic gossypiboma (textiloma). *Diagn Interv Radiol* 2011; 17: 122-124.
- Akbulut S, Arıkanoglu Z, Yagmur Y, Basbug M. Gossypibomas mimicking a splenic hydatid cyst and an ileal tumor. *J Gastrointest Surg* 2011; 15: 2101-2107. [\[CrossRef\]](#)
- Alis H, Soylu A, Dolay K, Kalayci M, Ciltas A. Surgical intervention may not always be required in gossypiboma with intramural migration. *World J Gastroenterol* 2007; 13: 6605-6607. [\[CrossRef\]](#)
- Wan W, Le T, Riskin L, Macario A. Improving safety in the operating room: a systematic literature review of retained surgical sponges. *Curr Opin Anaesthesiol* 2009; 22: 207-214. [\[CrossRef\]](#)
- Sümer A, Çarparlar MA, Uslukaya Ö, Bayrak V, Kotan Ç, Kemik O, et al. Gossypiboma: Retained Surgical Sponge After a Gynecologic Procedure. *Case Report Med* 2010; pii: 917626. [\[CrossRef\]](#)
- Duman AE, Ersoy O, Abbasoglu O, Harmanci O, Aydinli M, Bayraktar Y, et al. Misdiagnosis of a Gossypiboma as a Hydatid Cyst. *Indian J Gastroenterol* 2011; 30: 285. [\[CrossRef\]](#)
- Moslemi KM, Abedinzadeh M. Retained intraabdominal gossypiboma, five years after bilateral orchiopexy. *Case Report Med* 2010; 2010: 420357.
- Cattaneo F, Graffeo M, Brunetti E. Extrahepatic textiloma long misdiagnosed as calcified echinococcal cyst. *Case Rep Gastrointest Med* 2013; 2013: 261685. [\[CrossRef\]](#)
- Yagmur Y, Akbulut S, Gumus S. Post cholecystectomy gossypiboma mimicking a liver hydatid cyst: comprehensive literature review. *Iran Red Crescent Med J* 2015; 17: e22001. [\[CrossRef\]](#)
- Biava MF, Dao A, Fortier B. Laboratory diagnosis of cystic hydatid disease. *World J Surg* 2001; 25: 10-4. [\[CrossRef\]](#)