



Roux-en-Y fistulojejunostomy in the management of persistent external pancreatic fistula: is it olde worlde?

Gunjan Desai¹, Rajvilas Narkhede¹, Prasad Pande¹, Paresh Varty¹, Hitesh Mehta¹, Dattaprasanna Kulkarni¹

¹ Department of Surgical Gastroenterology, Lilavati Hospital and Research Centre, Mumbai, India

ABSTRACT

Objective: This article aimed to identify patient selection criteria and approach in treating persistent external pancreatic fistulas surgically with Roux-en-Y fistulojejunostomy, and the study evaluated the outcomes of Roux-en-Y fistulojejunostomy with a review of the relevant literature.

Material and Methods: A retrospective data analysis from January 2010 to May 2017 revealed 6 patients managed with Roux-en-Y fistulojejunostomy for persistent external pancreatic fistulas, and their details were entered in a proforma. Standard surgical steps were performed in all patients, and the patients were followed up postoperatively for 1 year. Data were analyzed for outcomes, and the literature was reviewed.

Results: Four of 6 patients had persistent external pancreatic fistulas following pancreatic necrosectomy, 1 had surgery for pancreatic pseudocyst, and 1 after pancreaticoduodenectomy for pancreatic head mass. An average duration of conservative management was 14 weeks, and Roux-en-Y fistulojejunostomy was performed at a median distance of 6 cm from pancreas via a midline laparotomy. All patients recovered without major complications. Only 1 patient developed diabetes at a 1-year follow-up.

Conclusion: Fistulojejunostomy is a safe and effective treatment for persistent pancreatic fistula having the benefit of avoiding a difficult major pancreatic resectional surgery in an already debilitated patient with frozen tissue planes, along with low postoperative morbidity and mortality. The short- and mid-term outcomes in the literature for this procedure are good, as it has also been seen in our study on diverse indications.

Keywords: Fistula, necrosectomy, pancreas, pancreaticoduodenectomy, surgery

INTRODUCTION

Pancreatic fistulas can result from surgery for various indications, including pancreatic necrosis, pancreatic pseudocysts, pancreatic masses (benign or malignant), chronic pancreatitis, trauma, or pancreatic ascites, and percutaneous interventions for fluid collections/pseudocysts (1-3).

Pancreatic fistulas, whether internal or external, can lead to locoregional complications such as abscess formation, hemorrhage, pseudoaneurysms, peritonitis, and sepsis (1,3). High mortality rates ranging between 13% and 36% have been reported. Initial conservative management is often successful in 90% of the patients without development of fever, tachycardia, leucocytosis, severe wound infection, or peritonitis (1,3,4). Clinical deterioration warrants a step-up approach, with total parenteral nutrition, optimal wound care, drainage of intra-abdominal collections via percutaneous drains, repositioning of previously placed drains, and occasionally, re-exploration with abdominal lavage. Prevention of wound complications, percutaneous dilatation of stenotic segments in anastomosis, and pancreatic duct stenting are all adjuncts for management.

The emergent surgical options include lavage with wide drainage, reinforcing or refashioning of anastomosis in case of a minor leak, disconnection of anastomosis with external pancreatic drainage in feeding jejunostomy, and rarely a total pancreatectomy, which leads to debilitating brittle diabetes and carries a prohibitively high mortality (5-7). Persistent external pancreatic fistula (PEPF) is defined as an external pancreatic fistula not resolving with these measures for longer than 6 weeks (1).

Cite this article as: Desai G, Narkhede R, Pande P, Varty P, Mehta H, Kulkarni D. Roux-en-Y fistulojejunostomy in the management of persistent external pancreatic fistula: is it olde worlde? Turk J Surg 2019; 35 (1): 62-69

Corresponding Author

Gunjan Desai

E-mail: dsashlsh@gmail.com

Received: 30.01.2018

Accepted: 03.04.2018

Available Online Date: 28.08.2018

© Copyright 2019 by Turkish Surgical Society Available online at www.turkjsurg.com

DOI: 10.5578/turkjsurg.4110

There are few surgical options to treat PEPF: internal drainage by Roux-en-Y fistulojejunostomy (RYFJ) or fistulogastrostomy, and pancreatic resection procedures are the available surgical options to treat PEPF not resolving with endoscopic, percutaneous, and combined endoscopic–percutaneous procedures (2).

Optimal time for performing fistulojejunostomy is a matter of debate (1,3). We present our algorithmic approach for the management of PEPF and our experience with RYFJ for this indication along with a brief review of the relevant literature.

MATERIAL and METHODS

A retrospective analysis of hospital records of the PEPF patients managed with RYFJ from January 2010 to May 2017 in the department of gastrointestinal surgery was carried out.

An institutional ethics committee approval was obtained, and patients were included into the study after providing a written informed consent. Data recorded in a dedicated proforma included patient demographics, etiology, details of conservative management, duration of conservative management, fistula output, investigations for complications and surgical planning, surgical indication and surgery details. A magnetic resonance cholangiopancreatography (Ingenia 3.0 T; Philips, Eindhoven, Netherlands) was done to evaluate the distal duct, the origin of the fistula tract, and confirm findings of disconnected duct syndrome. A contrast-enhanced computed tomography (Somatom definition flash; Siemens, Erlangen, Germany) was done for preoperative planning to evaluate the size of the tract and its wall thickness and rule out any associated intra-abdominal collections. Drain tube diameter, site of anastomosis, intraoperative blood loss, postoperative complications, and length of hospital stay were noted from inpatient hospital records.

At a formal laparotomy, a mature fistula tract was isolated by limited adhesiolysis to prevent devascularization of the tract, and it was dissected as close to the pancreas as possible, avoiding the immediate peri-pancreatic area (Figure 1).

The distance between the pancreas and the anastomotic site was measured. Single layer anastomosis was constructed to a 45-cm-long Roux loop of the jejunum using interrupted 4-0 polydioxanone sutures. A trans-anastomotic tube or stent was not used in any of the cases (Figures 2,3). Drains were placed at the end of the procedure. Intraoperative and postoperative complications were recorded from the inpatient case records.

Patients were followed in the outpatient department with clinical examination and ultrasonography of abdomen and pelvis. An algorithm for our approach to these patients is shown in Figure 4. The observations were tabulated, and the statistical data representation in the form of mean, median and range was done manually without any software.

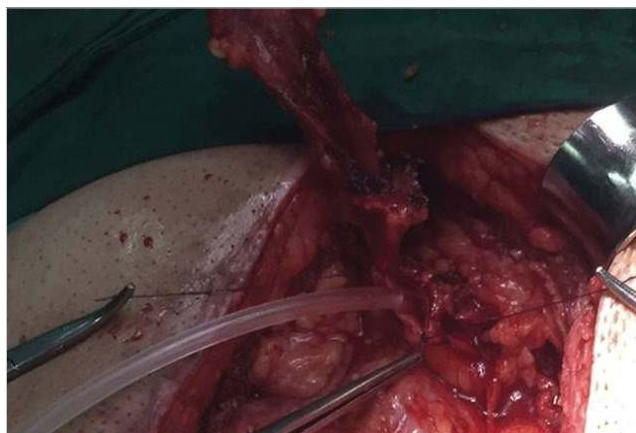

Figure 1. Intraoperative image showing the identification of the fistula tract along the abdominal drain.

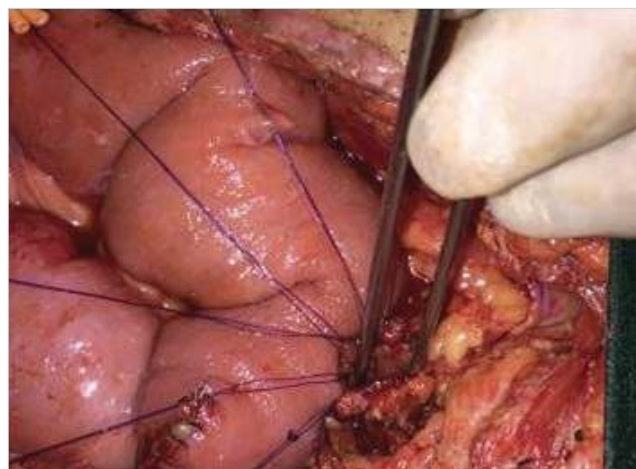


Figure 2. Intraoperative image showing the posterior layer sutures for Roux-en-Y fistulojejunostomy.

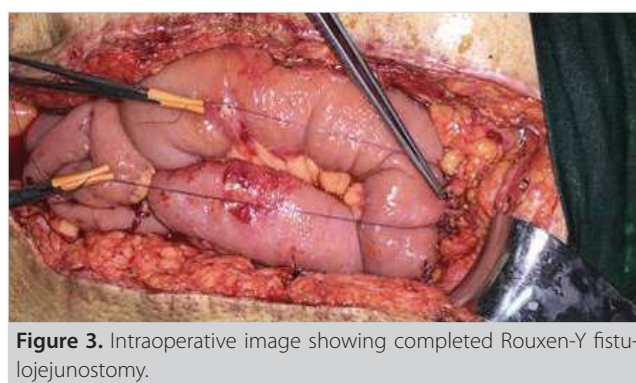
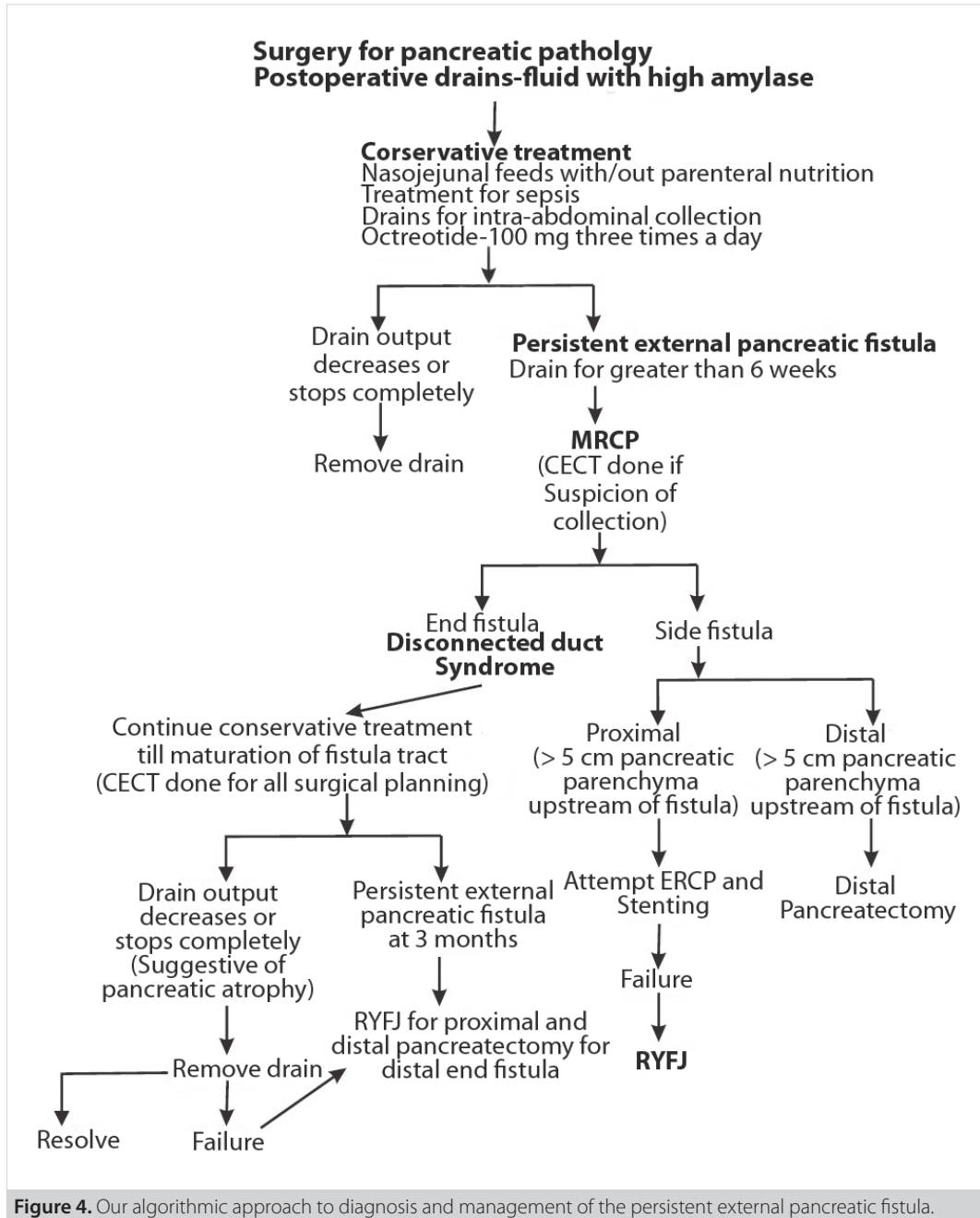


Figure 3. Intraoperative image showing completed Roux-en-Y fistulojejunostomy.



RESULTS

The details of each case are as follows.

Case 1

A 46-year-old man presented with obstructive jaundice due to a pseudocyst and a suspicious mass in the head of the pancreas (HOP), with a background of chronic pancreatitis. The patient underwent a pancreaticoduodenectomy (PD). He postoperatively developed a pancreatic fistula with an output of approximately 200-225 mL/day. He was managed conservatively with

enteral feeding by a nasojejunal tube. A percutaneous drain was placed for an intra-abdominal collection detected on CECT at 4 weeks postoperatively, and it was serially upgraded to 32 F. After 14 weeks of conservative management, the patient underwent RYFJ. The fistula tract was divided near the root of the mesocolon, approximately 4 cm from the pancreas, for anastomosis. The surgery lasted 150 minutes, and the blood loss was 100 mL. The patient recovered uneventfully and is doing well at a 60-month follow-up being on the pancreatic enzyme replacement therapy.

Case 2

A 48-year-old man was diagnosed with alcohol-induced acute pancreatitis, with walled-off pancreatic necrosis and splenic vein thrombosis. The patient underwent laparotomy with necrosectomy and splenectomy with a 32 F catheter drainage of the cavity, 6 weeks after the diagnosis. The patient postoperatively developed persistent pancreatic fistula with an output of 150-175 mL/day and was managed conservatively with nasojejunal tube feeding. After 12 weeks of conservative management, the patient underwent RYFJ. Anastomosis was supracolic infrahepatic, approximately 5 cm from the pancreas. The surgery lasted 160 minutes, and blood loss was 120 mL. The patient had a postoperative wound infection managed with dressings in the outpatient setting. The patient recovered without any major morbidity and is doing well on a 13-month follow-up, receiving diabetes therapy.

Case 3

A 52-year-old man was diagnosed with gall stone-induced severe acute pancreatitis with walled-off pancreatic necrosis and

underwent laparotomy with necrosectomy, 32 F catheter drainage of the cavity, and cholecystectomy 8 weeks after the diagnosis. The patient postoperatively developed a persistent pancreatic fistula with an output of approximately 50-75 mL/day and was managed conservatively with nasojejunal tube feeding. After 13 weeks of conservative management, the patient underwent RYFJ. The site of anastomosis was at the root of the mesocolon to the left of the middle colic vessels, at a distance of approximately 8 cm from the pancreas. The surgery lasted 200 minutes, and blood loss was 150 mL. The patient recovered uneventfully and is doing well at a 12-month follow-up.

Case 4

A 60-year-old man was diagnosed with alcohol-induced acute pancreatitis with walled-off pancreatic necrosis. The patient underwent percutaneous drainage of a necrotic collection at 3 weeks, followed 3 weeks later by a formal laparotomy with necrosectomy and the 30 F catheter drainage of the cavity. Having ostoperatively developed a persistent pancreatic fistula with an output of approximately 100-150 mL/day, the patient was man-

Table 1. Patient details, diagnosis, conservative measures, and duration of conservative measures in our series

Patient number	Patient 1	Patient 2	Patient 3	Patient 4	Patient 5	Patient 6
Age (years)	46	48	52	60	25	52
Sex	Male	Male	Male	Male	Male	Male
Primary pancreatic disease	Malignancy in chronic pancreatitis with pseudocyst in the pancreas head with obstructive jaundice	Alcohol-induced acute pancreatitis with walled-off pancreatic necrosis	Gall stone-induced severe acute pancreatitis with walled-off pancreatic necrosis	Alcohol-induced acute pancreatitis with walled-off pancreatic necrosis	Alcohol-induced acute pancreatitis with pseudocyst	Gall stone-induced acute severe necrotizing pancreatitis with infected walled-off pancreatic necrosis
Primary surgery	Whipple procedure	Open necrosectomy with splenectomy	Open necrosectomy and cholecystectomy	Open necrosectomy following a percutaneous drainage	Cystogastrostomy cystojejunostomy Hepaticojejunostomy (1 year later)	Laparoscopic transmesocolic necrosectomy
Splenic vein thrombosis	No	Yes	No	No	No	Yes
Conservative measures used before surgery	- Nasojejunal tube feeding - Catheter drainage of collection	- Nasojejunal tube feeding - Catheter drainage of the necrotic cavity	- Nasojejunal tube feeding and maintenance of drain of primary surgery	- Nasojejunal feeding - Catheter drainage of collection	- Percutaneous pseudocyst drainage (After 6 months) - Pancreatic duct stenting - Nasojejunal feeds	Nasojejunal tube feeding - Catheter drainage of collection - Laparoscopic lavage of intra-abdominal collections
Duration of conservative management	14 weeks	12 weeks	13 weeks	14 weeks	6 months	6 months
Fistula output (daily)	200-225mL	150-175mL	50-75mL	100-150mL	50-75mL	100-150 mL

Table 2. The table shows the drain tube diameter used, the approximate distance of the fistula anastomosis from the pancreas, intraoperative blood loss, postoperative complications, and the length of hospital stay in our patients

	Patient 1	Patient 2	Patient 3	Patient 4	Patient 5	Patient 6
Tube/drain diameter	32 F	32 F	32 F	30 F	18 F	32 F
Approximate distance from the pancreas	4 cm	5 cm	8 cm	4 cm	7 cm	4 cm
Site of anastomosis on the fistula	Left side near the root of mesocolon	Right-side infrahepatic area	Left side root of the mesocolon	Right side supracolic	Right side infrahepatic	Left-side root of the mesocolon
Intraoperative blood loss	100 mL	120 mL	150 mL	100 mL	180 mL	200 mL
Operative time	150 min	160 min	200 min	130 min	140 min	260 min
Length of stay	7 days	8 days	10 days	9 days	8 days	8 days
Complication	None	Wound infection	None	None	None	Wound infection
Follow-up duration	60 months	13 months	12 months	24 months	13 months	15 months
Follow-up method	Clinical evaluation and abdominal USG every 3 months					
PERT requirement	Yes	No	No	No	No	No
Postoperative leak/ Collections	No	No	No	No	No	No
Diabetes	No	Yes	No	No	No	No

F: French; cm: Centimeter; mL: Milliliters; min: Minutes; PERT: Pancreatic enzyme replacement therapy.

aged conservatively with nasojejunal tube feeding and needed a percutaneous catheter drainage of an undrained collection diagnosed on CECT 6 weeks after surgery. After 14 weeks of conservative management, the patient underwent RYFJ. The site of anastomosis was supracolic infrahepatic, at approximately 4 cm from the pancreas. The surgery lasted for 130 minutes, and blood loss was 100 mL. The patient recovered uneventfully and is doing well at a 24-month follow-up.

Case 5

A 25-year-old man was diagnosed with a pancreatic pseudocyst following alcohol-induced acute pancreatitis and underwent a cystogastrostomy. However, cyst drainage was not adequate, and cystogastrostomy was revised to a Roux-en-Y cystojejunostomy. A year later, the patient presented with obstructive jaundice for which he underwent hepaticojejunostomy. He again developed an infected pseudocyst, which was drained percutaneously with a 18 F catheter. The patient developed a pancreatic fistula with an output of approximately 50-75 mL/day and was managed conservatively with nasojejunal enteral feeding. After 12 weeks of conservative management, the patient underwent pancreatic duct stenting for his disconnected duct syndrome. However, the fistula persisted, and the patient was taken up for RYFJ, 6 months after the diagnosis of pancreatic fistula. The site of anastomosis was supracolic infrahepatic, at approximately 7 cm from the pancreas. The surgery lasted 140 minutes, and the blood loss was 180 mL. The patient recovered uneventfully and is doing well at a 13-month follow-up.

Case 6

A 52-year-old man was diagnosed with gall-stone-induced acute severe necrotizing pancreatitis with infected walled-off pancreatic necrosis for which he underwent laparoscopic transmesocolic necrosectomy, 32 F catheter drainage of the cavity, and cholecystectomy 6 weeks after the diagnosis. Having postoperatively developed a pancreatic fistula with an output of approximately 100-150 mL/day, the patient was managed conservatively with nasojejunal enteral feeding. The patient developed intraabdominal collection postoperatively at 4 weeks, which was managed with a percutaneous drainage followed by laparoscopic lavage. After 12 weeks of conservative management, the patient was diagnosed with disconnected duct syndrome, and conservative management was continued for 3 more months due to a decreasing drain output. Pancreatic duct stenting was attempted but was not successful in cannulating the disconnected duct, and he was finally planned for RYFJ. The site of anastomosis was at the root of the mesocolon to the left of the middle colic vessels, approximately 4 cm from the pancreas. The surgery lasted 260 minutes, and blood loss was 200 mL. The patient developed wound infection postoperatively, which was managed by dressings and antibiotics. He is doing well at a 15-month follow-up.

Thus, 6 male patients underwent RYFJ for PEPF during the study period. Patient details, indication of primary surgery and postoperative management, duration of fistula, and other conservative measures taken before surgery are summarized in Table

1. Median delay from the diagnosis of fistula to surgery was 14 weeks (range: 12 weeks to 6 months). The use of a 32 F drain in 5 out of 6 patients helped in the development of a mature fistula tract with an adequate diameter. Mean intra-operative blood loss was 140 mL (range: 100 mL to 200 mL). Intra-operative surgical details are as shown in Table 2. Median follow-up was 15 months (range: 12 months to 60 months). The patients with chronic pancreatitis required the pancreatic enzymes replacement therapy 2 years following the RYFJ surgery. None of the patients had residual or recurrent intra-abdominal collections.

DISCUSSION

External pancreatic fistulas have been classified as side fistulas and end fistulas. End fistulas include disconnected duct syndrome (DDS), which is the most common cause of PEPF. DDS, which can be partial or complete, is necrosis of a pancreatic duct segment along with a large segment full-thickness parenchymal necrosis leading to the disconnection of distal viable pancreas. Side fistulas have been further subdivided into post-operative and postinflammatory sequelae (1). The fistula may originate in the head, neck, body, or tail of the pancreas. Sometimes, the proximal pancreatic duct is strictured, preventing spontaneous fistula healing, which results in PEPF (4).

DDS can be managed by endoscopic sphincterotomy with a bridging stent placement across the discontinuity in the pancreatic duct. The management of complete DDS depends on the presence or absence of a significant fluid collection (> 2 cm), demonstrable duct disconnection, and presence or absence of an external drain. When these factors are present, endoscopic or endoscopic-ultrasound- (EUS) guided transmural drainage with/without stenting or percutaneous transfistulous distal pancreatic duct drainage or embolization with prolamine, ethylene-vinyl alcohol, fibrin sealant, or cyanoacrylate glue can be attempted with variable results. When the duct is not demonstrable, an outside-in (percutaneous) approach followed by an endoscopy- or EUS-guided transmural drainage is required (1,4,7).

These procedures need high technical expertise and are so far recommended for low-output [< 200 cc/day] fistulas with a short tract [< 2 cm]. The availability of expertise, stent blockage or migration, hemorrhage, post-procedure pancreatitis, and need for multiple interventions are some of the limitations (7).

Pancreatic surgeries (resection or drainage) for PEPF require difficult dissection in inflamed and friable tissues, which lead to an increased blood loss, longer operative times, and an extended hospital stay with higher treatment costs. Resection procedures have higher postoperative morbidity and mortality (1-3). DDS itself increases the incidence of diabetes mellitus development and metabolic and nutritional abnormalities due to a chronic protein loss and pancreatic enzymatic insufficiency.

Portal hypertension and its complications can be exacerbated after surgery. The first fistulojejunostomy for PEPF was performed by Lahey and Lium in 1937 (8). Ihse in 1994 treated the persistent pancreatic fistula using fistulogastrostomy (9). Bassi et al. have given the classical description of the standard technique (3). Over the years, RYFJ has also been suggested for the treatment of chronic external refractory biliary fistula and post-sleeve gastrectomy fistula, and it has been attempted laparoscopically.

Fistulojejunostomy is performed at our center based on principles put forward by Bassi et al., and it preserves the pancreatic parenchyma and function (3). Dissection in the lesser sac and difficult pancreatic re-surgery are avoided. Dissection is simpler and guided by the drainage tube, leading to shorter operating times, with less blood loss. As a result, associated costs and hospital stay are also reduced (3,6,9).

Vascularity of the fistula tract improves as we move closer to the pancreas, and chances of a delayed pseudocyst formation due to tract obliteration reduce as the length of the fistula tract reduces. Hence, anastomosis should be performed as close to the pancreas as possible. Bassi et al. question the notion of going very close to the pancreas (3). In their experience, the difference in outcomes with different distances from the pancreas is not significant (1-3,9).

Over subsequent years, variants of fistulojejunostomy have been described with similar outcomes and no demonstrable superiority of one technique over other (5,6,10).

Embedding fistulojejunostomy has been suggested by Luo et al., in which the fistula tract is disconnected from the abdominal wall and drained externally through a transluminal tube drain, with both the drain and the tract fixed to a Roux loop of the jejunum with seromuscular sutures (5). The drain is also fixed to the abdominal wall with absorbable sutures and removed after 30 days. It is an easy and safe technique with very limited entry into the abdominal wall, but drawbacks include a 1-month longer waiting period and the need of pancreatic enzyme supplementation as long as the drainage tube is present (6).

The binding fistulojejunostomy technique involves suturing a 2 cm length of fistula tract (with a tube drain) to an everted cut end of the Roux loop after carbolic acid ablation of the jejunal mucosa in the everted segment. The everted bowel is then wrapped over this anastomosis site with seromuscular sutures.

The drainage tube is brought out transjejunally and through the abdominal wall, and it is removed after a month (10). Subcutaneous fistulojejunostomy involves bringing out a Roux loop of jejunum in the subcutaneous plane followed by anastomosis in that area with the disconnected fistula tract.

The proponents of this technique suggest that there is necrosis or stenosis of the embedded or buried part of the fistula along

with the anastomotic segment. The technique requires minimal dissection of the tract, and the anti-gravity position ensures that there is no enteric contents entering the loop, minimizing the chances of leak (5).

The optimal time of performing fistulojejunostomy is still a matter of debate. Across various studies, timing ranges from 2 months to 1 year (1,5,6,9,10). Bassi et al. have recommended 6 to 12 weeks after identification of PEPF as the appropriate time (3). A delay allows adhesions to soften, inflammation to subside, and the tract wall to thicken and mature enough to allow a secure anastomosis. In the present study, the procedure was performed 12-14 weeks from the first identification of fistula in 4 cases and in 2 cases after 6 months. Fistulojejunostomy was successful in all of the 6 patients without any major complications in our series. The study has the limitations of being a single-center experience, and hence including a small number of patients.

CONCLUSION

Fistulojejunostomy is a safe and effective treatment plan for PEPF with benefits of avoiding a difficult major pancreatic resectional re-surgery in an already debilitated patient with frozen tissue planes. This procedure has a relatively low postoperative morbidity and mortality with good short- to mid-term outcomes.

Ethics Committee Approval: Ethics committee approval was received for this study from the Ethics Committee of Lilavati Hospital and research Centre.

Informed Consent: Written informed consent was obtained from all the patients who participated in this study.

Peer-review: Externally peer-reviewed.

Author Contributions: Concept - D.K., H.M., P.V.; Design - G.D., R.N., P.P.; Supervision - H.M., P.V., D.K.; Resource - R.N., P.P., G.D.; Materials - G.D., R.N., P.P.; Data Collection and/or Processing - P.V., D.K., H.M.; Analysis and/or Interpretation - D.K., H.M., P.V.; Literature Search - P.P., G.D., R.N.; Writing Manuscript - G.D., R.N., P.P.; Critical Reviews - D.K., H.M., P.V.

Conflict of Interest: The authors have no conflicts of interest to declare.

Financial Disclosure: The authors declared that this study has received no financial support.

REFERENCES

1. Nair R, Lowy A, McIntyre B, Sussman J, Matthews J, Ahmad S. *Fistulojejunostomy for the management of refractory pancreatic fistula. Surgery* 2007; 142: 636-42. [\[CrossRef\]](#)
2. Hirota M, Kanemitsu K, Takamori H, Chikamoto A, Hayashi N, Horino K, et al. *Percutaneous trans fistulous pancreatic duct drainage and interventional pancreatojejunostomy as a treatment option for intractable pancreatic fistula. Am J Surg* 2008; 196: 280-4. [\[CrossRef\]](#)
3. Bassi C, Butturini G, Salvia R, Contro C, Valerio A, Falconi M, et al. *A single-institution experience with fistulojejunostomy for external pancreatic fistulas. Am J Surg* 2000; 179: 203-6. [\[CrossRef\]](#)
4. Shibuya T, Shioya T, Kokuma M, Watanabe Y, Moriyama Y, Matsumoto K, et al. *Cure of intractable pancreatic fistula by subcutaneous fistulojejunostomy. J Gastroenterol* 2004; 39: 162-7. [\[CrossRef\]](#)
5. Luo S, Cheng S, Wu C, Huang C, Lin Y, Peng F. *Embedding fistulojejunostomy: An easy and secure technique for refractory external pancreatic fistula. Asian J Surg* 2018; 41: 143-7. [\[CrossRef\]](#)
6. Solanki R, Koganti SB, Bheerappa N, Sastry RA. *Disconnected duct syndrome: refractory inflammatory external pancreatic fistula following percutaneous drainage of an infected peripancreatic fluid collection. A case report and review of the literature. JOP* 2011; 12: 177-80.
7. Lahey FH, Lium R. *Cure of pancreatic fistula by pancreatojejunostomy. SurgGynecol Obstet* 1937; 64: 78-91.
8. Ihse I, Larsson J, Lindström E. *Surgical management of pure pancreatic fistulas. Hepatogastroenterology* 1994; 41: 271-5.
9. Varadarajulu S, Rana S, Bhasin D. *Endoscopic Therapy for Pancreatic Duct Leaks and Disruptions. Gastrointest Endosc Clin N Am* 2013; 23: 863-92. [\[CrossRef\]](#)
10. Zhao YF, Wu Y, Sun WR, Zhai WL, Zhang SJ. *Binding fistulojejunostomy for the treatment of external pancreatic fistula. Zhonghua Yi Xue Za Zhi* 2006; 86: 2721-2.



OLGU SERİSİ-ÖZET

Turk J Surg 2019; 35 (1): 62-69

Persistan eksternal pankreatik fistül tedavisinde Roux-en-Y fistülojejunostomi: Modası geçmiş bir yöntem mi?

Gunjan Desai¹, Rajvilas Narkhede¹, Prasad Pande¹, Paresh Varty¹, Hitesh Mehta¹, Dattaprasanna Kulkarni¹

¹ Litavati Hastanesi Araştırma Merkezi, Gastroenteroloji Cerrahi Bölümü, Mumbai, Hindistan

ÖZET

Giriş ve Amaç: Bu çalışmanın amacı, persistan eksternal pankreatik fistülün Roux-en-Y fistülojejunostomi ile cerrahi tedavisinde hasta seçimi ve yaklaşımın tespit edilmesi olmakla birlikte çalışma, ilgili literatürün gözden geçirilmesi ile Roux-en-Y fistülojejunostominin sonuçlarını da değerlendirmiştir.

Gereç ve Yöntem: Ocak 2010 tarihinden Mayıs 2017 tarihine kadar yürütülen retrospektif veri analizi persistan eksternal pankreatik fistül için altı hastanın Roux-en-Y fistülojejunostomi ile tedavi edildiğini ortaya koydu ve bu hastaların bilgileri bir proforma üzerine girildi. Bütün hastalarda standart cerrahi adımlar uygulandı ve hastalar postoperatif bir yıl boyunca takip edildi. Sonuçlar açısından veriler analiz edildi ve literatür tarandı.

Bulgular: Altı hastanın dördünde pankreatik nekrorektomiye takiben persistan eksternal pankreatik fistül vardı, bir hasta pankreatik psödokist için opere edildi ve bir diğeri de pankreatikoduodenektomi sonrası pankreas başında kitle sebebiyle opere edildi. Konservatif tedavinin ortalama süresi 14 haftaydı ve Roux-en-Y fistülojejunostomi orta hat laparotomi yoluyla pankreastan medyan 6 cm uzaklıkta yapıldı. Tüm hastalar majör komplikasyonlar geliştirmeden iyileşti. Sadece bir hastada, bir yıllık takip süresinde diabetes mellitus gelişti.

Sonuç: Fistülojejunostomi, persistan pankreatik fistül için zaten zayıflamış ve donmuş doku düzlemlerine sahip hastada zorlu majör pankreatik rezeksiyonel cerrahiden kaçınmaya yarayan güvenilir ve efektif bir tedavidir. Postoperatif morbidite ve mortalite oranı düşük olmakla birlikte bu prosedür için literatürde belirtilen kısa ve orta dönem sonuçlar iyidir ve bizim çeşitli endikasyonlara sahip bu çalışmamızda da bu sonuçlar görülmektedir.

Anahtar Kelimeler: Fistül, nekrorektomi, pankreas, pankreatikoduodenektomi, cerrahi

DOI: 10.5578/turkjsurg.4110