




# Gastrointestinal stromal tumors: A clinical and histopathological presentation of 27 cases

Doğan Gönüllü<sup>1</sup> , Okan Demiray<sup>1</sup> , Serkan İlgün<sup>1</sup> , Ufuk Mete Yıldız<sup>1</sup> , Mehmet Lari Gedik<sup>2</sup> , Muzaffer Er<sup>1</sup> , Ayşenur İğdem<sup>3</sup> , Elife Kimiloglu<sup>3</sup> , Ferda N. Köksoy<sup>1</sup> 

## ABSTRACT

**Objective:** Gastrointestinal stromal tumors (GISTs) are mesenchymal tumors that express type 3 tyrosine kinase receptors and are thought to develop from the neoplastic transformation of the interstitial Cajal cells. The present study was performed to morphologically and immunohistologically evaluate GISTs, to compare their qualities using a GIST risk categorization system, and to identify the diagnostic and prognostic parameters of GISTs.

**Material and Methods:** A total of 27 patients with GISTs underwent treatment and were followed up at the Gaziosmanpaşa Taksim Training and Research Hospital. Descriptive statistics was used to calculate the mean and median values. Survival analysis was performed by the Kaplan–Meier method. The analyses were performed using the SPSS version 22.0 software.

**Results:** The mean follow-up time was 3.5 (5 months to 13 years) years. The mean age was 60.4 (29–82) years. The tumors were localized in the stomach (62.9%), extraintestinal areas (14.8%), intestine (7.4%), esophagus (7.4%), and rectum (7.4%). Twenty-four patients were classified according to the Fletcher system. Of these patients, 7 (25.9%) were classified as very low risk, 8 (29.6%) as low risk, 7 (25.9%) as intermediate risk, and 2 (7.4%) as high risk. Twenty-four patients underwent surgery. Of the 3 patients who did not undergo surgery, 1 had metastatic disease at the time of diagnosis, and 2 had mini- or micro-GISTs in the stomach. On endoscopic surveillance, all tumors remained stable. Three out of the 27 patients were lost to follow-up. Two patients developed recurrence, and 1 patient died of GIST.

**Conclusion:** We analyzed the clinical and pathological characteristics of GIST. The most common site of tumor origin was the stomach. The size, mitotic index, and Ki-67 values were to be found high in intermediate- and high-risk groups and metastatic diseases.

**Keywords:** Gastrointestinal stromal tumor, interstitial Cajal cells, mesenchymal tumors, tyrosine kinase receptor mutation

## ORCID IDs of the authors:

D.G. 0000-0002-8232-5209;  
O.D. 0000-0001-6920-7585;  
S.İ. 0000-0002-4862-2891;  
U.M.Y. 0000-0002-4482-0225;  
M.L.G. 0000-0002-0440-9394;  
M.E. 0000-0001-8578-1229;  
A.İ. 0000-0002-3047-1546;  
E.K. 0000-0002-2708-1272;  
F.N.K. 0000-0002-5878-7489.

## Cite this paper as:

Gönüllü D, Demiray O, İlgün S, Yıldız UM, Gedik ML, Er M, et al. Gastrointestinal stromal tumors: A clinical and histopathological presentation of 27 cases. Turk J Surg 2018; 34(4): 259-263.

<sup>1</sup>Department of General Surgery, University of Health Sciences, Gaziosmanpaşa Taksim Training and Research Hospital, Istanbul, Turkey

<sup>2</sup>Department of General Surgery, Ministry of Health, Fatsa State Hospital, Ordu, Turkey

<sup>3</sup>Department of Pathology, University of Health Sciences, Gaziosmanpaşa Taksim Training and Research Hospital, Istanbul, Turkey

This study was presented at the 36<sup>th</sup> Congress of the European Society of Surgical Oncology, 14-16 September 2016, Krakow, Poland.

## Corresponding Author

Doğan Gönüllü

e-mail: dogangonullu@yahoo.com

Received: 08.11.2017

Accepted: 07.02.2018

Available Online Date: 11.09.2018

©Copyright 2018  
by Turkish Surgical Association  
Available online at  
turkjsurg.com

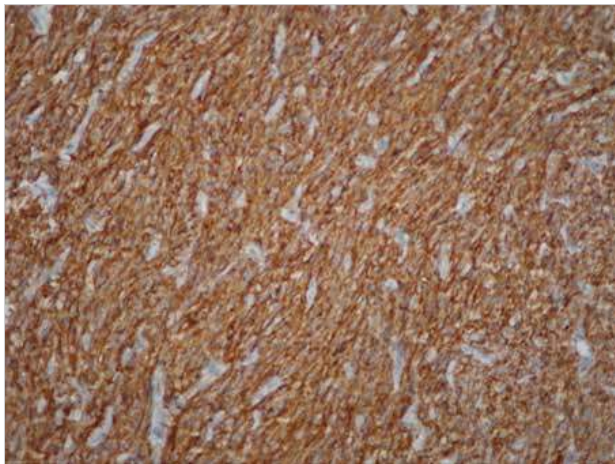
## INTRODUCTION

Gastrointestinal stromal tumors (GISTs) are mesenchymal tumors that express type 3 tyrosine kinase receptors and are thought to develop from the neoplastic transformation of the interstitial Cajal cells (intestinal pacemaker cells on the intestinal wall) or their precursors (1-3). Mutation of the tyrosine kinase receptor (c-Kit/CD117) in precursor tumors causes uncontrolled growth. Approximately 95% of sporadic GISTs are positive for CD117, 60% to 70% positive for CD34, and 30% to 40% positive for smooth muscle actin, whereas negative for S100 protein and desmin (3, 4). KIT gene mutation is specific to gastric stromal tumors in the intramembranous component of the tyrosine kinase receptor (exon 11) and in the extramembranous component (exon 9) as well as to tumors located in the intestines and colon, which reportedly have a worse prognosis (3, 5-7). Patients with exon 11 mutation (63.0%–83.5%) have been shown to have better responses to imatinib (Gleevec; Novartis Pharma AG, Basel, Switzerland) than patients with exon 9 mutation (34.0%–47.8%) (3, 8, 9). In patients without KIT mutation, platelet-derived growth factor receptor- $\alpha$  (PDGFR $\alpha$ ) mutation should be considered, and these types of stromal tumors frequently have epithelioid qualities (5, 10). GISTs positive for both KIT and PDGFR $\alpha$  mutations have not been reported; however, tumors that are negative for both markers reportedly constitute approximately 10% of all GISTs and are predominantly located in the stomach (2, 5, 9). A highly specific marker, DOG1 (discovered on GIST-1), has been started to be used for c-Kit-negative stromal tumors (2).

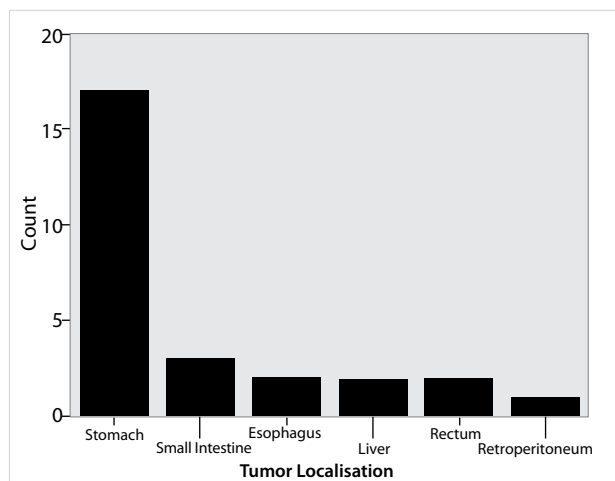
The purpose of the present study was to morphologically and immunohistochemically evaluate GISTs, to compare their qualities using the GIST risk categorization table established by Fletcher et al. (11), and to determine the important parameters for the diagnosis and prognosis of GISTs.

## MATERIAL AND METHODS

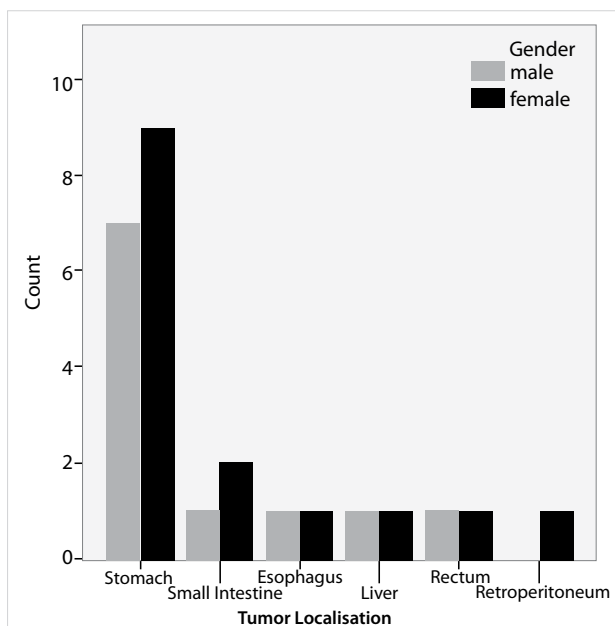
In total, 27 patients with GISTs underwent surgical treatment and were followed up at the Gaziosmanpaşa Taksim Training and Research Hospital from 2002 to 2016. The study was conducted in accordance with the ethical standards set by the Declaration of Helsinki. Informed consent was obtained from all individual



**Figure 1.** CD117 staining of a gastrointestinal stromal tumor (×200 magnification)



**Figure 2.** Locations of gastrointestinal stromal tumors



**Figure 3.** Risk groups according to the Fletcher classification

participants included in the study. Hematoxylin and eosin staining and immunohistochemical markers, such as c-Kit, CD34, and Ki-67, were used to diagnose GISTs (Figure 1). Risk groups and other prognostic parameters were reported (Figure 1). On clinical

presentation, the median follow-up time was 3.5 (5 months to 13 years) years. Patients in the high-risk group were monitored using an abdominal ultrasonography and a computed tomography every 3 to 6 months for the first 3 years and every 6 months for the following 5 years. Descriptive statistics was used to calculate the mean and median values. Survival analysis was performed by the Kaplan–Meier method. The analyses were performed using the Statistical Package for the Social Sciences (SPSS) version 22.0 software (IBM Corp., Armonk, NY, USA).

## RESULTS

The female-to-male ratio was 5:4. The mean age was 60.4 (29–82) years. Five tumors were incidentally diagnosed in patients undergoing surgery for other reasons, such as gastric cancer, sigmoid volvulus cancer, colon cancer, renal cancer, and ovarian cancer. Seventeen (62.9%) tumors were localized in the stomach, 4 (14.8%) in the extraintestinal areas (2 in the mesentery and 2 in the liver), 2 (7.4%) in the intestine, 2 (7.4%) in the esophagus, and 2 (7.4%) in the rectum (Figure 2). Twenty-four patients were classified according to the Fletcher system (3 patients were classified as stage 4). Of all 27 patients, 7 (25.9%) were classified as very low risk, 8 (29.6%) as low risk, 7 (25.9%) as intermediate risk, and 2 (7.4%) as high risk (Figure 3).

The mean Ki-67 of the patients with stage 4 cancer was 15.6 (7–25), whereas it was 9.6 (2–25) for both intermediate and high-risk patients. The Ki-67 level was >7% in all patients with metastatic GISTs but in only 6 (54%) of the intermediate and high-risk patients. The Ki-67 staining ratio was <1% for 7 (25.9%) patients, 2%–7% for 13 (48.1%) patients, and >7% for 7 (25.9%) patients. Staining was not observed in >7% of the tumors located in the esophagus; however, staining >7% was observed in only 1 patient among those with intestinal tumors (Figure 4).

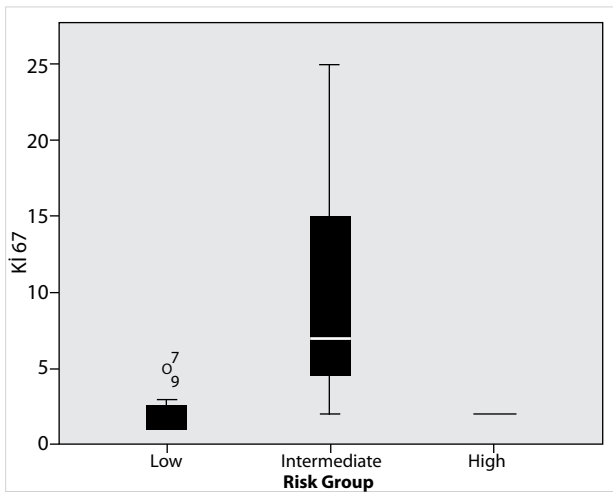
The mean tumor diameter was 5.45 (0.5–18) cm, and the largest tumors were observed among those with an extraintestinal localization (average tumor diameter: 13.2 (8–18) cm) (Figure 5). Seven tumors were <2 cm, 3 were classified as micro-GISTs (<1 cm), and 4 were classified as mini-GISTs (1–2 cm).

Fifteen (55.5%) tumors were spindle cell tumors, 7 (25.9%) were epithelioid tumors, and 5 (18.5%) were mixed form tumors (Figure 6). Nine of the 17 GISTs located in the stomach were spindle cell tumors. All esophageal tumors were epithelioid tumors, and tumors localized in the colon or extraintestinal regions were either spindle cell tumors (75%) or epithelioid tumors (25%).

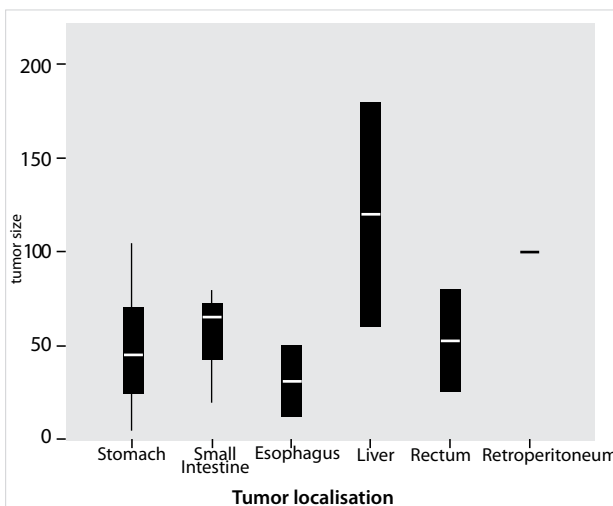
Three out of the 27 patients were lost to follow-up. Two patients developed recurrent disease, and one died of GIST. The 5-year survival rate was 89.3% (Figure 7). Twenty-four (88.8%) patients underwent surgery. Of the 3 patients who did not undergo surgery, 1 had metastatic disease at the time of diagnosis, and 2 had a mini- or micro-GIST localized in the stomach. On endoscopic surveillance, the tumors remained stable. All patients with high-risk disease and metastatic disease underwent imatinib treatment.

## DISCUSSION

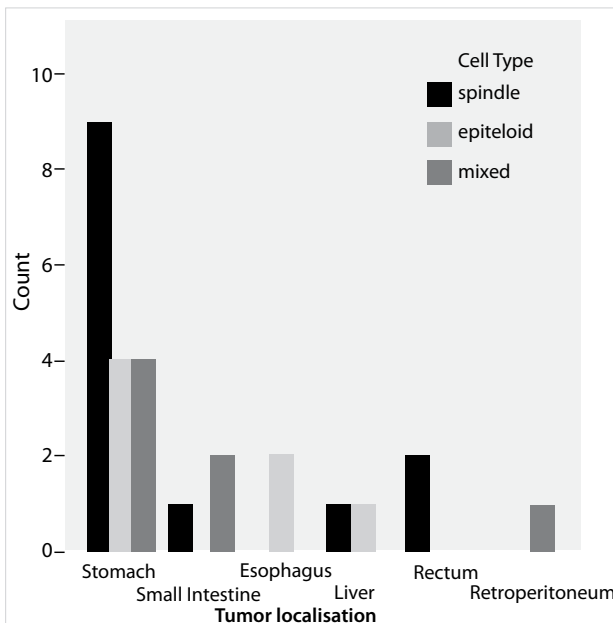
Gastrointestinal stromal tumors are rare and constitute <1% of the primary tumors of the gastrointestinal system, 2.2% of the stomach tumors, 13.9% of the intestinal tumors, and 0.1% of the colorectal tumors (12). GISTs are most frequently located in the stomach (50%–60%), intestine (20%–30%), colon and rec-



**Figure 4.** Correlations between Ki-67 index and risk group

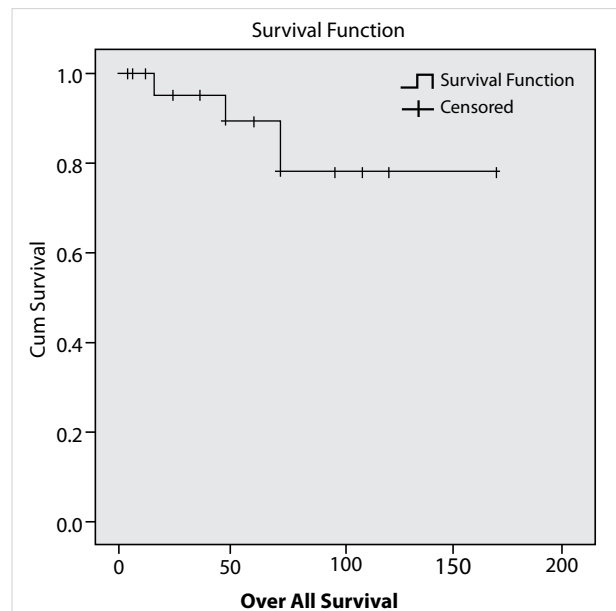


**Figure 5.** The mean size of gastrointestinal stromal tumors



**Figure 6.** Histological types of gastrointestinal stromal tumors

tum (10%), and esophagus (5%). They are rarely located in the extraintestinal regions, such as the mesentery, omentum, and retroperitoneum (5%) (13). GISTs in the bladder and gallblad-



**Figure 7.** The 5-year survival rate

der have only been described in case reports (14). Consistent with the literature, most GISTs in our series were localized in the stomach (62%), yet our high ratio of extraintestinal GISTs (14.8%, 4 liver and retroperitoneal tumors) is a different finding.

Gastrointestinal stromal tumors are equally observed in both sexes. They are more frequent between aged 50 and 70 years. However, the development of GISTs in pediatric patients has also been reported (9). The incidence of GISTs in a Swedish study was 13 per million (15). In other studies, the annual incidence in North America was 3.2 to 7.0 per million, whereas that in Hong Kong was 15 to 20 per million (2). Most GISTs (80%) are found incidentally; only a small ratio is observed as a component of a familial disease (e.g., neurofibromatosis type 1 and Carney complex) (9).

Gastrointestinal stromal tumors were historically classified as soft tissue sarcomas (e.g., leiomyosarcoma, leiomyoma, and leiomyoblastoma) owing to their CD34 staining, but the c-Kit mutation was demonstrated in 1990, after which the term "GIST" began to be used more frequently as a tumor group separate from leiomyosarcoma, schwannoma, and neurofibroma, all of which are c-Kit-negative (4). The Armed Forces Institute for Pathology reviewed 1765 patients who were diagnosed with smooth muscle tumors from 1979 to 1996 and classified 94% of them as GISTs (2, 3).

Histologically, GISTs are classified as spindle cell tumors (70%), epithelioid cell tumors (20%), and mixed-type tumors, which are rarely observed. Spindle cell tumors are large in volume, most frequently localized in the stomach and intestines, exhibit KIT and PDGFRα mutations, and respond well to treatment with imatinib mesylate. In contrast, the epithelioid subtype is less frequently observed, does not exhibit KIT and PDGFRα mutations, and co-occurs with lymph node metastases. Spindle cell tumors were observed in 55.5% (n=15) of the patients, epithelioid in 25.9% (n=7) of the patients, and mixed in 18.5% (n=5) of the patients in the present study. Nine of the 17 GISTs were spindle cell tumors, whereas all esophageal tumors were epithelioid. Of those located in the colon or extraintestinally,

75% were spindle cell tumors, and 25% were epithelioid tumors. In contrast to previous studies, mixed tumors had larger volumes in the present study (average diameter: 6.8 cm). c-Kit and CD34 were positive in 86.6% of the spindle cell tumors, and CD34 was negative in 2 tumors. Additionally, 54.1% of the epithelioid tumors were positive for both c-Kit and CD34. One case was c-Kit-negative, and the other case was CD34-negative. Among the mixed tumors, c-Kit/CD34 staining was positive in 80% of the cases, whereas 1 tumor was CD34-negative.

The prognosis and prognostic factors of GISTs have long been the subject of debates. Many parameters have been discussed, but four risk groups were recently accepted based on the tumor size and mitotic index (11). In addition to these two parameters, mucosal invasion, presence of tumor necrosis, increased cellularity, and immunohistochemical markers of cell proliferation (Ki-67, MIB-1, PCNA, and DOG) have been considered as other potentially effective factors in the evaluation of malignancy risk.

The Ki-67 proliferative index is not included among the accepted prognostic factors, yet many studies (15, 16) have revealed that it is more valuable than the mitotic index. Nilsson et al. (16) found that in patients with a Ki-67 index >7, GIST recurrence is observed in 63%, and 47% die of this tumor. On the other hand, in patients with a Ki-67 index <7, the recurrence rate was only 4%, and only 1% died of the tumor. Zhao et al. (15) suggested that patients with a Ki-67 index >8 respond less to treatment with tyrosine kinase inhibitors. In our series, the Ki-67 index was >7% in 7 patients who were classified as low risk (n=1), intermediate risk (n=3), high risk (n=1), and phase 4 (n=2) based on the Fletcher stratification.

Extraintestinal GISTs develop from multipotent stem cells, which are the precursors of the interstitial Cajal cells. Immunohistochemical studies have shown that they are CD117-positive, and according to a previous study, they constitute 10% of all GISTs (17). In the 2012 San Francisco Gastrointestinal Cancers Symposium, Guye et al. (18) reported that based on the Surveillance, Epidemiology and End-Results records, 261 out of the 2951 patients who underwent surgery from 1996 to 2008 had extraintestinal GISTs with a higher average diameter and were in advanced stages. The 5-year survival rate was 32% for extraintestinal GISTs and 49% for GISTs (18). Their report suggested that extraintestinal localization is an independent factor for a poor prognosis. In our series, 4 patients had extraintestinal tumors, 3 had spindle cell tumors, and 1 had an epithelioid stromal tumor. All cases were CD34- and CD117-positive, with an average diameter of 13.2 (8–18) cm. Two had necrosis, and the Ki-67 ratio was 14.8% (2%–25%). Two were localized in the liver (one was intermediate risk and the other was stage 4 with lung and adrenal metastases). Three were localized in the retroperitoneum or mesentery (intermediate and high risk). Recurrence was observed after 1 year in 1 patient with an intermediate-risk tumor. These patients were followed up for an average of 4 (1–6) years, and all were alive at the time of the present study.

Although GISTs reach a larger volume than other gastrointestinal tumors with adenocarcinoma qualities, they do not lead to lymphatic metastasis, making surgical procedures easier and the prognosis more favorable (8). Their biological behavior varies; only 10% to 30% of all GISTs progress to malignancy (13). There is still a lack of consensus on prognostic factors, but the risk clas-

sification described by Fletcher et al. (11) is an accepted guideline (18). Tumors displaying malignant behaviors are assessed by tumor size and the mitotic index per 50 high power field (HPF). When the tumor diameter alone is evaluated, a diameter <5 cm generally indicates a good prognosis, whereas a diameter >5 cm signifies a malignant prognosis. A mitotic index >5/50 HPF suggests malignancy. However, these parameters have been shown to vary according to localization, and Miettinen et al. (19) of the Armed Forces Institute of Pathology added the GIST localization to the parameters indicated by Fletcher et al. (11). In our series, the use of the Fletcher classification revealed that 25.9% (7/27) of the cases were very low risk, 29.0% (8/27) were low risk, 25.9% (7/27) were intermediate risk, and 7.4% (2/27) were high risk.

The Memorial Sloan-Kettering Cancer Clinic has developed prognostic nomograms for calculating the 2-year and 5-year recurrence-free rates by evaluating the tumor diameter, mitotic index, and localization findings (2, 3).

The fundamental treatment method for most GISTs is surgical resection with clear surgical margins. The extreme fragility of the tumor requires special attention to prevent its rupture (8, 13) during the procedure with resultant intra-abdominal seeding. If the tumor ruptures, and if there is no indication for the tyrosine kinase inhibitor imatinib, then it should be noted as an epicrisis and brought to the oncologist's attention; such cases are considered for imatinib treatment regardless of the Fletcher classification (8). Since the possibility of lymphatic metastasis is low in patients with sporadic GISTs (8, 13), lymphadenectomy is not necessary (2, 8, 13, 20, 21). However, case reports have indicated that the rate of lymph node metastasis is higher in pediatric patients with GISTs that are c-Kit- and PDGFR $\alpha$ -negative, multifocal, or familial (22–24).

Laparoscopic procedures are not recommended for especially large tumors (8). Radiotherapy is ineffective (9). After surgical treatment, recurrence is observed mostly in the peritoneum (50%), liver (65%), or both (13). A review of the previous study suggests that omental tumors recur frequently, and this may be due to rupture and unseen implants. De Matteo et al. (25) reported that among their patients who underwent R0 resection, 35% have local recurrence, and 44% had local recurrence with liver metastases. The tumor diameter is more important than the surgical margin negativity for local recurrence according to their results. We observed recurrence in 2 of the patients. In the first patient, a Fletcher low-risk epithelioid tumor in the stomach fundus was treated by proximal gastrectomy, and recurrence developed at the resection line 4 years later despite the fact that the surgical margin was negative. In the second patient who was determined to have a retroperitoneal spindle cell tumor with intermediate risk, recurrence developed 1 year later and displayed high-risk tumor qualities. Interestingly, two neuroendocrine tumors, each with a diameter of 1 cm, were incidentally detected in the intestine of the second patient.

The 5-year overall survival rate was 63% for patients with low-risk tumors (<5 cm) and 34% for those with high-risk tumors (>10 cm) in the present study (26).

Patients with high-risk tumors (>5 mitoses/50 HPF, tumor diameter >5 cm, tumor rupture during surgery, or R1-type resection and exon 11 mutation) are considered for adjuvant treat-

ment (8). In the present series, 5 out of the 27 patients had high-risk stage 4 GISTs according to the Fletcher classification and received imatinib treatment.

We were able to surgically treat 88.8% (24/27) of the patients, and the 5-year survival rate was 89.3%. Most of the tumors were resectable at the point of diagnosis. Most of the tumors (62.9%) were located in the stomach, and 81.4% (22/27) of the patients were classified as very low, low, or intermediate risk based on the Fletcher criteria. All of these factors can explain the high survival rate. De Matteo et al. (25) reported a 54% survival rate and 45% 5-year remission rate following radical surgery (R0).

## CONCLUSION

We analyzed the clinical and pathological characteristics of GIST admitted and treated during the past 13 years. The most common site of tumor origin was the stomach. The size, mitotic index, and Ki-67 values were found to be high in intermediate- and high-risk groups and metastatic diseases.

**Ethics Committee Approval:** Authors declared that the research was conducted according to the principles of the World Medical Association Declaration of Helsinki "Ethical Principles for Medical Research Involving Human Subjects" (amended in October 2013).

**Informed Consent:** Written informed consent was obtained from patients who participated in this study.

**Peer-review:** Externally peer-reviewed.

**Author Contributions:** Concept - D.G., O.D., S.I.; Design - D.G., O.D., A.I., E.K.; Supervision - M.E., F.N.K., M.L.G.; Resource - D.G., O.D., E.K.; Materials - D.G., A.I., E.K., M.L.G.; Data Collection and/or Processing - F.N.K., S.I., M.L.G., O.D.; Analysis and/or Interpretation - D.G., F.N.K., S.I.; Literature Search D.G., O.D., F.N.K., A.I.; Writing Manuscript - D.G., O.D., S.I.; Critical Reviews - M.E., A.I., E.K.

**Conflict of Interest:** The authors have no conflicts of interest to declare.

**Financial Disclosure:** The authors declared that this study has received no financial support.

## REFERENCES

- Pidhorecky I, Chency RT, Kraybill WG, Gibbs JF. Gastrointestinal stromal tumors: current diagnosis, biologic behavior, and management. *Ann Surg Oncol* 2000; 7: 705-712. [CrossRef]
- Valsangkar N, Sehdev A, Misra S, Zimmers TA, O'Neil BH, Koniaris LG. Current management of gastrointestinal stromal tumors: Surgery, current biomarkers, mutations, and therapy. *Surgery* 2015; 158: 1149-1164. [CrossRef]
- Lai EC, Lau SH, Lau WY. Current management of gastrointestinal stromal tumors-A comprehensive review. *Int J Surg* 2012; 10: 334-340. [CrossRef]
- Fletcher CD, Berman JJ, Corless C, Gorstein F, Lasota J, Longley BJ, et al. Diagnosis of Gastrointestinal Stromal Tumors: A consensus Approach. *Human Pathology* 2002; 33: 459-465. [CrossRef]
- Neeta Somaiah. Gastrointestinal stromal tumors: optimizing therapy throughout the course of disease. Available from URL: [www.clinicaloptions.com/oncology](http://www.clinicaloptions.com/oncology). 2015
- Lasota J, Corless CL, Heinrich MC, Debiec-Rychter M, Sciot R, Wardelmann E, et al. Maria Debiec-Rychter, Sciot R, Eva W. Clinicopathologic profile of gastrointestinal stromal tumors (GISTs) with primary KIT exon 13 or exon 17 mutations: a multicenter study on 54 cases. *Mod Pathol* 2008; 21: 476-484. [CrossRef]
- Taniguchi M, Nishida T, Hirota S, Isozaki K, Ito T, Nomura T, et al. Effect of c-kit Mutation on Prognosis of Gastrointestinal Stromal Tumors. *Cancer Res* 1999; 59: 4297-4300.
- Anna Nasierowska-Guttmejer. Gastrointestinal stromal tumors. In Rutkowski P, ed. *Soft Tissue Sarcomas*. Copyright Via Media: 2016, p: 126-52.
- Gabriella A. Expression profiling of gastrointestinal stromal tumors biomarkers for prognosis and therapy (MSD Thesis). University of Gothenburg; 2012.
- Local treatment for gastrointestinal stromal tumors. Available from URL: [www.up.to.date.com](http://www.up.to.date.com)
- Fletcher CD, Berman JJ, Corless C, Gorstein F, Lasota J, Longley BJ, et al. Diagnosis of gastrointestinal stromal tumors: a consensus approach. *Int J Surg Pathol* 2002; 10: 81-89. [CrossRef]
- Thomas RM, Sobin LH. Gastrointestinal cancer incidence and prognosis by histologic type, SEER population based data 1973-1983. *Cancer* 1995; 75: 154-170. [CrossRef]
- Michael S, Emmanouel D, Charikleia S, Panagiotis S, Electra P, Georgia L, Michael S. Gastrointestinal stromal tumor. *W J of Surg Oncol* 2009; 7: 61. [CrossRef]
- Ortiz-Hidalgo C, de Leon Bojorge B, Albores Saavedra J. Stromal tumor of the gallbladder with phenotype of interstitial cells of Cajal. A previous unrecognized neoplasm. *Am J Surg Pathol* 2000; 24: 1420-1423. [CrossRef]
- Zhao WY, Xu J, Wang M, Zhang ZZ, Tu L, Wang CJ, et al. Prognostic value of Ki 67 index in gastrointestinal stromal tumors. *Int J Clin Exp Pathol* 2014; 7: 2298-2304.
- Nilsson B, Bümming P, Meis-Kindblom JM, Oden A, Dortok A, Gustavsson B, et al. Gastrointestinal stromal tumors :the incidence, prevalence, clinical course, and prognostication in the preimatinibmesylat era, a population based study in western Sweden. *Cancer* 2005; 15: 103; 821-829. [CrossRef]
- Xiao-Li Luo, Dan Liu, Jian-Jun Yang, Min-Wen Zheng, Jing Zhang, Xiao-Dong Zhou. Primary gastrointestinal stromal tumor of the liver: A case report. *World J Gastroenterol* 2009; 7; 15: 3704-3707. [CrossRef]
- Guye ML. Extraintestinal location for primary non-metastatic GIST associated with increased risk for death. 2012 Gastrointestinal Cancers Symposium. San Francisco.
- Miettinen M, Leslie H. Sobin, Maarit Sarlomo-Rikala. Immunohistochemical Spectrum of GISTs at Different Sites and Their Differential Diagnosis with a Reference to CD117 (KIT). *Mod Pathol* 2000; 13: 1134-1142. [CrossRef]
- Fletcher CD. Risk aggressive behavior in GIST's. *Human Pathology* 2002; 33: 459-65. [CrossRef]
- D'Amato G, Steinert DM, McAuliffe JC, Trent JC. Update on biology and therapy of gastrointestinal stromal tumours. *Cancer Control* 2005; 12: 44-56. [CrossRef]
- Shafizad A, Mohammadianpanah M, Nasrolahi H, Mokhtari M, Mousavi SA. Lymph Node Metastasis in Gastrointestinal Stromal Tumor (GIST): to Report a Case. *Iranian J of Cancer Prevention* 2014; 7: 171-175.
- Otto C, Agaimy A, Braun A, Räddecke J, Hoepfner J, Illerhaus G, et al. Multifocal gastric gastrointestinal stromal tumors (GISTs) with lymph node metastases in children and young adults: A comparative clinical and histomorphological study of three cases including a new case of Carney triad. *Diagn Pathol* 2011; 6: 52. [CrossRef]
- Agaimy A, Wünsch PH. Lymph node metastasis in gastrointestinal stromal tumours (GIST) occurs preferentially in young patients <math>\leq 40</math> years: An overview based on our case material and the literature. *Langenbecks Arch Surg* 2009; 394: 375-381. [CrossRef]
- DeMatteo RP, Lewis JJ, Leung D, Mudan SS, James M W, Brennan MF. Two Hundred Gastrointestinal Stromal Tumors Recurrence Patterns and Prognostic Factors for Survival. *Ann Surg* 2000; 231: 51-58. [CrossRef]
- Besana-Ciani I, Boni L, Dionigi G, Benevento A, Dionigi R. Outcome and long term results of surgical resection for gastrointestinal stromal tumors (GIST). *Scand J Surg* 2003; 92: 195-199. [CrossRef]