



Adult morgagni hernia: A single-center experience of five cases and a review of literature

Cihan Ağalar¹ , Koray Atıla¹ , Naciye Çiğdem Arslan² , Zekai Serhan Derici¹ , Seymen Bora¹

ABSTRACT

Morgagni hernia is a rare congenital anomaly arising from the fusion defect between the septum transversum and sternum. The diagnosis is usually difficult since the presentation may be asymptomatic or with respiratory symptoms, abdominal and/or retrosternal pain, abdominal fullness, or gastrointestinal obstruction. In this report, we discuss the clinical presentation and management of this rare condition in five consecutive cases. Between 2009 and 2015, five cases underwent surgery for Morgagni hernia (three laparoscopic and two open repair surgeries); one patient developed recurrent hernia 7 months after the laparoscopic surgery. This case is the first reported recurrence in literature following laparoscopic repair in adults. Surgery is the only treatment option for Morgagni hernias, which can be performed through transthoracic, transabdominal, laparoscopic, or thoracoscopic approach. The issues of using mesh and reducing the hernial sac remain controversial.

Keywords: Diaphragmatic hernia, laparoscopic repair, morgagni hernia

ORCID IDs of the authors:

C.A. 0000-0002-9848-0326;
K.A. 0000-0001-9628-5300;
N.Ç.A. 0000-0002-2282-7207;
Z.S.D. 0000-0002-2828-1452;
S.B. 0000-0002-6725-5169..

Cite this paper as:

Ağalar C, Atıla K, Arslan NÇ, Derici ZS, Bora S. Adult morgagni hernia: A single-center experience of five cases and a review of literature. Turk J Surg 2018; 10.5152/turkjsurg.2018.3929.

¹Department of General Surgery, Dokuz Eylül University School of Medicine, İzmir, Turkey

²Department of General Surgery, İstinye University School of Medicine, İstanbul, Turkey

This study was presented at the "19th National Surgery Congress", "16-20 April 2014", "Antalya, Turkey".

Corresponding Author

Cihan Ağalar

e-mail: cihanagalar@hotmail.com

Received: 22.06.2017

Accepted: 09.08.2017

Available Online Date: 11.09.2018

©Copyright 2018
by Turkish Surgical Association
Available online at
www.turkjsurg.com

INTRODUCTION

Morgagni hernia was first described by an Italian anatomist and pathologist Giovanni Morgagni in 1769 (1-2). This para-retrosternal defect between the septum transversum and sternum is called the foramen of Larrey or the foramen of Morgagni (1). Its incidence is 1/2000-5000, accounting for 3%-4% of all congenital diaphragmatic hernias (3). The abdominal organs herniate to the thorax through a retrosternal diaphragmatic defect from the right side in 90% of the cases. The pericardium is considered responsible for the decreased incidence of the left-sided Morgagni hernia, but bilateral cases are rarely reported (4). Increased intra-abdominal pressure has been considered to be associated with Morgagni hernia, particularly in the adults. Chest radiography and thorax computed tomography (CT) are useful for diagnosis. The omentum, transverse colon, and less often, the stomach and small bowel herniate to the thorax. Surgery is the only treatment, which can be performed through transthoracic, transabdominal, laparoscopic, or thoracoscopic approach. Our aim was to discuss the clinical presentation and management Morgagni hernia in adults.

CASE PRESENTATION

All patients provided informed consent for publishing the surgical data and documents for scientific purposes.

CASE 1

A 74-year-old female patient presented with abdominal pain, nausea, vomiting, and anorexia. Chest x-ray showed right paracardiac opacity (Figure 1A). Morgagni hernia was suspected and confirmed by a thoracoabdominal CT (Figure 1B). The patient underwent surgery through an upper midline incision, which revealed bilateral Morgagni hernia. Hernial sacs were present on both sides (Figure 1C). The left sac contained the stomach and large bowel and the right sac contained the omentum. The contents were reduced, and the sacs were not excised. Both defects were repaired using an expanded polytetrafluoroethylene (E-PTFE) mesh (Figure 1D). Postoperatively, the patient had recovered and was discharged on postoperative day 4. On postoperative day 32, the patient presented with seroma in the repaired defect. The fluid was aspirated under ultrasound guidance. No further complications, including recurrent seroma, occurred during the 63 months of follow-up.

CASE 2

A 62-year-old woman was referred from another institute with the diagnosis of Morgagni hernia. The patient complained of dyspnea, nausea, vomiting, and episodic right flank pain. Thoracoabdominal CT revealed Morgagni hernia, cholelithiasis, and umbilical hernia. Laparoscopic repair was considered. Gastric and omental herniation to the thorax via a 4-cm diaphragmatic unilateral defect was seen in laparoscopic examination (Figure 2A). The stomach and omentum were reduced into the abdominal cavity, and the diaphragmatic defect was repaired using polypropylene stitches (Figure 2B-D). The hernial sac was not resected,

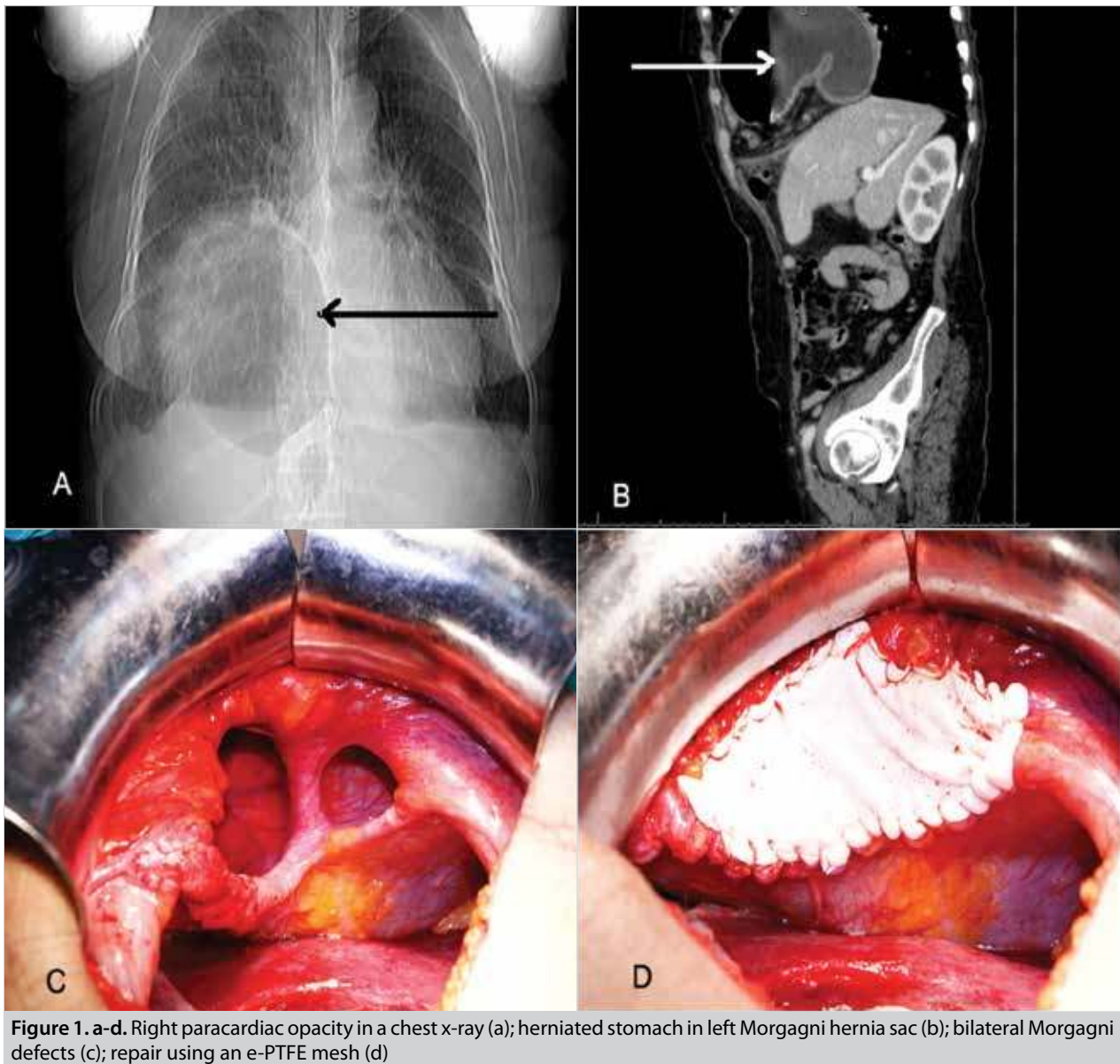


Figure 1. a-d. Right paracardiac opacity in a chest x-ray (a); herniated stomach in left Morgagni hernia sac (b); bilateral Morgagni defects (c); repair using an e-PTFE mesh (d)

and a silicon drain was placed in the sac. The surgery was completed after a laparoscopic cholecystectomy and umbilical hernia repair. The patient was discharged on postoperative day 5. She was followed up for 58 months without any complications.

CASE 3

A 63-year-old female patient consulted to the emergency department with abdominal pain, nausea, and vomiting. The patient presented with signs of ileus in an abdominal x-ray, but there were no signs of free subdiaphragmatic air; chest x-ray indicated diaphragmatic hernia. Thoracoabdominal CT revealed ileal and colonic dilatations and diaphragmatic hernia. Examination through an upper midline incision revealed dilated ileal segments in accordance with ileus and a 9-cm unilateral diaphragmatic hernia defect comprising the omentum and transverse colon. The colon and omentum were reduced into the abdominal cavity, and the diaphragmatic defect was repaired with using polypropylene sutures (Prolene no. 1, Ethicon, Amersfoort, the Netherlands). The patient was discharged uneventfully on postoperative day 5. No complication or recurrence was noted at 44 months of follow-up.

CASE 4

A 63-year-old female patient was referred to our clinic with an incidentally diagnosed diaphragm hernia in a chest x-ray performed for her chest pain. The patient presented with a medical history of gastroesophageal reflux and grade b esophagitis for 6 years. Thoracoabdominal CT finding was compatible with Morgagni hernia. Laparoscopic exploration revealed the thoracic herniation of the transverse colon. Bilateral Morgagni defects of 6 cm on the right side and 3 cm on the left side were detected after reducing the colon. The hernial sac was not resected, and the defect was closed with no.1 polypropylene stitches. Laparoscopic Nissen fundoplication was performed for the gastroesophageal reflux. A silicon drain was placed in the hernial sac, and operation was completed. The patient was uneventfully discharged on postoperative day 6. On postoperative day 45, she was admitted with dyspnea. A chest x-ray revealed air-fluid level in the hernial sac, and 200 cc seroma was drained under ultrasound guidance. The culture of aspirated fluid was negative. The seroma did not recur, but 6 months later she consulted for dyspnea. A recurrent hernia was detected on thoracoabdominal CT. Open repair surgery

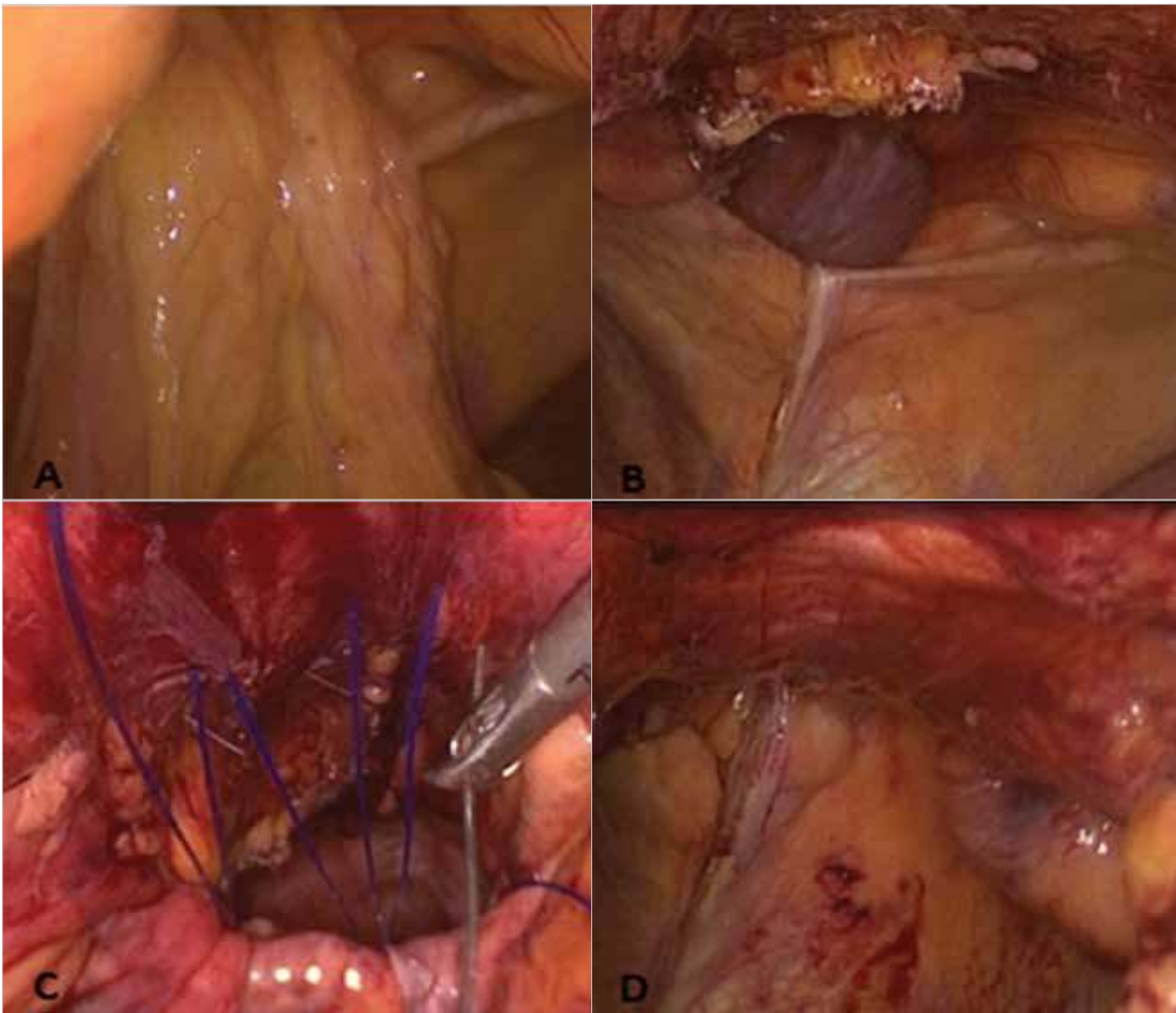


Figure 2. a-d. Herniated stomach and omentum through a 4-cm diaphragmatic defect (a); hernia sac was reduced into the abdominal cavity (b); laparoscopic primary closure of the defect with polypropylene stitches (c); intraoperative view after primary repair (d)

with E-PTFE mesh was performed. During 36 months since the second surgery, no further complication was noted.

CASE 5

A 51-one-year old male patient presented with abdominal distention and vomiting. The patient presented with a medical history of hypertension. Chest x-ray revealed air-fluid levels over the diaphragm compatible with herniated intestinal segments to the thorax. Laparoscopy revealed a left Morgagni hernia comprising the transverse colon. The sac was reduced, and the defect was closed primarily using no.1 polypropylene stitches. A silicone drain was placed in the hernia sac. The patient was discharged on postoperative day 5 and followed up for 15 months.

DISCUSSION

The classical Bochdalek hernia accounts for approximately 80% of all the congenital diaphragmatic hernias, while Morgagni hernia accounts for approximately 3%–4% diaphragmatic hernias in of both children and adults (3). In Morgagni hernia, the defect is usually small, and complaints vary with the size of hernia and herniated organ. The herniated organs

most frequently include the omentum and colon segments; however, the stomach, liver, and small intestines might also be herniated (5). Morgagni hernias are right sided in 90% of the cases, left sided in 8%, and bilateral in 2% (4). In our cases, three of the five patients showed unilateral and the other two patients showed bilateral hernias. A previous case series has reported that 62% of the cases were females, and the mean age at diagnosis was 53 years (5). Four of the five cases were females, and the mean age at diagnosis was 62.6 (51–74) years in our series. The symptomatology of Morgagni hernia is diverse; the cases can be asymptomatic or may present with a clinical scenario of acute respiratory distress (6). In diaphragmatic hernia, a decrease in the respiratory sounds or the presence of colonic sounds on chest examination is a significant finding during diagnosis. All the patients in our series presented with symptoms related to hernia, varying between retrosternal pain and ileus. Chest x-ray and thorax CT are useful diagnostic modalities (7). The signs in the chest x-ray may mimic a mediastinal mass in some cases in which hernial sac comprises the omentum alone. We preferred to perform thoracoabdominal CT to confirm the diagnosis following chest x-ray. Surgery is the curative treatment in Morgagni hernia,

which may be performed through transthoracic, transabdominal, and laparoscopic approaches. Thoracoscopic repair has been reported in two patients from the UK (8, 9). Laparoscopic approaches are more favored owing to less complication and short hospital stay. Nonetheless, open surgery has some advantages. In open surgery, the reduction of herniated organs is easier, the functional status and circulation of the organs may be evaluated better, and it more readily detects a bilateral Morgagni defect. In addition, a thoracic surgery allows for the easier dissection of mediastinal and pleural adhesions (5, 10, 11). We performed two transabdominal and three laparoscopic surgeries. Approximately 95% of the Morgagni hernias comprise a hernial sac, but the resection of the hernial sac remains controversial. Some authors have suggested the retention of sac to avoid massive pneumomediastinum and injuries to the phrenic nerve (12). Rau et al. (13) have recommended that retaining the sac may result in thoracic cystic lesions, and thus, it should be resected. We preferred to retain the sac in all the cases to avoid pneumothorax and nerve injuries. In the literature, transabdominal approaches have been performed by primary repair in 88% of the cases and by mesh repair in 6% of the cases. The primary and mesh repair rates were reported to be 29% and 64%, respectively, in laparoscopic approaches (5). Thoman et al. (14) have suggested that mesh repair may be favorable in defects larger than 20–30 cm². Notably, the results of primary and mesh repairs are similar (5). The recurrence after transthoracic Morgagni hernia repair in adults has been reported in one patient. Other surgical methods have not been reported for recurrence in adults (5). Case 4 is the first reported recurrence in literature following laparoscopic repair in adults. Recurrence in 5 of the 12 children has been reported in a laparoscopic repair series (15). We performed four primary repairs (three laparoscopic) and one mesh repair (open transabdominal). The recurrence of a laparoscopic primary repair was restored with open mesh repair. The complications following transabdominal surgery include pleural effusion, surgical site infection, atelectasis, deep venous thrombosis, and pulmonary embolism. Pneumonia and sepsis have been reported following transthoracic surgery. The 30-day mortality has been reported in four patients after the transabdominal surgery (5). In our patients, the mean hospital stay was 5 days, but we did not observe the 30-day mortality. Seroma was observed on postoperative days 32 and 45 in two patients after one transabdominal and one laparoscopic surgery, both of which did not recur after drainage. In our clinical experience, one patient showed recurrent hernia 7 months after the laparoscopic surgery (case 4), which was resolved by repeat open repair.

CONCLUSION

Morgagni hernia is a rare type of hernia, particularly in adults, but it may cause intestinal obstruction and may present as an emergency due to the strangulation of the herniating viscera. Once diagnosed, surgery should be recommended even in asymptomatic patients to prevent the risk of complications. Different surgical approaches can be efficiently used to repair Morgagni hernia, and the choice of surgical procedure is based on the characteristics of patients.

Informed Consent: Written informed consent was obtained from patients who participated in this study.

Peer-review: Externally peer-reviewed.

Author Contributions: Concept - C.A., K.A.; Design - C.A., K.A. S.B.; Supervision - C.A., K.A. N.Ç.A., Z.S.D., S.B.; Resource - C.A., K.A., S.B.; Materials C.A., K.A., Z.S.D., S.B.; Data Collection and/or Processing - C.A., N.Ç.A., Z.S.D.; Analysis and/or Interpretation - C.A., K.A. N.Ç.A., Z.S.D., S.B.; Literature Search - C.A., K.A. N.Ç.A.; Writing Manuscript - C.A., K.A., N.Ç.A., Z.S.D., S.B.; Critical Reviews - K.A., S.B.

Conflict of Interest: The authors have no conflicts of interest to declare.

Financial Disclosure: The authors declared that this study has received no financial support.

REFERENCES

1. Laberge JM. Congenital diaphragmatic hernia. In: Nyhus LM, Condon R, editors. *Hernia* 4th ed. Philadelphia: J.B. Lippincott Co.; 1995: 555-566.
2. Federico JA, Ponn RB. Foramen of Morgagni hernia. In: Shields TW, LoCicero III J, Ponn RB, editors. *General Thoracic Surgery*. Philadelphia, Lippincott Williams & Wilkins, 2000; 647-650.
3. Paris F, Tarazona V, Casillas M, Blasco E, Cantó A, Pastor J, et al. Hernia of Morgagni. *Thorax* 1973; 28: 631-636. [\[CrossRef\]](#)
4. Comer TP, Clagett OT. Surgical treatment of hernia of the foramen of Morgagni. *J Thorac Cardiovasc Surg* 1966; 52: 461-468.
5. Horton JD, Hofmann LJ, Hetz SP. Presentation and management of Morgagni hernias in adults: a review of 298 cases. *Surg Endosc* 2008; 22: 1413-1420. [\[CrossRef\]](#)
6. Wong NA, Dayan CM, Virjee J, Heaton KW. Acute respiratory distress secondary to Morgagni diaphragmatic herniation in an adult. *Postgrad Med J* 1995; 71: 39-41. [\[CrossRef\]](#)
7. Gossios KJ, Tatsis CK, Lykouri A, Constantopoulos SH. Omental herniation through the foramen of Morgagni. Diagnosis with chest computed tomography. *Chest* 1991; 100: 1469-1470. [\[CrossRef\]](#)
8. Akamine S, Kawahara K, Nakamura A, Takahashi T, Yamamoto S, Ayabe H, et al. Successful utilization of a video assisted thoracoscopic (VATS) approach to repair Morgagni's hernia: report of a case. *Surg Today* 1995; 25: 654-656. [\[CrossRef\]](#)
9. Hussong RL, Landreneau RJ, Cole FH. Diagnosis and repair of a Morgagni hernia with video assisted thoracic Surgery. *Ann Thorac Surg* 1999; 63: 1474-1475 [\[CrossRef\]](#)
10. Slaetis P. Herniation through the foramen of Morgagni: clinical observations in 17 operatively treated cases. *Ann Chir Gynaecol Fenn* 1963; 52: 477-486.
11. Loong TP, Kocher HM. Clinical presentation and operative repair of hernia of Morgagni. *Postgrad Med J* 2005; 81: 41-44. [\[CrossRef\]](#)
12. Orita M, Okino M, Yamashita K, Morita N, Esato K. Laparoscopic repair of a diaphragmatic hernia through the foramen of Morgagni. *Surg Endosc* 1997; 11: 668-670. [\[CrossRef\]](#)
13. Rau HG, Schardey HM, Lange V. Laparoscopic repair of a Morgagni hernia. *Surg Endosc* 1994; 8: 1439-1442. [\[CrossRef\]](#)
14. Thoman DS, Hui T, Phillips EH. Laparoscopic diaphragmatic hernia repair. *Surg Endosc* 2002; 16: 1345-1349. [\[CrossRef\]](#)
15. Garriboli M, Bishay M, Kiely E.M, Drake DP, Curry JI, Cross KM, et al. Recurrence rate of Morgagni diaphragmatic hernia following laparoscopic repair. *Pediatr Surg Int* 2013; 29: 185-189. [\[CrossRef\]](#)