










Laparoscopic resection of retroperitoneal bronchogenic cyst clinically presenting as adrenal cyst

Mahmut Başoğlu¹ , Kağan Karabulut¹ , Gökhan Selçuk Özbalcı¹ , Nihal Aykun¹ , İlkey Çamlıdağ² ,
Bahadır Bülent Güngör¹ , Mehmet Kefeli³ 

ABSTRACT

Bronchogenic cyst localized in the retroperitoneum is a rare clinical entity. It is a congenital malformation generally occurring in the posterior mediastinum due to the abnormal development of the foregut. We report the case of a retroperitoneal cyst presenting as left adrenal cyst. A 38-year-old female presented with left upper abdominal pain. Endocrinological evaluation was done, and no adrenal hormonal secretion was detected. The cyst was removed laparoscopically. Pathologic examination confirmed it as a bronchogenic cyst. Therefore, bronchogenic cysts should be considered in the differential diagnosis of retroperitoneal cysts. Laparoscopic resection of retroperitoneal cysts results in favorable outcome.

Keywords: Adrenal, bronchogenic cyst, retroperitoneal cystic mass, laparoscopic

ORCID IDs of the authors:

M.B. 0000-0003-3283-4483;
K.K. 0000-0003-4723-5360;
G.S.Ö. 0000-0003-0768-8306;
N.A. 0000-0001-5435-5016;
İ.Ç. 0000-0001-6151-1312;
B.B.G. 0000-0002-1086-4254;
M.K. 0000-0003-3437-5348.

Cite this paper as:

Başoğlu M, Karabulut K, Özbalcı GS, Aykun N, Çamlıdağ İ, Güngör BB, et al. Laparoscopic resection of retroperitoneal bronchogenic cyst clinically presenting as adrenal cyst. Turk J Surg 2018; 10.5152/turkjsurg.2018.4033.

¹Department of General Surgery, Ondokuz Mayıs University School of Medicine, Samsun, Turkey

²Department of Radiology, Ondokuz Mayıs University School of Medicine, Samsun, Turkey

³Department of Pathology, Ondokuz Mayıs University School of Medicine, Samsun, Turkey

This study was presented at the "7th National Endocrine Surgery Congress", "23-26 June 2015", "Antalya, Türkiye".

Corresponding Author

Mahmut Başoğlu

e-mail: mbasoglu@hotmail.com

Received: 18. 11.2017

Accepted: 29.01.2018

Available Online Date: 11.09.2018

©Copyright 2018

by Turkish Surgical Association

Available online at

www.turkjsurg.com

INTRODUCTION

Bronchogenic cysts are rare clinical malformations due to the abnormal development of the primitive foregut between the third and seventh weeks of embryonic life. They are generally localized in the posterior mediastinum because of abnormalities resulting from embryological budding of the bronchial tree and are rarely localized in the abdomen or retroperitoneum (1-3). Bronchogenic cysts are usually asymptomatic unless they are infected or are enlarged enough to compress a nearby organ. Symptoms are variable, depending on the location and diameter of the cyst (3-5). In most cases, retroperitoneal bronchogenic cysts occur on the corpus of the pancreas or left adrenal gland (6). Herein, we report the laparoscopic total resection of an incidental bronchogenic cyst that presented as a left adrenal cyst.

CASE PRESENTATION

A 38-year-old female with no significant past medical history was admitted with left upper abdominal pain. Complete blood count, serum liver function tests, amylase, and lipase were within normal limits. There was no history of palpitation, sweating, hypertension, or exhaustion. The secretory levels of all the adrenal gland hormones were normal. In addition, plasma and urine catecholamine metanephrine concentrations and aldosterone/renin ratio were normal. Carcinoembryonic antigen (CEA) and CA 19-9 were not elevated. Abdominal MRI axial turbo spin-echo T2-weighted (a) and T1-weighted (b) images revealed a 63×25×55-mm well-defined, ovoid, heterogeneous lesion with hyperintense components (arrows) in the left suprarenal region elevating the crus (Figure 1).

To confirm the diagnosis and to document the risk of malignant transformation, the cyst was removed laparoscopically. The surgery was performed in the left lateral decubitus position. Intraoperatively, the mass lesion was associated with the left adrenal gland and diaphragm; it was 60×80 mm in diameter. The mass included mucous and fluid, as seen in an abscess. The patient was discharged on the fourth postoperative day.

Pathological examination supported the diagnosis of a bronchogenic cyst. There was no malignant transformation. In addition, pathological examination revealed cartilage tissue and a mucous gland under the cyst wall (Figure 2).

Written informed consent was obtained from the patient.

DISCUSSION

Bronchogenic cysts are malformations that occur due to the abnormal development of the embryologic foregut in the early period. Their pathogenesis is not fully clear (3, 7).

Generally, these cysts are localized in the posterior of the carina or are embedded in the pulmonary parenchyma. If total separation occurs during abnormal budding, a cyst may migrate to a different

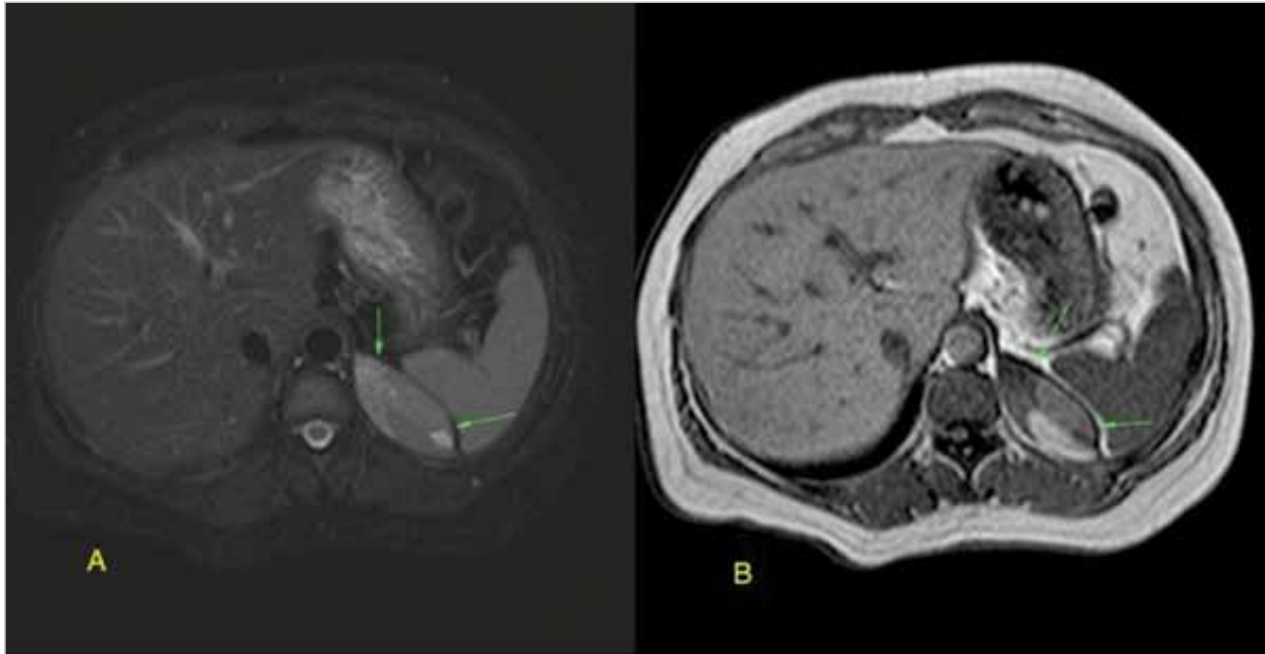


Figure 1. a, b. Axial turbo spin-echo T2-weighted (a) and T1-weighted (b) images reveal a well-defined, ovoid, heterogeneous lesion with hyperintense components (arrows) in the left suprarenal region abutting the diaphragmatic crus

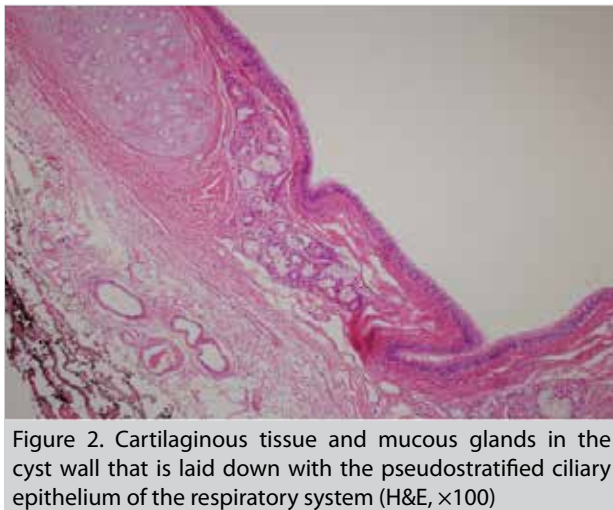


Figure 2. Cartilaginous tissue and mucous glands in the cyst wall that is laid down with the pseudostratified ciliary epithelium of the respiratory system (H&E, $\times 100$)

location. The cysts migrate particularly to the subcutaneous tissue around the sternum, shoulder, neck, pericardium, and diaphragm. However, retroperitoneal localization is 0.03% (1, 2, 6, 8, 9).

Generally, a bronchogenic cyst is asymptomatic and is discovered incidentally; however, sometimes back pain and epigastric pain may occur. A cyst can lead to secondary complications. Its diameter is usually less than 5 cm, but sometimes it can lead to infection, acute hemorrhage, perforation, and the compression of other organs (1, 2, 6, 7, 10). Our patient had left abdominal pain.

Histologically, bronchogenic cysts are well defined because they contain ciliary respiratory epithelium, mucinous glands, and well-differentiated cartilage (3, 6). A pancreatic pseudocyst, adrenal cyst, cystic lymphangioma, and cystic teratoma should be considered in the differential diagnosis of retroperitoneal bronchogenic cysts (2). In our case, the decision of surgery is taken because of diagnosis of the ad-

renal cyst. But after surgery it was diagnosed as retroperitoneal bronchogenic cyst.

Endocrinological evaluation must be performed in cases where the bronchogenic cyst is adherent to the adrenal gland or is localized in it. But this data may not be helpful for the diagnosis (3).

Surgery is recommended to make the diagnosis certain, reduce the symptoms, prevent infection, and document the risk of malignant transformation (11, 12). A surgery can be performed by an experienced laparoscopic surgeon. The laparoscopic approach results in less postoperative pain, a shorter hospital stay, and less cost. Postoperative outcomes are reliable and no complications have been reported (1, 7). We performed the laparoscopic excision successfully in our patient and there have been no postoperative complications.

CONCLUSION

A retroperitoneal bronchogenic cyst is a rare clinical entity. A differential diagnosis must be considered for retroperitoneal cysts. It is difficult to make a preoperative diagnosis; therefore, surgery is recommended to confirm the diagnosis. Laparoscopic surgery can be performed by an experienced surgeon, and postoperative outcomes are reliable.

Informed Consent: Written informed consent was obtained from patient who participated in this study.

Peer-review: Externally peer-reviewed.

Author Contributions: Concept - M.B.; Design - K.K., S.Ö.; Supervision - M.B.; Resource - M.B.; Materials - M.K., İ.C.; Data Collection and/or Processing - K.K., M.B.; Analysis and/or Interpretation - K.K., M.B., N.A.; Literature Search - B.G.; Writing Manuscript - K.K., N.A.; Critical Reviews - K.K., M.B.

Conflict of Interest: The authors have no conflicts of interest to declare.

Financial Disclosure: The authors declared that this study has received no financial support.

REFERENCES

1. Dong B, Zhou H, Zhang J, Wang Y, Fu Y. Diagnosis and treatment of retroperitoneal bronchogenic cysts: A case report. *Oncol Lett* 2014; 7: 2157-2159. [\[CrossRef\]](#)
2. Castro R, Oliveira MI, Fernandes T, Madureira AJ. Retroperitoneal bronchogenic cyst: MRI findings. *Case Rep Radiol* 2013; 2013: 853795. [\[CrossRef\]](#)
3. Runge T, Blank A, Schäfer SC, Candinas D, Gloor B, Angst E. A retroperitoneal bronchogenic cyst mimicking a pancreatic or adrenal mass. *Case Rep Gastroenterol* 2013; 7: 428-432. [\[CrossRef\]](#)
4. Murakami R, Machida M, Kobayashi Y, Ogura J, Ichikawa T, Kumazaki T. Retroperitoneal bronchogenic cyst: CT and MR imaging. *Abdom Imaging* 2000; 25: 444-447. [\[CrossRef\]](#)
5. Doggett RS, Carty SE, Clarke MR. Retroperitoneal bronchogenic cyst masquerading clinically and radiologically as a pheochromocytoma. *Virchows Arch* 1997; 431: 73-76. [\[CrossRef\]](#)
6. Mirsadeghi A, Farrokhi F, Fazli-Shahri A, Gholipour B. Retroperitoneal bronchogenic cyst: a case report. *Med J Islam Repub Iran* 2014; 28: 56.
7. Cao DH, Zheng S, Lv X, Yin R, Liu LR, Yang L, et al. Multilocular bronchogenic cyst of the bilateral adrenal: report of a rare case and review of literature. *Int J Clin Exp Pathol* 2014; 7: 3418-3422.
8. Parray FQ, Sherwani AY, Dangroo SA, Bisati RA, Malik NS. Retroperitoneal bronchogenic cyst mimicking hydatid liver: a case report. *Case Rep Surg* 2012; 2012: 312147. [\[CrossRef\]](#)
9. Menke H, Röher HD, Gabbert H, Schweden F. Bronchogenic cyst: a rare cause of aretroperitoneal mass. *Eur J Surg* 1997; 163: 311-314.
10. Goh BK, Chan HS, Wong WK. A rare case of "giant" right-sided retroperitoneal bronchogenic cyst. *Dig Dis Sci* 2004; 49: 1491-1492. [\[CrossRef\]](#)
11. Sullivan SM, Okada S, Kudo M, Ebihara Y. A retroperitoneal bronchogenic cyst with malignant change. *Pathol Int* 1999; 4: 338-341. [\[CrossRef\]](#)
12. Balcı AE, Özalp K, Ayan E, Duran M. Bronchogenic cyst in the mediastinum: a case report. *Turkish J Thorac Cardiovasc Surg* 2005; 13: 286-289.