



# Experimental pericardial tamponade—translation of a clinical problem to its large animal model

Gábor Bari<sup>2</sup> , Szilárd Szűcs<sup>1</sup> , Dániel Ércses<sup>1</sup> , Mihály Boros<sup>1</sup> , Gabriella Varga<sup>1</sup>

## ABSTRACT

**Objectives:** Pericardial tamponade is a life-threatening medical emergency, when the hemodynamic consequences of low cardiac output severely disturb the perfusion of the peripheral tissues. Our aim was to design a reliable large animal model to reproduce the clinical scenario with the relevant pathophysiological consequences of pericardial tamponade -induced cardiogenic shock.

**Material and Methods:** Anesthetized Vietnamese mini pigs were used (n=12). Following laparotomy, a cannula was fixed into the pericardium through the diaphragm without thoracotomy. A sham-operated group (n=6) served as control, while in the second group (n=6) pericardial tamponade was induced by intra-pericardial injection of heparinized own blood. Throughout the 60-min pericardial tamponade and the 180-min reperfusion, macro hemodynamics, renal circulation and the mesenteric macro- and micro-circulatory parameters were monitored. Myeloperoxidase activity was measured to detect neutrophil leukocyte accumulation and in vivo histology was performed by confocal laser scanning endomicroscopy to observe the structural changes of the intestinal mucosa.

**Results:** PT increased the central venous pressure, heart rate, and decreased mean arterial pressure. The mesenteric artery flow (from 355.5±112.4 vs 182.0±59.1 mL/min) and renal arterial flow (from 159.63±50.7 vs 35.902±27.9 mL/min) and the micro-circulation of the ileum was reduced. The myeloperoxidase activity was elevated (from 3.66±1.6 to 7.01±1.44 mU/mg protein) and manifest injury of the ileal mucosa was present.

**Conclusion:** This experimental model suitably mimics the hemodynamics and the pathology of clinical pericardial tamponade situations, and on this basis, it provides an opportunity to study the adverse macro- and micro-circulatory effects and biochemical consequences of human cardiogenic shock.

**Keywords:** Animal model, cardiogenic shock, mesenteric ischemia, mini pig, pericardial tamponade

## ORCID IDs of the authors:

G.B. 0000-0003-4167-5736;  
S.S. 0000-0001-8478-6386;  
D.E. 0000-0002-4283-2441;  
M.B. 0000-0003-1410-1999;  
G.V. 0000-0003-1888-8629.

## Cite this paper as:

Bari G, Szűcs S, Ércses D, Boros M, Varga G. Experimental pericardial tamponade—translation of a clinical problem to its large animal model. Turk J Surg 2018 34 (3): 205-211.

<sup>1</sup>Institute of Surgical Research, Szeged University, Szeged, Hungary

<sup>2</sup>Department of Cardiac Surgery, Szeged University, Szeged, Hungary

This study was presented at the 17<sup>th</sup> Congress of the European Shock Society, 13-15/09/2017, Paris, France.

## Corresponding Author

**Gabriella Varga**

e-mail:  
varga.gabriella.1@med.u-szeged.hu

Received: 06.04.2018

Accepted: 18.06.2018

©Copyright 2018  
by Turkish Surgical Association  
Available online at  
www.turkjsurg.com

## INTRODUCTION

This article will explore the line between patients and experimental subjects, in an attempt to provide a proper view on the role of classical surgical research in contemporary cardiac surgery. According to the proverbial quote of Francis D. Moore, a “*surgical investigator must be a bridge tender, channeling knowledge from biological science to the patient’s bedside and back again*” (1). This traditional approach emphasizes the great potential of biomedical sciences to provide help for unsolved problems in surgery. An equally important aspect of this type of research is that it develops new data, or more comprehensible knowledge on a specific area of clinical practice. In this sense, the science of surgery, like any other area of biomedical sciences, has four main methodological steps: observation of a clinical problem, formulation of a hypothesis, and performance of test procedures to reach a conclusion, supporting or refuting the initial hypothesis. In this analytical circle, models are indispensable tools to check the validity of hypotheses and to generate clinically useful data. In pragmatic terms differences are always present between the clinical reality and the models and therefore these dissimilarities should be reduced by choosing the experimental setup as accurate as possible. Understandably, the demand is huge for developing high fidelity models to decrease existing limitations and to obtain better applicable results for human medical science and healthcare (2).

A specific problem addressed by our study is cardiogenic shock due to cardiac tamponade. Pericardial tamponade is one of the most dreadful complication of cardiac surgery and invasive cardiology. Tamponade can develop after myocardial infarction, it can be the corollary of intra- or post-operative complications, or the consequence of non-cardiac surgical procedures (NCSP) as well (3). During tamponade, fluid will accumulate within the pericardial space, which can be transudate or pus, however the most common cause is bleeding (4). The increasing pressure in the closed pericardial sac blocks the venous inflow and decreases stroke volume. The subsequently reduced cardiac output (CO) results in tissue hypoxia and multi-organ damage. The long-term systemic consequences of pericardial tamponade are pronounced and serious even after the primary cause has been diagnosed and the basic problem was solved, i.e., the pericardial pressure was decreased via pericardiocentesis, re-operation or other intervention (5). The main reason for late complications is ischemia-reperfusion injury of distant organs, including the lungs, kidneys, and splanchnic tissues. This circulatory condition results in an antigen-

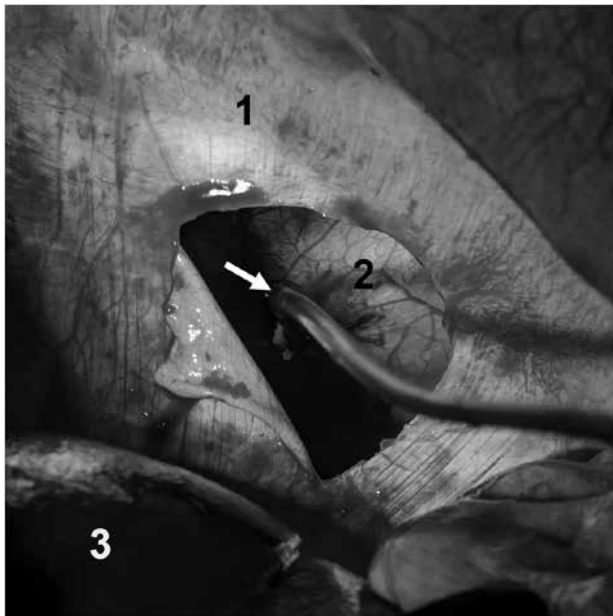


Figure 1. The insertion of the pericardial cannula via the transphrenic route (1 diaphragm, 2 pericardium, 3 liver, arrow: the cannula fixed into the pericardium)

independent inflammatory reaction with cytokine storm and increased endothelial permeability, which finally leads to an overwhelmingly severe systemic immune response (6).

According to previous experiences, cardiogenic shock can be modelled if an animal is anaesthetized, mechanically ventilated, and the pericardial sac is accessible through thoracotomy (7). The disadvantage of the model is thoracotomy itself with significantly impaired lung function, extended wound surface with a high risk of bleeding, lung injury, and tissue damage. Based on the above, our aim was to develop an experimental procedure where thoracotomy can be avoided and thus to design a new model of iatrogenic cardiogenic shock, where the situation is realistic, similar to the clinical appearance.

## MATERIAL AND METHODS

### Animals

The experiments were performed in accordance with National Institutes of Health guidelines on the handling and care of experimental animals and European Union Directive 2010/63 for the protection of animals used for scientific purposes. The study was approved by the Animal Welfare Committee of the University of Szeged (approval number: V/148/2013).

### Surgical interventions

Anesthesia was induced by a mixture of ketamine (20 mg kg<sup>-1</sup> *im.*) and xylazine (2 mg kg<sup>-1</sup> *im.*) and maintained by a continuous infusion of propofol (6 mg kg<sup>-1</sup>h<sup>-1</sup> *iv.*). The animals were placed on heating pad in a supine position; the body temperature was kept between 36–37°C. After endotracheal intubation, mechanical ventilation was started with a tidal volume of 10 mlkg<sup>-1</sup>. The left jugular vein was cannulated for fluid and drug administration and the left femoral artery for the measurement of mean arterial pressure (MAP), heart rate (HR) and cardiac output (CO) by transpulmonary thermodilution (PICCO Catheters; PULSION Medical Systems, Feldkirchen, Germany). MAP, HR, CO and SMA flow (SMAF) data were recorded, pres-

sure signals (BPR-02 transducer; Experimetria Ltd, Budapest, Hungary) and superior mesenteric artery (SMA), renal artery (RA) flow signals (T206 Animal Research Flowmeter; Transonic Systems Inc., Ithaca, NY, USA) were measured continuously by surgically placing a urinary catheter in the bladder via the femoral incision. and registered with a computerized data-acquisition system (SPEL Advanced HAEMOSYS 1.17; Experimetria Ltd, Budapest, Hungary). Ringer's lactate was given at the rate of 10 mlkg<sup>-1</sup>h<sup>-1</sup>. After a median laparotomy, the SMA was dissected free and a flow probe was placed around the SMA (Transonic Systems Inc., Ithaca, NY, USA). The RA was dissected free and a flow probe was placed around it (Transonic Systems Inc., Ithaca, NY, USA). The wound of the abdominal wall was temporarily closed thereafter with clips. In addition, intra-vital examination of the intestinal microcirculation was carried out by an orthogonal polarization spectral imaging system (OPS; Cytoscan A/R, Cytometrics, Philadelphia, PA, USA), and the extent of damage of the gastric mucosa was evaluated by *in vivo* histology (Five1, Optiscan Pty. Ltd., Melbourne, Victoria, Australia). The diaphragm was accessed through a median laparotomy and a 3-cm incision was made at the sternal part, avoiding the muscular region of the diaphragm. The pericardium was opened and a cannula was fixed into the pericardial cavity with a pledgeted purse string suture (Figure 1). The tamponade was induced for 60 min by intra-pericardial administration of heparinized own blood (100±50 mL), and the MAP was kept between 40–45 mmHg. During the observation period and between microcirculatory imaging the abdominal wall was closed by surgical clips.

### Experimental Protocol

The animals were randomly allocated into two experimental groups. Group 1 (n=6) served as sham-operated control, with the same surgical interventions, time-frame, and sampling as in group 2 (n=6) but without the induction of a tamponade. In both groups, the diaphragm was accessed through a median mini-laparotomy. A 3-cm incision was performed at the sternal part, avoiding the muscular region of the diaphragm. The pericardium was opened and a cannula was fixed into the pericardial cavity with a pledgeted purse string suture. In Group 2, after the end of 60-min tamponade the blood was released from the pericardial sac and the animals were monitored for 180 min. Blood gas and hemodynamic parameters were measured in every 30 min. *In vivo* histological examination on the ileal mucosa and determination of neutrophil granulocytes was performed at baseline, 30 min after the relief of tamponade (90 min) and at the end of the experiments (240 min). Myeloperoxidase enzyme activity was measured at the -5; 30; 60; 90 and 240 min of observation period.

### Hemodynamic Measurements

Central venous pressure (CVP), mesenteric and renal artery blood flow (AMSF, ARF) signals were monitored continuously and registered with a computerized data acquisition system (SPELL Hemosys; Experimetria, Budapest, Hungary). The MAP, CO, and HR were measured with the PICCO Plus monitoring system (PULSION Medical Systems; Munich, Germany).

### Myeloperoxidase enzyme activity

Blood samples (0.5 mL) were taken from the left jugular vein into precooled, heparinized (100 U mL<sup>-1</sup>) polypropylene tubes, centrifuged at 1.200 g at 4°C for 15 minutes, and stored at

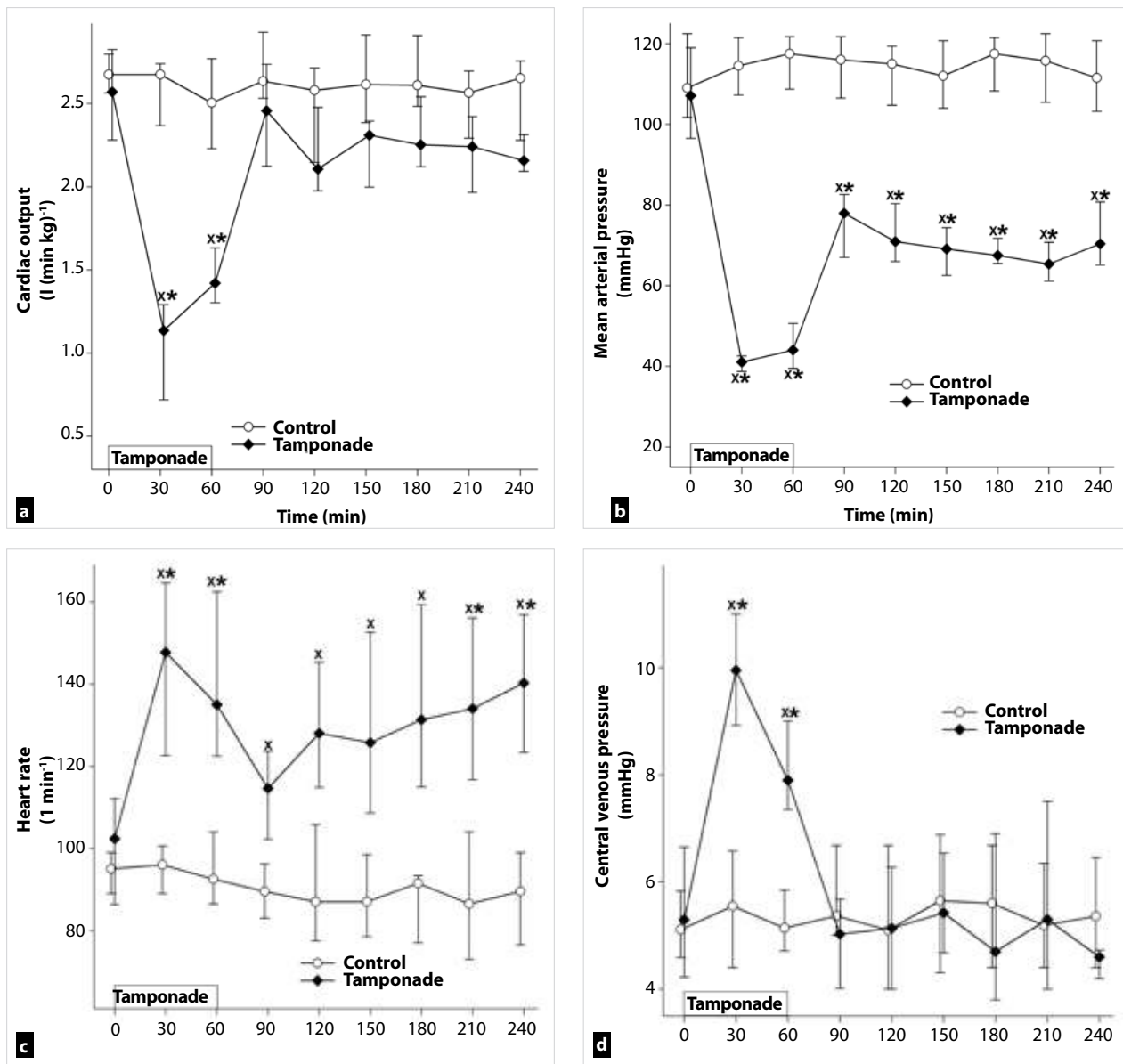


Figure 2. a-d. Changes in cardiac index (a), mean arterial pressure (b), heart rate (c), and central venous pressure (d) in control (white circle–solid line) and tamponade groups (black diamond–solid line). The plots demonstrate the median and the 25<sup>th</sup> (lower whisker) and 75<sup>th</sup> (upper whisker) percentiles

\* $p < 0.05$  for groups vs baseline values,  $x p < 0.05$  for cardiac tamponade vs control group values

–70°C until assay. Plasma MPO enzyme activity, a marker of polymorphonuclear leukocyte activation, was determined by the modified method of Kaszaki et al. (7).

### Microcirculatory measurement

An intra-vital orthogonal polarization spectral imaging technique (Cytoscan A/R; Cytometrics, Philadelphia, PA) was used for non-invasive visualization of the mucosal microcirculation of ileum. This technique utilizes reflected polarized light at the wavelength of the isosbestic point of oxy- and deoxyhemoglobin (548 nm). As polarization is preserved in reflection, only photons scattered from a depth of 200 to 300  $\mu\text{m}$  contribute to image formation. A  $\times 10$  objective was placed onto the mucosal surface of the small intestine, and microscopic images were recorded by a S-VHS video recorder 1 (Panasonic AG-TL 700; Matsushita Electric Ind, Osaka, Japan). Quantitative assessment of the microcirculatory parameters was accomplished off-line by frame-to-frame analysis of the videotaped

images. Red blood cell velocity (RBCV,  $\mu\text{m/s}$ ) changes in the capillary were determined in three separate fields by means of a computer-assisted image analysis system (IVM Pictron, Budapest, Hungary). All microcirculatory evaluations were performed by the same investigators (GB and GV).

### In vivo detection of mucosal damage

The extent of damage of the ileal mucosa was evaluated by means of fluorescence confocal laser scanning endomicroscopy (CLSEM) developed for *in vivo* histology. The analysis was performed twice, separately by two investigators (GV and GB). The mucosal surface of the ileum was surgically exposed and laid flat for examination. The ileal mucosal structure was recorded after the topical application of the fluorescent dye acriflavin (Sigma-Aldrich Inc, St. Louis, MO, USA). The surplus dye was washed off the mucosal surface of the ileum with saline 2 min before imaging. The objective of the device was placed onto the mucosal surface of the ileum and confocal imaging

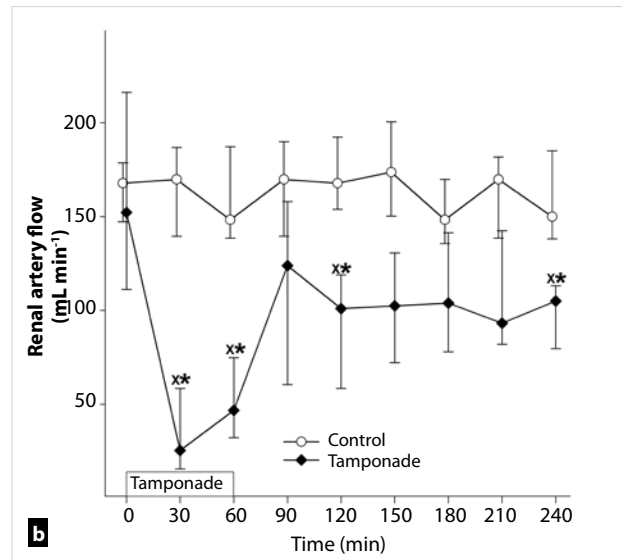
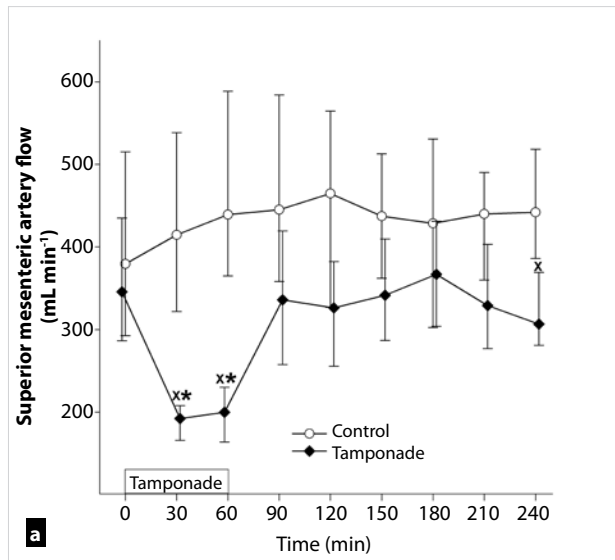


Figure 3. a-b. Changes in mesenteric artery (a) and renal artery flow (b) in control (white circle–solid line) and tamponade (black diamond–solid line) groups. The plots demonstrate the median and the 25<sup>th</sup> (lower whisker) and 75<sup>th</sup> (upper whisker) percentiles.

\*p<0.05 for groups vs baseline values, \*\*p<0.05 for cardiac tamponade vs control group values

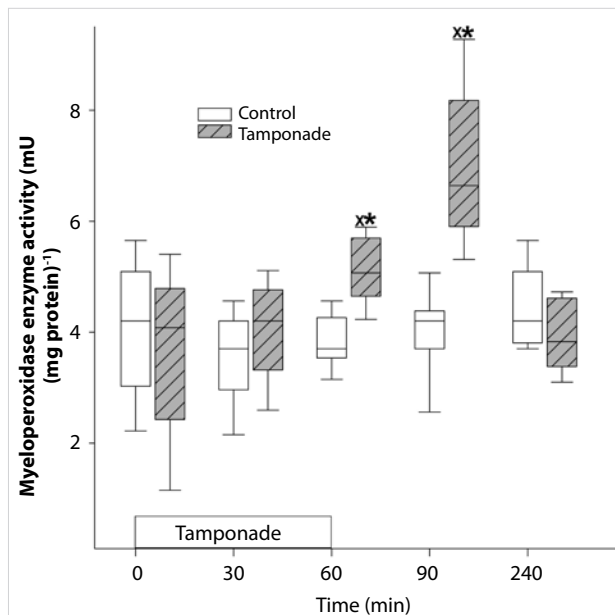


Figure 4. Changes in myeloperoxidase enzyme activity in control (white box) and tamponade (gray striped box to the right side) groups. The plots demonstrate the median and the 25<sup>th</sup> (lower whisker) and 75<sup>th</sup> (upper whisker) percentiles \*p<0.05 for groups vs baseline values, \*\*p<0.05 for cardiac tamponade vs control group values

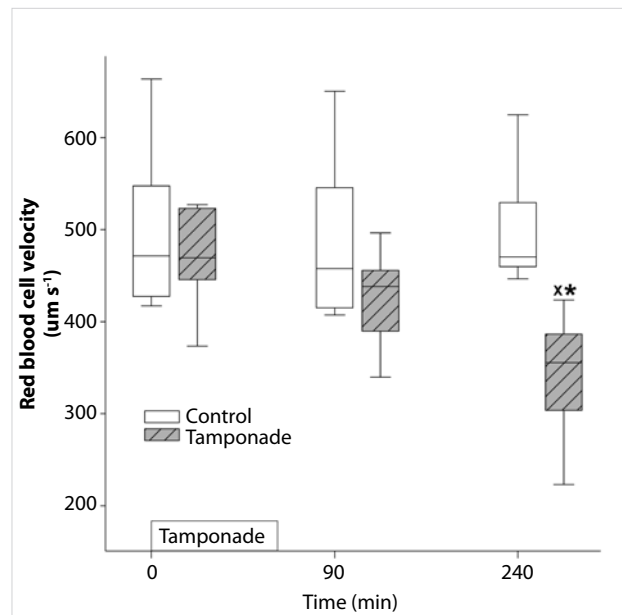


Figure 5. Changes in red blood cell velocity in control (white box) and tamponade (gray striped box to the right side) groups. The plots demonstrate the median and the 25<sup>th</sup> (lower whisker) and 75<sup>th</sup> (upper whisker) percentiles. \*p<0.05 for groups vs baseline values, \*\*p<0.05 for cardiac tamponade vs control group values

was performed 5 min after dye administration (1 scan/image, 1024x512 pixels and 475x475 µm per image). The changes in the mucosal architecture were examined by using a semi-quantitative scoring system as described previously (8). (I. oedema (0=no oedema, 1=moderate epithelial swelling, 2=severe oedema); and II. epithelial cell outlines (0=normal, clearly, well-defined outlines, 1=blurred outlines, 2=lack of normal cellular contours).

#### Statistical Analysis

Data analysis was performed with a statistical software package (SigmaStat for Windows, Jandel Scientific, Erkrath, Germany).

Friedman repeated measures analysis of variance on ranks was applied within groups. Time-dependent differences from the baseline for each group were assessed by Dunn's method. The differences between groups were analyzed with Mann-Whitney probe. In the figures, median values and 75<sup>th</sup> and 25<sup>th</sup> percentiles are given; p<0.05 were considered significant.

#### RESULTS

##### Changes in Hemodynamic Parameters

The average duration of the surgical preparation phase was 70±20 min. The MAP remained at 40–45 mmHg as previously

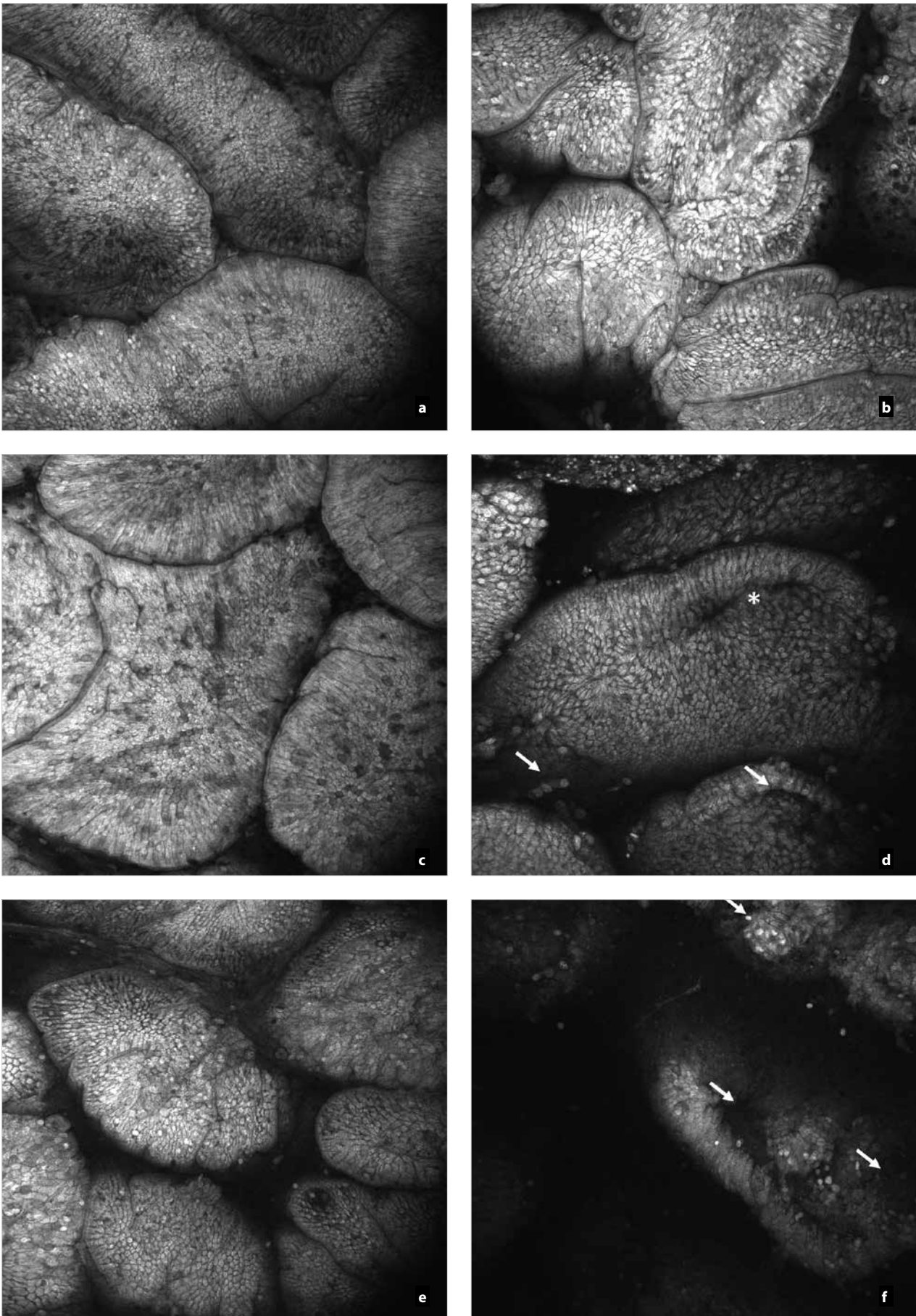


Figure 6. a-f. *In vivo* histology (CLSEM technique) showing the changes of the epithelial surface of the terminal ileum after acriflavin staining. Mucosal surface of control group (a, c, e); and structure of mucosal surface in tamponade group (b, d, f) are shown

planned throughout the 60 min of pericardial tamponade, accompanied by a concomitantly decreased CO. The CO increased to baseline levels after the reversal of tamponade (Figure 2a) but the MAP remained significantly depressed (Figure 2b). The elevation of CO was accompanied by a compensatory elevation of HR (Figure 2c). The decreased venous return was evidenced by a significant elevation of CVP throughout the tamponade phase.

Significant deterioration of artery mesenteric flow was observed during tamponade, but no significant differences were found in the post-tamponade phase as compared to the baseline values and the control group (Figure 3a). The renal artery flow was significantly and permanently reduced during tamponade and the post-tamponade period as well (Figure 3b).

#### Leukocyte accumulation

The plasma MPO activity increased during the tamponade period and its peak was reached 30 minutes after tamponade. At the end of the observation period the MPO activity decreased towards the control level (Figure 4).

#### Changes in microcirculation

The RBCV did not change in the control group, while in the tamponade group, a significant decrease from the baseline and control group was detected but at the end of the observation period (Figure 5).

#### In vivo Histology

The mucosal morphology was examined by intra-vital CLSEM technique in real time. The epithelial morphology of the small intestinal mucosa presented normal morphological patterns in sham-operated animals and in the control samples of the tamponade group while 30 min after tamponade induction longitudinal fissures appeared and partial epithelium defects were detected (Figure 6a-e). The lack of epithelium was extended by the end of observation (Figure 6f).

#### DISCUSSION

Animal models have important, sometimes, decisive roles in today's medical research. Large animal models have many advantages for studying human pathophysiology and by their size they can provide additional benefits for the development of new surgical techniques and therapies. Experimental pericardial tamponade models using thoracotomy can be suitable to examine the complication of open cardiac surgical procedures or to monitor the hemodynamic changes (7, 9). Our purpose was to develop a suitable model based on experimental surgical standards for the investigation of cardiogenic shock, which evolves after NCSP where the duration, extent, characteristics, and outcome variables of impaired systemic circulation can be determined exactly. According to our results the presented experimental model can be used to study the acute pathophysiological consequences of low cardiac output states. Moreover, it may well reflect the signs of cardiogenic shock during NCSP. In addition, this pericardial tamponade setup can be useful for the practical training of surgical residents for the real-life demonstration and management of pericardiocentesis or emergency thoracotomy.

Increased pressure in the pericardium effects the low-pressure areas, like the superior and inferior caval veins and the right

atrium. During the heart cycle, tension changes dynamically inside the atria and ventricles, thus the pericardial pressure blocks the right atrial inflow and consecutively the right ventricular diastolic filling. The high venous pressure leads to the distension of the jugular veins (Kussmaul-sign) the cardiac sounds are "muffled." In addition, the peripheral pulse cannot be palpated while cardiac auscultation detects heartbeats, this is referred as *pulsus paradoxus*. The ECG signs reveal the lower amplitude of R waves due to the increased resistance of intra-pericardial liquids (5, 10). The development of cardiogenic shock activates numerous compensation mechanisms to maintain the perfusion pressure to the vital organs. Besides the enhanced contractility, the heart rate is increased to maintain CO. Additionally, the body redistributes the circulating volume by systemic and local vasoactive responses, including the remarkable vasoconstriction of the muscle-, skin-, and mesenteric vessels (5, 10-12).

The decreasing diuresis could be the first sign of accumulating pericardial fluid and thriving pericardial tamponade on cardiac surgical ICU. In our experiments, the renal blood flow remained significantly depressed despite the resolving CO. The deteriorating renal function is a challenging problem in clinical practice, thus our porcine model could be an important tool for studies aiming to study the improvement of renal function.

#### CONCLUSION

Our model using anesthetized mini pigs reflects the local and systemic hemodynamic and inflammatory changes of the clinical picture correctly. In the absence of thoracotomy, the surgical procedure is relatively easy and fast while at the same time the experimental setup allows for extensive hemodynamic monitoring, tissue biopsies, and biochemical measurements. We tried to make the model as realistic as possible, thus the animal's own blood is used to fill the pericardium. Leakage of blood was not detected and therefore the amount of intra-pericardial fluid could be standardized. The MAP level can be precisely controlled and the pressure response can be exactly modified throughout the experiments. Another advantage is that there is no explicit need for mechanical ventilation, and the lack of thoracotomy allows for longer duration or even chronic experiments with prolonged data collection. Besides, the transphrenic thoracal approach is definitely less stressful (refinement), and considering that the reduced invasiveness enables a reduction in animal numbers, this new model facilitates the adherence to the 3R principles as well.

---

**Ethics Committee Approval:** Ethics committee approval was received for this study from the Ethics Committee of Szeged University (V/148/2013).

**Informed Consent:** N/A.

**Peer-review:** Externally peer-reviewed.

**Author Contributions:** Concept - G.B., D.É., M.B., G.V.; Design - B.G., S.S., É.D., G.V.; Supervision - M.B. Resource - M.B., G.V.; Materials - B.G., S.S., É.D., G.V.; Data Collection and/or Processing - B.G., S.S., É.D., G.V.; Analysis and/or Interpretation B.G., S.S., É.D., G.V.; Literature Search - B.G., S.S., É.D., G.V.; Writing Manuscript - G.B., G.V.; Critical Reviews - D.É., M.B.

**Acknowledgments** The authors are grateful to Ágnes Fekete, Csilla Mester, Nikolett Beretka, Éva Nagyiván, Károly Tóth, and Péter Sárkány for their skillful assistance.

**Conflict of Interest:** The authors have no conflicts of interest to declare.

**Financial Disclosure:** This study was funded by Hungarian National Research, Development and Innovation Office NKFIH-K120232 and NKFIH-K116861 and GINOP-2.3.2-15-2016-00015 grants.

## References

1. Moore FD. The university in American surgery. *Surgery* 1958; 44: 1-10.
2. Osuchowski MF, Remick DG, Lederer JA, Lang CH, Aasen AO, Aibiki M, et al. Abandon the Mouse Research Ship? Not Just Yet!. *Shock* 2014; 41: 463-475. [\[CrossRef\]](#)
3. Orbach A, Schliamser JE, Flugelman MY, Zafrir B. Contemporary evaluation of the causes of cardiac tamponade: Acute and long-term outcomes. *Cardiol J* 2016; 23: 57-63. [\[CrossRef\]](#)
4. Bodson L, Bouferrache K, Vieillard-Baron A. Cardiac tamponade: *Curr Opin Crit Care* 2011; 17: 416-424. [\[CrossRef\]](#)
5. Carmona P, Mateo E, Casanovas I, Peña JJ, Llagunes J, Aguar F, et al. Management of Cardiac Tamponade After Cardiac Surgery. *J Cardiothorac Vasc Anesth* 2012; 26: 302-311. [\[CrossRef\]](#)
6. Rivera-Nieves J, Gorfu G, Ley K. Leukocyte adhesion molecules in animal models of inflammatory bowel disease. *Inflamm Bowel Dis* 2008; 14: 1715-1735. [\[CrossRef\]](#)
7. Kaszaki J, Nagy S, Tárnoky K, Laczi F, Vecsernyés M, Boros M. Humoral changes in shock induced by cardiac tamponade. *Circ Shock* 1989; 29: 143-153.
8. Kovács T, Varga G, Erces D, Tóké T, Tiszlavicz L, Ghyczy M, et al. Dietary Phosphatidylcholine Supplementation Attenuates Inflammatory Mucosal Damage in a Rat Model of Experimental Colitis. *Shock* 2012; 38: 177-185. [\[CrossRef\]](#)
9. Érces D, Nógrády M, Nagy E, Varga G, Vass A, Süveges G, et al. Complement C5A Antagonist Treatment Improves the Acute Circulatory and Inflammatory Consequences of Experimental Cardiac Tamponade. *Crit Care Med* 2013; 41: e344-e351. [\[CrossRef\]](#)
10. Spodick DH. Acute cardiac tamponade. *N Engl J Med* 2003; 349: 684-690. [\[CrossRef\]](#)
11. Ashikhmina EA, Schaff HV, Sinak LJ, Li Z, Dearani JA, Suri RM, et al. Pericardial Effusion After Cardiac Surgery: Risk Factors, Patient Profiles, and Contemporary Management. *Ann Thorac Surg* 2010; 89: 112-118. [\[CrossRef\]](#)
12. Kuvín JT, Harati NA, Pandian NG, Bojar RM, Khabbaz KR. Postoperative cardiac tamponade in the modern surgical era. *Ann Thorac Surg* 2002; 74: 1148-1153. [\[CrossRef\]](#)