






Endoscopic parathyroidectomy via unilateral axillobreast approach

Burhan Mayir¹ , Kutbettin Altun² , Mehmet Sercan Ertürk³ , Cemal Özben Ensari¹ 

¹ Clinic of General Surgery, Antalya Training and Research Hospital, Antalya, Turkey

² Clinic of General Surgery, Private Olimpos Hospital, Antalya, Turkey

³ Clinic of Endocrinology, Antalya Training and Research Hospital, Antalya, Turkey

ABSTRACT

Endoscopic parathyroid and thyroid surgery is becoming increasingly common. In this study, we present the results of patients who underwent Endoscopic parathyroid via unilateral axillo-breast approach (EP via UABA). Three patients underwent EP via UABA. Patients were discharged on the next day after surgery, while at one month follow up all of them reported no further symptoms. Operation performed via two axillar and one areolar trochar. As different from open surgery, the strap muscles don't pulled laterally and not entered into the thyroid lobe from the midline. In this technique, the strap muscles are separated from the middle part of the strap muscles and the thyroid gland is reached from the middle of the strap muscles. In this way, N. laryngeal recurrence and parathyroid gland that usually located in the posterior aspect of the thyroid gland can be revealed clearly by reducing the risk of complications. EP via UABA can be performed safe effective procedure via good cosmetic results.

Keywords: Endoscopic parathyroidectomy, endoscopic surgery, parathyroidectomy

INTRODUCTION

Primary hyperparathyroidism (PHPT) is a common endocrine disorder associated with elevated levels of serum calcium due to oversecretion of parathormone. 75%-85% of all cases are single adenomas; the remaining cases consist of multiple adenomas, hyperplastic glands, and carcinomas (1).

Bilateral neck exploration was a standart method of PHPT surgery in the past. Today, minimally invasive parathyroidectomy (MIP) has become the standard method with the use of high-resolution neck ultrasonography (US) and 99mTc-SestaMIBI scintigraphy (MIBI scan) (2). In addition to US and MIBI scan, some methods such as intraoperative rapid parathormone determination, radioguided surgery are used to increase the success of surgery in minimally invasive parathyroidectomy (3-5). Many studies have reported that MIP provides reduced operation time, length of stay and hospital costs (6). Furthermore, these studies showed that the MIP had fewer cases of permanent hypocalcemia with succesfully treatment results (95%) similar to bilateral neck exploration (7).

In past three decades, minimal access and minimally invasive techniques have become routine practice in abdominal and gynaecological surgeries. At the beginning of the 21. century, minimally invasive endoscopic techniques have been attempted in different subspecialties. Similarly, thyroid and parathyroid diseases were not excluded from these approaches.

In our country, endoscopic thyroid and parathyroid surgery has been applied in some surgical clinics. In this respect, we started to perform endoscopic thyroid and parathyroid surgery in our clinic. In this study, we presented patients who underwent endoscopic parathyroidectomy (EP) via unilateral axillobreast approach (UABA) in our clinic for parathyroid adenoma.

CASES

Patients with a history of neck surgery or neck radiotherapy, patients with multiple adenomas compatible with surgical imaging methods, patients with ectopic

Cite this article as: Mayir B, Altun K, Ertürk MS, Ensari CÖ. Endoscopic parathyroidectomy via unilateral axillobreast approach. Turk J Surg 2021; 37 (2): 188-192.

Corresponding Author

Burhan Mayir

E-mail: burmay@yahoo.com

Received: 02.03.2020

Accepted: 24.04.2020

Available Online Date: 30.06.2021

© Copyright 2021 by Turkish Surgical Society Available online at www.turkjsurg.com

DOI: 10.5152/turkjsurg.2021.4755

parathyroid adenoma, patients with concomitant thyroid nodules, and patients who did not accept this surgical approach were not considered appropriate for EP via UABA. Except for the patients with this feature, patients who were compatible with parathyroid adenoma in the same localizations on both neck ultrasound and Tc-99m MIBI parathyroid scintigraphy were found suitable for e EP via UABA.

Three patients underwent EP via UABA. Two patients were female and one was male. The patients age were 24-67 (mean: 47.3). Preoperative blood calcium levels were 10.9-11.9 (mean: 11.5) mg/dl and parathormone levels were 99-548 (mean: 250) ng/dl preoperatively. Neck ultrasonography of these patients revealed parathyroid adenoma with a diameter of 9-30 (mean: 18) mm and located in the lower part of left thyroid lobe. Tc-99m MIBI parathyroid scintigraphy showed increased activity uptake at the same locations in all patients. All operations were completed endoscopically. The operations time was calculat-

ed as 140-150 (mean 147 min). In all patients, N. laryngeus recurrences were seen and preserved. We did not need to use intraoperative neural monitoring in any patient.

Drains were removed in all patients one day after surgery. It was seen that blood calcium levels decreased below normal levels and parathormone levels returned to normal levels in three patients on the first postoperative day. There was no unpleasant cosmetic appearance in the neck on the first postoperative day in patients (Figure 1). Patients were discharged on the next day after surgery, while at one month follow up all of them reported no further symptoms. Histopathological examination of the parathyroid glands revealed as parathyroid adenoma.

Surgical Technique

General inhalational anaesthesia was utilised with orotracheal intubation. Patients were placed in a supine position. The neck was slightly extended (Figure 2). A 10 mm incision was made

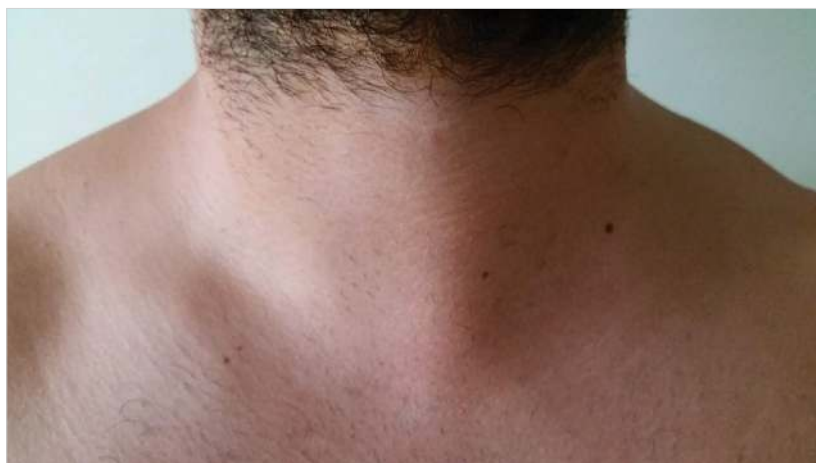

Figure 1. View of patient's neck one day after surgery.

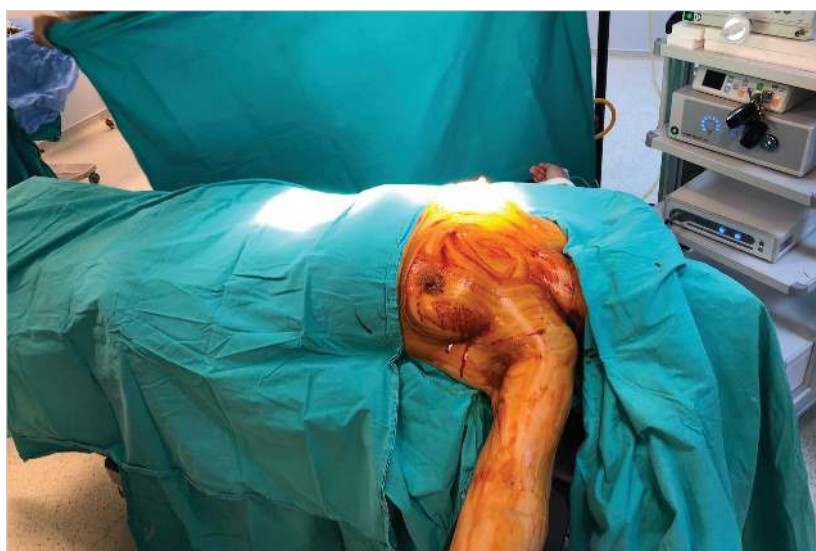

Figure 2. Patient's position on the operating table.

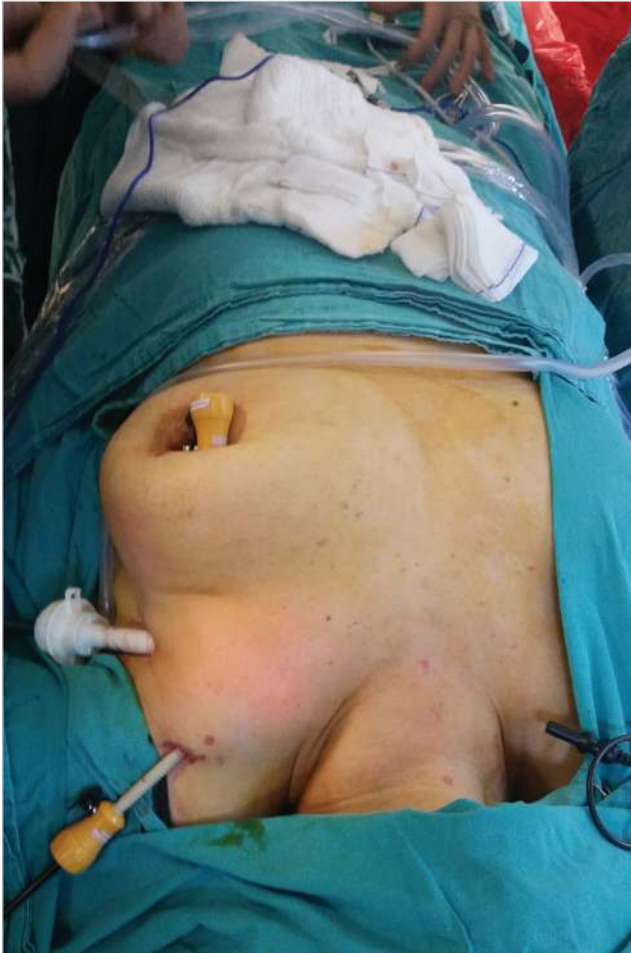

Figure 3. Trochar positions.

from the axillary region on the side where the parathyroid adenoma was detected. Trocar and camera were entered through this incision. 6 mm CO₂ insufflation was performed. 5 mm incision were made 3-4 cm above the 10 mm trocar incision and 5 mm incision were made around the breast areola on the same

side. Under the camera vision, 5 mm trocars was inserted from these incisions. (Figure 3).

No fluid or any drug injections were performed under the skin prior to flap dissection. Flap dissection was advanced from axilla to sternal notch. Than flap dissection was continued from the sternal notch to the thyroid cartilage. Thyroid strap muscles were found between the trachea and the sternocleidomastoid muscle and below the omohyoid muscle. Than strap muscles were opened parallel to the trachea with a cautery. The thyroid gland was reached through the strap muscles. The thyroid gland was separated from the muscle with blunt dissection and vascular sealing device and than lifted upwards. At this stage n. laryngeus recurrence was searched (Figure 4). Neural monitoring was not used routinely. According to preoperative imaging methods, parathyroid adenomas were found and removed. The parathyroid specimen was removed from the 10 mm trocar region in the endobag. The excised parathyroid specimen was sent for frozen section histopathological examination. After the histopathological examination confirmed the parathyroid gland, the trocars were removed following bleeding control. A hemovac was placed in the 10 mm trocar region and the operation was terminated.

DISCUSSION

In the majority of the 20. century, a traditional approach for parathyroid exploration was done with a horizontal neck incision. The first EP was reported in 1996 by Gagner (8). Subsequently, in 1997, Husher reported the first endoscopic thyroidectomy (ET) (9). Increasing experience, gaining confidence among endocrine surgeons, and the presence of complex endoscopic equipment contributed to accelerating endoscopic thyroid and parathyroid surgery. However, this progress was more pronounced in ET than in EP. Probably, commonality of thyroid disease and more experience in open thyroid surgery compared to the less common PHPT are the most important factors for the stagnant evolution of EP. Another reason for this

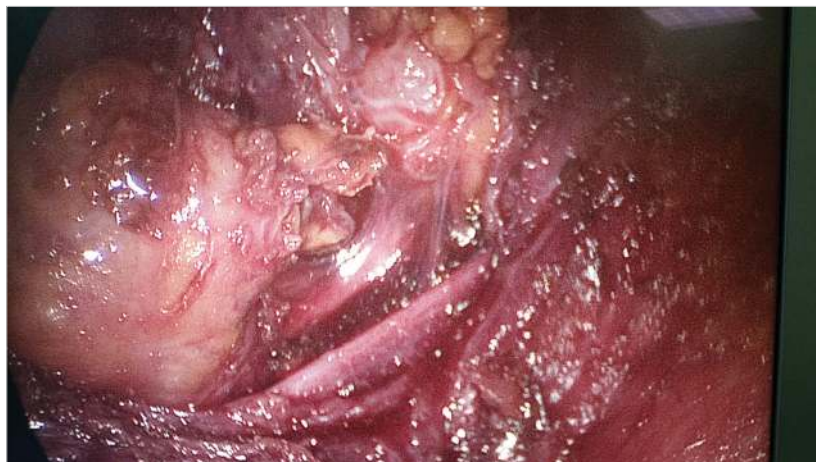

Figure 4. View of N. laryngeus recurrence.

trend is that parathyroidectomy for solitary adenoma usually requires a small 2-3 cm incision compared to open thyroidectomy which requires a 6-10 cm incision.

Today, many EP and ET techniques have been reported. Fully endoscopic, video-assisted, robotic, transaxillary, chest wall, thoracoscopic, post-auricular, and lateral neck routes have been already attempted (10). Although none of them are universally confirmed, endoscopic parathyroid and thyroid surgery is becoming increasingly common. The goals of any ET and EP techniques are the cure with best cosmesis and low morbidity.

In this study, we present the results of patients who underwent EP via UABA. When the results were examined, it was seen that good cosmetic results, which are the most important expectations of endoscopic parathyroid surgery, were achieved. No complications were observed in any patient. In this study, the mean operation time was 147 minutes. This time seems to be long for open minimally invasive parathyroidectomy. Nuyeng et al reported that they completed thyroid lobectomy in 50 minutes by EP via UABA and operation time is same as open surgery (11). We think that operation time will be shorten as our experience increases. It is considered that after the learning curve phase, the operative times for EP via UABA will be comparable to open surgery

When compared with minimally invasive parathyroidectomy than can performe with 2-3 cm incision made with local anesthesia, it is accepted that there are disadvantages of EP via UABA such as requiring general anesthesia, requiring a total incision of 4 cm, and long operation time. The most important aspect of EP via UABA technique is that the incision made to axilla and areola, so there is no visible scar at the end of the operation and it shows a cosmetically superior result. Although the incision in the neck at the MIP is small, the scar on the neck is not considered to be cosmetic.

This technique is different from the conventional method. In this technique, as in the conventional technique, the strap muscles don't pulled laterally and not entered into the thyroid lobe from the midline. In this technique, the strap muscles are separated from the middle part of the strap muscles and the thyroid gland is reached from the middle of the strap muscles. In this way, n. laryngeal recurrence and parathyroid gland that usually located in the posterior aspect of the thyroid gland can be revealed clearly by reducing the risk of complications. Therefore, we did not need to use intraoperative neural monitoring in any patient.

Currently, the transoral vestibular approach has become very popular in endoscopic thyroid-parathyroid surgery. It has been shown that thyroidectomy and parathyroidectomy can be performed safely via this technique (12-14). Although there is no comparative study, we think that the EP via UABA have some advantages over the transoral endoscopic parathyroidectomy

vestibular approach (TOEPVA). Firstly, in TOEPVA method, some technical difficulties may arise because the trocars are very close to each other (15). This problem does not exist during endoscopic parathyroidectomy in the axillo-breast approach. Trocars can be inserted at desired distance intervals according to the patient. Secondly, if a second surgical intervention is required for thyroid or parathyroid glands after TOETPA, the second surgical approach cannot be performed endoscopically again. However, since the axillo-breast approach is performed only from the diseased side, a second surgical procedure could be performed on the opposite side via the axillo-breast approach. Thirdly, in EP via UABA, there are no risks such as mental nerve injury and infection that may occur in TOEPVA surgery.

It is demonstrated that EP via UABA for the first time in our country can be performed safely via good cosmetic results. In our country, there is increasing interest in endoscopic thyroid-parathyroid surgery in parallel via the developments in the world. Our study will further encourage surgeons to perform ET and EP. The publication of similar results in patients who underwent thyroidectomy will further demonstrate the efficacy and safety of this technique. It is demonstrated that EP via UABA for the first time in our country can be performed safely via good cosmetic results. can be recommended to patients who require parathyroidectomy and who have better cosmetic expectations than open surgery.

Ethics Committee Approval: The approval for this study was obtained from Health Sciences University Antalya Training and Research Hospital Clinical Research Ethics Committee (Decision No: 26/12, Date: 12.12.2019).

Informed Consent: Informed consents were obtained from patients.

Peer-review: Externally peer-reviewed.

Author Contributions: Concept - B.M., K.A.; Design - B.M., K.A.; Supervision - B.M., K.A.; Materials - B.M., M.S.E.; Data Collection and/or Processing - All of authors; Analysis and/or Interpretation - B.M., C.Ö.E.; Literature Search - B.M.; Writing Manuscript - B.M.; Critical Reviews - All of authors.

Conflict of Interest: No conflict of interest was declared by the authors.

Financial Disclosure: The authors declared that this study has received no financial support.

REFERENCES

1. Madkhali T, Alhfezhi A, Chen H, Eifenbein D. Primary hyperparathyroidism. *Ulus Cerrahi Derg* 2016; 32(1): 58-66. [\[CrossRef\]](#)
2. Arıcı C, Mayir B, Altunbas HA, Boz A, Sari R, Karayalcin B, et al. Primer hiperparatiroidizmde lokalizasyon yöntemleri ve tedavi. *Journal of Dialog in Endocrinology* 2005; 2: 225-30. [\[CrossRef\]](#)
3. Mayir B. Hiperparatiroidi cerrahisinde hangi intraoperatif hızlı parathormon ölçüm kriteri kullanılmalıdır? *Journal of Dialog in Endocrinology* 2012; 9: 27-30. [\[CrossRef\]](#)
4. Rudin AV, McKenzie TJ, Thompson GB, Farley DR, Lyden ML. Evaluation of parathyroid glands with indocyanine green fluorescence angiography after thyroidectomy. *World J Surg* 2019; 43: 1538-43. [\[CrossRef\]](#)

5. Desiato V, Melis M, Amato B, Bianco T, Rocca A, Amato M, et al. Minimally invasive radioguided parathyroid surgery: a literature review. *Int J Surg* 2016; 28(Suppl 1): S84-93. [\[CrossRef\]](#)
6. Soyder A, Ünübol M, Ömürlü İK, Güney E, Özbaş S. Minimally invasive parathyroidectomy without using intraoperative parathyroid hormone monitoring or gamma probe. *Ulus Cerrahi Derg* 2015; 31(1): 9-14. [\[CrossRef\]](#)
7. Urkan M, Peker YS, Ozturk E. Minimally invasive parathyroidectomy for primary hyperparathyroidism. *Acta Endocrinol (Buchar)* 2019; 15(2): 182-6. [\[CrossRef\]](#)
8. Gagner M. Endoscopic subtotal parathyroidectomy in patients with primary hyperparathyroidism. *Br J Surg* 1996; 83(6): 875. [\[CrossRef\]](#)
9. Hüscher CS, Chiodini S, Napolitano C, Recher A. Endoscopic right thyroid lobectomy. *Surg Endosc* 1997; 11(8): 877. [\[CrossRef\]](#)
10. Ozdenkaya Y, Ersavas C, Arslan NC. Robotic transoral vestibular parathyroidectomy: two case reports and review of literature. *World J Clin Cases* 2018; 6(12): 542-7. [\[CrossRef\]](#)
11. Nguyen XH, Nguyen XH, Mai TKN, Nguyen TTN, Tran NL, Le VQ. Feasibility and safety of endoscopic thyroidectomy via a unilateral axillo-breast approach for unilateral benign thyroid tumor in Vietnam. *Surg Laparosc Endosc Percutan Tech* 2019; 29(6): 447-50. [\[CrossRef\]](#)
12. Hurtado-López LM, Gutiérrez-Román SH, Basurto-Kuba E, Luna-Ortiz K. Endoscopic transoral parathyroidectomy: initial experience. *Head Neck* 2019; 41(9): 3334-7. [\[CrossRef\]](#)
13. Pérez-Soto RH, Ponce de León-Ballesteros G, Montalvo-Hernández J, Sierra-Salazar M, Pantoja Millán JP, Herrera-Hernández MF, et al. Transoral endoscopic thyroidectomy by vestibular approach-initial experience and comparative analysis in the first reported Mexican cohort. *J Laparoendosc Adv Surg Tech A* 2019; 29(12): 1526-31. [\[CrossRef\]](#)
14. Sasanakietkul T, Jitpratoom P, Anuwong A. Transoral endoscopic parathyroidectomy vestibular approach: a novel scarless parathyroid surgery. *Surg Endosc* 2017; 31(9): 3755-63. [\[CrossRef\]](#)
15. Zhang D, Park D, Sun H, Anuwong A, Tufano R, Kim HY, et al. Indications, benefits and risks of transoral thyroidectomy. *Best Pract Res Clin Endocrinol Metab* 2019; 33(4): 101280. [\[CrossRef\]](#)



CERRAHİ TEKNİK-ÖZET

Turk J Surg 2021; 37 (2): 188-192

Aksilla meme yaklaşımı ile endoskopik paratiroidektomi

Burhan Mayır¹, Kutbettin Altun², Mehmet Sercan Ertürk³, Cemal Özben Ensari¹

¹ Antalya Eğitim ve Araştırma Hastanesi, Genel Cerrahi Kliniği, Antalya, Türkiye

² Özel Olimpos Hastanesi, Genel Cerrahi Kliniği, Antalya, Türkiye

³ Antalya Eğitim ve Araştırma Hastanesi, Endokrinoloji Kliniği, Antalya, Türkiye

ÖZET

Endoskopik paratiroid ve tiroid cerrahisi giderek yaygınlaşmaktadır. Bu çalışmada aksilla meme yolu ile endoskopik paratiroidektomi tekniği ve bu hastalara ait sonuçları sunmayı amaçladık. Üç hasta bu teknik ile ameliyat edildi. tüm hastalar ameliyattan sonraki gün taburcu edildi. Birinci ay kontrollerinde hastalarda parathormon ve kalsiyum düzeyleri normal idi. Ameliyat aksiller bölgeden iki ve meme başından bir trokar girilerek yapıldı. açık cerrahiden farklı olarak strap kasları laterale ayrıldı ve tiroid lojuna orta hattan ulaşılmadı. Bu teknikte strap kasları orta kısımdan ayrılarak tiroid lojuna lateralden girildi. Böylece tiroid bezinin arka kısmında yer alan N. larengeus rekürrens ve paratiroid bezleri kolaylıkla gözlemlenebilir ve komplikasyon riski azaltılabilir. Aksilla meme yolu ile endoskopik paratiroidektomi güvenli efektif ve kozmetik açıdan çok iyi sonuçlara sahip bir tekniktir.

Anahtar Kelimeler: Endoskopik paratiroidektomi, endoskopik cerrahi, paratiroidektomi

DOI: 10.47717/turkjsurg.2021.4755