



# Laparoscopic liver right posterior sectionectomies; surgical technique and clinical results of a single surgeon experience

Muharrem Öztaş<sup>1</sup> , Emin Lapsekili<sup>1</sup> , Mehmet Fatih Can<sup>2</sup> 

<sup>1</sup> Department of of General Surgery, Gülhane Training and Research Hospital, University of Health Sciences, Ankara, Turkey

<sup>2</sup> Department of General Surgery, Lokman Hekim University Faculty of Medicine, Ankara, Turkey

## ABSTRACT

**Objective:** Laparoscopic liver resections have been performed with increasing frequency in recent years. With increasing surgical experience and technological developments, more complex laparoscopic liver resections can now be applied. Laparoscopic right posterior sectionectomy (LSPS) requires a sophisticated and highly challenging surgical technique due to the length of the parenchyma transection line and the camera out of view in laparoscopic surgery. The aim of this study was to share tips and tricks about resection which will contribute to the operation time and technique.

**Material and Methods:** Evaluation was made of the laparoscopic major liver resections performed consecutively between 2015-2020 in our center. During the resections, three different inflow control techniques were used; hilar, glasssonian and intraparenchymal approach.

**Results:** A total of 14 LSPS surgeries were performed. Mean age of the patients was  $51.6 \pm 10.2$  years (34-68), and mean operation time was  $300 \pm 58$  (200-440) minutes. The Pringle maneuver was applied to all patients, with a mean time of  $58.4 \pm 14.4$  (30-75) minutes. Mean perioperative bleeding was measured as  $290 \pm 105$  (140-550) mL. Additional surgery was performed on six patients in the same session. Complications occurred in three patients. No perioperative mortality was observed.

**Conclusion:** LSPS is a technically difficult process, which requires advanced skills in both liver surgery and laparoscopic surgery. Surgeons should consider applying this method, which offers different advantages depending on the location and nature of the lesion, after completing the learning curve by performing laparoscopic liver surgery of the correct number and type. In our article, we stated the tips and tricks that make it easy to perform laparoscopic right posterior sectionectomies, which have been thought to be difficult until recently and these difficulties have been clearly stated in many articles.

**Keywords:** Hepatobiliary surgery, laparoscopic, liver resection, right posterior, sectionectomy, techniques

## INTRODUCTION

Laparoscopic liver surgery has made rapid progress in recent years in parallel with positive developments in terms of feasibility, safety and oncological efficacy (1,2). Compared with the open approach, laparoscopic liver surgery offers lower complication rates, reduced intraoperative blood loss, and shorter hospital stay (3,4). However, laparoscopic major and complex resections are performed in a small number of centers worldwide due to doubts about the reported advantages of performing major resections, oncological surgical margin safety and technical complexities.

The majority of early studies report data from case-control series, and although there have been some recent multicenter good quality comparative studies (5), randomized controlled trials have not been conducted to provide definitive answers. Traditionally, resections involving only one or two Couinaud segments are classified as minor resections, while resections involving three or more segments are called major resections (6). However, given the technical complexity of posterosuperior segment resections (segments 4a, 7, and 8), these have been technically classified as major resections to distinguish them from minor resections, and it has been proposed that their difficulties should be acknowledged (7). The technical complexity of this major resection is due to the limited access and difficulty in exposing the posterosuperior part of the liver, which is close to the diaphragm and vena cava inferior (8). Right posterior sectionectomy (RPS) is scored as 9 or 10 points, according to the difficulty scoring system derived by Ban et al. (9) for

**Cite this article as:** Öztaş M, Lapsekili E, Can MF. Laparoscopic liver right posterior sectionectomies; surgical technique and clinical results of a single surgeon experience. Turk J Surg 2022; 38 (1): 18-24.

### Corresponding Author

Emin Lapsekili

E-mail: lapsekilemin@yahoo.com

Received: 30.12.2021

Accepted: 28.01.2022

Available Online Date: 28.03.2022

© Copyright 2022 by Turkish Surgical Society Available online at [www.turkjsurg.com](http://www.turkjsurg.com)

DOI: 10.47717/turkjsurg.2022.5623

laparoscopic liver surgery, and it is considered one of the most complex procedures (for example, laparoscopic right hemihepatectomy is scored as 7).

Difficult access to segment 7, the potential for a close relationship between the lesion and the right hepatic vein, the fact that the right posterior section is not separated by a clear anatomic structure, the requirement for complex inflow control and the need for a wide resection line significantly complicate the procedure.

In our center, laparoscopic liver resection operations were started in 2013. After completing the learning curve and with increasing experience and technological advances, we began to routinely perform laparoscopic, complex and major liver resections, including laparoscopic right posterior sectionectomy. The aim of this article was to share our experiences with this difficult procedure, as well as tips, tricks and outcomes that we think may be useful.

## MATERIAL and METHODS

Our study was approved by the local ethics committee's decision dated 29.09.2021 and numbered 2021/70. The study included 14 patients with indication for right posterior sectionectomy and who underwent consecutive LSPS operation between 2015-2020. LSPS was applied in cases with multiple lesions in segments 6 and 7, large lesions involving both seg-

ments and cases where segmental or parenchymal sparing resections could not be performed (such as central lesions involving both segments). The most common indication was liver metastasis with colorectal cancer in 6 patients. Three of the patients were operated on for HCC, 1 for KCC, 2 for symptomatic hemangioma, and 2 for hepatic adenoma.

The operation was planned with a multidisciplinary approach, preoperative evaluation with CT, MRI and other necessary imaging techniques, for all patients. The patients were examined in terms of surgery type, operation time, blood loss, rate of conversion to open surgery, resection margins, morbidity, mortality, Pringle maneuver time and number, postoperative hospital stay and whether additional surgery was performed in the same session. Demographic characteristics of the patients and other data regarding the operation are shown in Table 1.

## Surgical Technique

The inflow control approach in LSPS surgery was carried out using one of the following methods:

### 1. Inflow Control with Hilar Dissection

Inflow control was provided by hilar dissection and dissection of RPS vessels. In this technique, transection is guided by the demarcation line and intraoperative ultrasonography (IOUS). This technique was used in 6 patients (41.6%).

**Table 1.** Demographic characteristics of the patients and operational data

Patient	Age (years)	Sex	Diagnosis	Operation	Inflow control method	Operation time (min)	Pringle time (min)	Blood loss (mL)	Complications	Length of stay (days)
1	44	Male	Hemangioma	Lap.	Hilar	310	45	350	-	6
2	34	Female	Adenoma	HA	Hilar	270	30	200	-	6
3	49	Male	CRLM	HA	Parenchymal	280	N/A	550	Wound infection	11
4	50	Male	CRLM	Lap	Hilar	340	60	280	-	13
5	60	Male	CCC	Lap	Hilar	330	60	380	-	7
6	43	Male	CRLM	Lap	Parenchymal	440	45	380	-	10
7	55	Male	CRLM	Lap.	Hilar	250	75	220	-	8
8	62	Female	HCC	Lap.	Glissonian	300	45	200	-	8
9	68	Female	HCC	Lap.	Parenchymal	290	70	340	Bile leakage + liver failure	12
10	40	Female	Hemangioma	Lap.	Parenchymal	240	60	250	-	7
11	55	Male	HCC	Lap.	Parenchymal	200	50	140	-	6
12	58	Male	CRLM	Lap.	Parenchymal	320	70	280	-	9
13	63	Male	CRLM	Lap.	Parenchymal	280	75	200	Liver failure	7
14	41	Female	Adenoma	Lap.	Hilar	360	75	300	-	4
Mean ± SD (min-max)	51.6 ± 10.2 (34-68)	-	-	-	-	300 ± 58 (200-440)	58.4 ± 14.4 (30-75)	290 ± 105 (140-550)	-	8.1 ± 2.5 (4-13)

CCC: Cholangiocellular carcinoma, CRLM: Colorectal cancer - liver metastasis, HA: Hand-assistant, HCC: Hepatocellular carcinoma, Lap: Laparoscopic, N/A: Not available.

In the hilar approach, the gallbladder and falciform ligament are suspended for convenient access to the hepatic pedicle, and the pedicle is reached by opening the hepatoduodenal ligament, over the hepatoduodenal ligament, conventionally. By following the main hepatic artery, the right hepatic artery is reached near the cystic duct and the dissection is advanced towards the right posterior pedicle. The portal branch, which runs just posterior to the artery, is identified with the same method and the demarcation line is controlled by clamping the pedicle with the help of a laparoscopic bulldog clamp after right posterior pedicle isolation. Confirmation that the right posterior pedicle was clamped is made with ultrasonography. Subsequently, pedicle transection is performed with the appropriate method (hem-o-lock clip or vascular stapler).

## 2. Inflow Control with Glissonian Approach

Inflow control is performed by dividing at the level of the Rouviere sulcus (RS), and resection is directed by the demarcation line and IOUS. This technique was used in one patient (8.4%). In the Glissonian approach, under the guidance of Rouviere's sulcus, hepatotomy is performed above or below the sulcus, and inflow control is achieved by exploring the right posterior pedicle. The parenchyma transection line is determined with the help of the demarcation line and ultrasonography after bulldog clamping. Subsequently, pedicle transection is performed with the appropriate method (hem-o-lock clip or vascular stapler). The Glissonian approach is considered to be more advantageous compared to the hilar approach in terms of reduced possibility of major (main portal vein and hepatic artery) injury and keeping the hilar region intact for future liver surgery that the patient may undergo. This approach allows for highly selective control of Glissonian pedicles without hilar or extensive parenchymal dissection. However, in cases where there is no Rouviere sulcus or the tumor is very close to or in contact with the posterior pedicle, it is necessary to perform resection with a hilar approach or an ultrasonography-guided parenchymal approach instead of the Glissonian approach.

## 3. Parenchymal Approach

In cases where the hilar approach or Glissonian approach is considered unsuitable, without any inflow control, intraoperative USG is used, and the resection line is placed 5-10 mm to the right of the right hepatic vein. After parenchymal transection, inflow control is achieved by exploring the right posterior pedicle and transecting the pedicle with an appropriate method (hem-o-lock clip or vascular stapler). This technique was used in 7 (50.0%) patients.

When patients are approached through the parenchyma, they are placed in the left lateral decubitus position. When the hilar approach or the Glissonian approach is adopted, the modified French position with a 15° reverse Trendelenburg and a left inclination of about 40° is placed in the transection stage. In our experience, we have seen the great benefit of the left lateral decubitus position for ligation and cutting of the short hepatic veins and transection of the hepatocaval ligament when the parenchymal approach is applied, while the modified French position provides better access to the hilum and the Rouvier sulcus.

At the beginning of the surgery, a 12 mm trocar is placed in the right upper quadrant to create a pneumoperitoneum (port I). Pneumoperitoneum is involved between 12 and 14 mmHg. One 10 mm trocar (port II) is placed approximately 4 cm below the point where the right anterior axillary line intersects the costal line. A 5 mm trocar (port III) is placed just below the xiphoid and a 10 mm working trocar is placed 5 cm right lateral to the umbilicus (port IV). A 5 mm port (port V) is placed 4 cm below where the left midclavicular line intersects the arcus costa and a 5 mm trocar is placed approximately 5 cm left lateral to the umbilicus (port VI). Patient positions and port entry areas are shown in Figure 1.

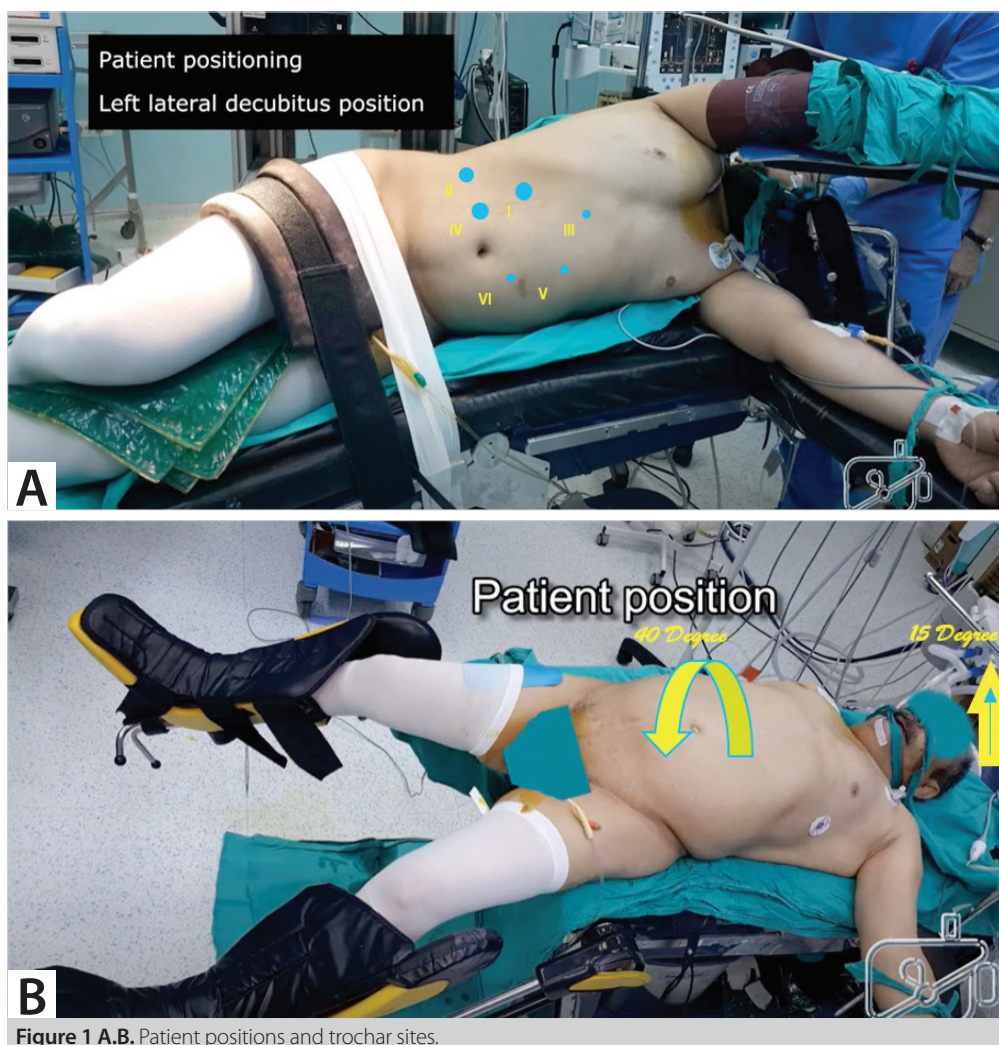
The camera, Cavitron ultrasonic surgical aspirator (CUSA), energy devices and laparoscopic clips were placed from ports I and II, alternately. To be able to view the transection line from the front and to avoid dissection tools obstructing the surgeon's view, vision was always provided with a 30° or 45° laparoscopic camera aligned with the transection plane. Port I was used as the working port for hilar dissection and port II was used during parenchyma dissection.

The third port was used for dissection of the hepatic artery and portal vein, division of the coronary ligament, retraction of the falciform ligament and elevation of the posterior surface of the right hemi-liver during dissection of the right triangular ligament. The fourth port was used for laparoscopic clips and laparoscopic linear stapler application. The fifth port was used for gallbladder retraction, dissection of the triangular ligament and allows the assistant to achieve suction, liver retraction, and elevation. The sixth port was used for the traction of the nelaton catheter used in the Pringle maneuver.

IOUS was used to define the relationship of the lesion to vascular structures and to mark the transection line. The Pringle maneuver was made by turning the nelaton catheter around the hepatoduodenal ligament and was controlled with the instrument inserted through the 5 mm port (Figure 2).

## Outflow Control

Right hepatic vein (RHV) dissection and suspension may be required to protect the right hepatic vein, control bleeding in



possible venous bleeding and resection safety for lesions very close to the RHV. In this case, the coronary and right triangular ligaments were opened and the right hepatic vein was suspended after the hepatocaval ligament was cut and outflow control was achieved.

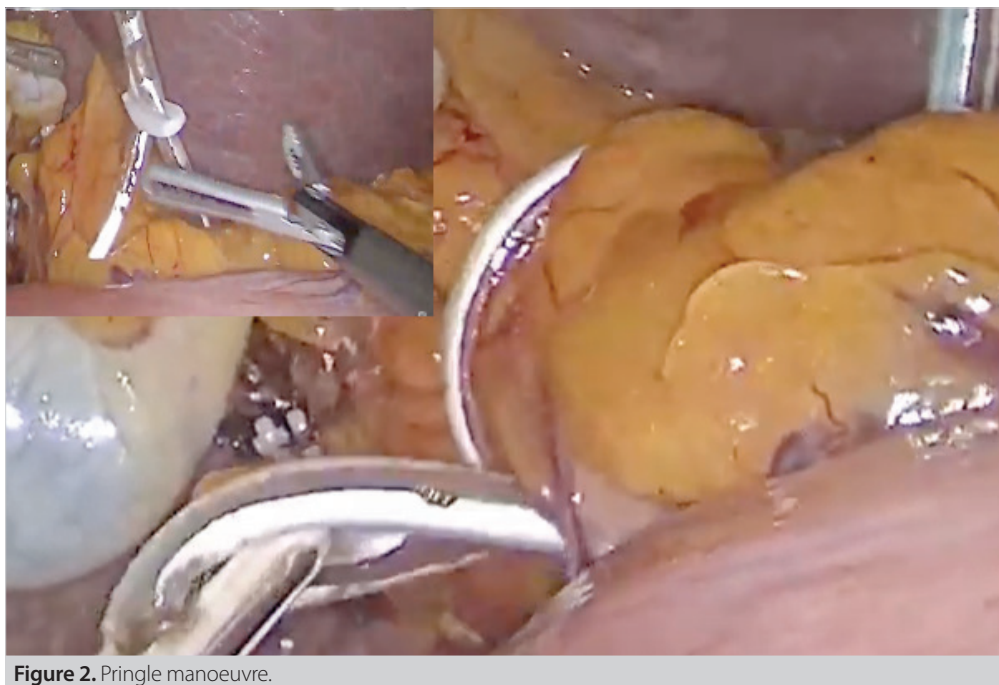
### Parenchymal Transection

Before parenchyma transection, it was attempted to obtain a good view by ensuring the mobilization of the right lobe of the liver over the vena cava and by ligating and cutting the short hepatic veins. Subsequently, laparoscopic ultrasonography was performed on all patients, and the location and borders of the tumor and its relationship with the right hepatic vein and vascular structures were determined. Parenchyma transection was started by marking the transection line with the help of cautery. The liver capsule and approximately 1-2 cm deep superficial, partially avascular layers were transected with Ultracision Harmonic Scalpel® or THUNDERBEAT®. During the parenchyma transection, it was tried to keep the central venous pressure

(CVP) low ( $\leq 5$  cmH<sub>2</sub>O) by coordinating with the anesthesia team. During transection, we generally did not use sutures for traction and preferred parenchymal traction with manual tools. We used laparoscopic CUSA for deep tissue transection and the hepatic artery, portal vein and small branches of the hepatic vein were cut and tied with titanium clips or tissue-vessel sealing devices. Structures thought to be bile ducts were necessarily clipped. A laparoscopic aspirator was used to keep the line dry during parenchyma transection.

### Hemostasis and Removing the Specimen

After the transection process was completed, the surface was checked for bleeding and bile leakage. Gas tampon was placed on the transection line and the presence of bile leakage was checked again, and the leak was closed using titanium clips, hem-o-lock clips or sutures, depending on the situation. Various bleeding control materials were used over time to control especially venous leakage type parenchymal bleeding (TachoSil®, FLOSEAL®, SURGICEL SNoW®, SURGICEL FIBRILLAR®). Recently,



**Figure 2.** Pringle manoeuvre.

permanent surface hemostasis has been routinely performed with SURGICEL SNoW®/SURGICEL FIBRILLAR. Usually, the specimen taken in the endo-bag was removed with a Pfannenstiel incision. In female patients, it was sometimes removed transvaginally, depending on the size of the specimen.

## RESULTS

Fourteen LSPS surgeries were performed in a five-year period. The patients comprised 9 males and 5 females with mean age of 51 years and mean BMI of 30 (22-38). An incision scar from previous open surgery was present in 6 patients, and 1 patient had a history of liver surgery. The procedure was hand-assisted in the first 2 patients in the series, while the others were performed purely laparoscopically. Additional surgery was performed in 7 patients (50%) in the same session. Colorectal surgery was performed in 3 patients, lymph node dissection in 1, secondary liver resection in 2, and colorectal surgery and RF application in one patient in the same session. Vascular inflow control was performed using the Glissonian approach in one patient, the parenchymal approach in 7 patients, and hilar approach in 6 patients. Portal vein embolization was not performed in any patient in the preoperative period. Resection surgery was performed in all patients in a single session. The ASA scores were 3 in 2 patients, and 1 or 2 in the other patients. Cirrhosis was present in 5 patients. While the child score of one patient with an ASA score of 3 was "B", the other patients' child score was "A". Three patients had lesions other than in the right posterior segment. RF was applied to one of these patients, and additional resection was performed laparoscopically in the others. The size of the major lesion was measured as mean 60 mm

(35-150 mm). The lesion was closer than 2 cm to the hilus in 2 patients and less than 2 cm to the hepatic veins in 5 patients. Resection was completed as R1 in one patient, while the others were completed as R0. The tumor of the patient who underwent R1 resection was located very close to the hepatic hilus. The resection margin of all patients who underwent R0 resection was >1 mm. The mean operative time was 300 minutes (200-440). The Pringle manoeuvre was applied to all patients, and the average Pringle time was determined as 58 minutes (30-75 minutes). Mean perioperative bleeding was measured as 290 ml (140-550 mL). Red blood cell suspension was required intraoperatively or postoperatively in only 5 patients. The length of stay in hospital was an average of 8 (4-13) days. Minor complications (Accordion grade I or II) developed in 3 patients, as stage 1 wound infection in 1, which was treated with dressing and appropriate antibiotics, and 2 patients had stage 2 bile leakage and liver failure. One of these patients was a patient with child B cirrhosis, and the findings that regressed with medical treatment and follow-up in the early period were not reflected in the long term. Grade A liver failure developed in the other patient, but the patient was discharged in seven days without any problems. No perioperative mortality was observed in the patients.

## DISCUSSION

Since the first laparoscopic liver resection was reported, data on more than 9000 laparoscopic liver resections have been published (1). Although laparoscopic liver surgery is more widely accepted, LSPS is considered a technically demanding procedure reserved for specialist liver surgeons with experience in advanced laparoscopic liver resections (6,10). Minimal

working space, the need to perform curvilinear-parenchymal transections and the difficulty in controlling bleeding from the branches of the major hepatic veins contribute to the technical complexity of the operation. In fact, right hepatectomy is an acceptable option for right posterior lesions. However, if the parenchymal approach is to be made with a protective technique, while resection performed by preserving the anterior sector decreases the chance of developing early-stage liver failure and decreases the morbidity rates, it increases the resectability capacity for other pathologies of the liver that may develop in the late period (11,12). Such parenchymal sparing procedures are more difficult than major resections, so major resections are more preferred. The reason that right posterior segment resection was preferred in this series of patients was that the major mass was located in segments 6-7. In 2 patients, a second resection was performed laparoscopically in one of the lesions located in other segments of the liver and RF ablation was performed in the other patient.

In a multi-center study evaluating 171 LSPS surgeries including the current study group (5), 4 of the 9 centers (44%) preferred inflow control with the parenchymal approach with IOUS more, 3 (33%) stated that they preferred hilar control, and 2 (22%) stated no specific preference. In the operations of the current series, the Glissonian approach (1/14), hilar approach (6/14) and parenchymal approach (7/14) with IOUS were preferred. Machado et al. have reported that the Glissonian approach is a reliable approach in their 7-year laparoscopic hepatectomy series involving 234 patients (13). In the current study, no significant difference was observed between the two methods most used for inflow control (hilar and parenchymal) in terms of operation time and intraoperative bleeding (mean 300 and 293 min, mean 288 and 306 mL, respectively). An average of 2 units of erythrocyte suspension replacement were required by five patients. In order to reduce the amount of intraoperative bleeding, the Pringle maneuver was applied in all surgeries as 15 minutes of clamping and 5 minutes of rest. The average Pringle time was measured as 58 minutes, which can be considered quite long compared to the average time of 33 minutes stated in the multicenter study (5). However, when it was determined that one Pringle more was applied on average in the current study. This excess does not affect either the amount of intraoperative bleeding or the morbidity rate observed in the postoperative period. At the same time, as previously stated, CVP was kept below 5 cm H<sub>2</sub>O, and venous bleeding was minimized by performing outflow control. In the Oslo-CoMet study, minimally invasive liver parenchymal sparing surgery for liver metastases of colorectal cancers has been reported to be associated with lower postoperative complications (14). The common denominator of postoperative complications was bile leakage. In the current study, minor bile leakage and mild liver failure devel-

oped in one patient. This patient was also being followed up for Child B cirrhosis. Accordion II wound site infection developed in one patient, and Grade A liver failure in one patient.

The aim of liver tumor surgery is R0 resection and if the surgical margin does not involve major vascular structures, a tumor-free parenchymal margin >1 mm is considered sufficient. In this study, R0 resection was achieved in 13 patients, and one patient had a microscopic tumor at the surgical margin in a location different from that of the tumor identified after postoperative pathology. According to the pathology results of this series, it can be seen that we also approached the R0 resection percentages of 95% as stated in the multicenter study (5). The results of this study, in which no 90-day mortality was observed, were similar to those of other studies.

## CONCLUSION

LSPS is a specialized surgery that requires advanced technique and skill in both liver surgery and laparoscopic surgery. Although the learning curve is considered to be longer and slower, the application of this method, which offers different advantages depending on the location and nature of the lesion, should be considered following the completion of the learning curve with the correct number and type of laparoscopic liver surgeries, especially in high-volume centers.

**Ethics Committee Approval:** The approval for this study was obtained from Gülhane Training and Research Hospital Ethics Committee (Decision no: 2021/70, Date: 29.09.2021).

**Peer-review:** Externally peer-reviewed.

**Author Contributions:** **Author Contributions:** Concept - All of authors; Design - All of authors; Supervision - M.F.C.; Materials - E.L., M.Ö.; Data Collection and/or Processing - E.L., M.Ö.; Analysis and/or Interpretation - E.L., M.Ö.; Literature Search - M.Ö., E.L.; Writing Manuscript - All of authors; Critical Reviews - M.F.C..

**Conflict of Interest:** The authors have no conflicts of interest to declare.

**Financial Disclosure:** The authors declared that this study has received no financial support.

## REFERENCES

1. Seehofer D, Sucher R, Schmelzle M, Öllinger R, Lederer A, Denecke T, et al. Evolution of laparoscopic liver surgery as standard procedure for HCC in cirrhosis? *Z Gastroenterol* 2017; 55(5): 453-60. <https://doi.org/10.1055/s-0043-100021>
2. Cipriani F, Rawashdeh M, Ahmed M, Armstrong T, Pearce NW, Abu Hilal M. Oncological outcomes of laparoscopic surgery of liver metastases: a single-centre experience. *Updates Surg* 2015; 67(2): 185-91. <https://doi.org/10.1007/s13304-015-0308-1>
3. Di Fabio F, Barkhatov L, Bonadio I, Dimovska E, Fretland ÅA, Pearce NW, et al. The impact of laparoscopic versus open colorectal cancer surgery on subsequent laparoscopic resection of liver metastases: A multicenter study. *Surgery* 2015; 157(6): 1046-54. <https://doi.org/10.1016/j.surg.2015.01.007>

4. Martínez Cecilia D, Cipriani F, Vishal S, Ratti F, Tranchart H, Barkhatov L, et al. Laparoscopic versus open liver resection for colorectal metastases in elderly and octogenarian patients: a multicenter propensity score based analysis of short- and long-term outcomes. *Ann Surg* 2017; 265(6): 1192-200. <https://doi.org/10.1097/SLA.0000000000002147>
5. Van der Heijde N, Ratti F, Aldrighetti L, Benedetti Cacciaguerra A, Can MF, D'Hondt M, et al. Laparoscopic versus open right posterior sectionectomy: an international, multicenter, propensity score-matched evaluation. *Surg Endosc* 2021; 35(11): 6139-49 <https://doi.org/10.1007/s00464-020-08109-y>
6. Teo JY, Kam JH, Chan CY, Goh BKP, Wong JS, Lee VTW. Laparoscopic liver resection for posterosuperior and anterolateral lesions-a comparison experience in an Asian centre. *Hepatobiliary Surg Nutr* 2015; 4: 379-90.
7. Di Fabio F, Samim M, Di Gioia P, Godeseth R, Pearce NW, Abu Hilal M. Laparoscopic major hepatectomies: clinical outcomes and classification. *World J Surg* 2014; 38: 3169-74. <https://doi.org/10.1007/s00268-014-2724-7>
8. Kaneko H, Takagi S, Shiba T. Laparoscopic partial hepatectomy and left lateral segmentectomy: technique and results of a clinical series. *Surgery* 1996; 120: 468-75. [https://doi.org/10.1016/S0039-6060\(96\)80065-1](https://doi.org/10.1016/S0039-6060(96)80065-1)
9. Ban D, Tanabe M, Ito H, Otsuka Y, Nitta H, Abe Y, et al. A novel difficulty scoring system for laparoscopic liver resection. *J Hepatobiliary Pancreat Sci* 2014; 21: 745-53. <https://doi.org/10.1002/jhpb.166>
10. Wakabayashi G, Cherqui D, Geller DA, Buell JF, Kaneko H, Han HS, et al. Recommendations for laparoscopic liver resection: a report from the second international consensus conference held in Morioka. *Ann Surg* 2015; 261: 619-29.
11. Cheng KC, Yeung YP, Ho KM, Chan FKM. Laparoscopic right posterior sectionectomy for malignant lesions: an anatomic approach. *J Laparoendosc Adv Surg Tech* 2015; 25: 646-50. <https://doi.org/10.1089/lap.2015.0166>
12. Nomi T, Fuks D, Kawaguchi Y, Mal F, Nakajima Y, Gayet B. Learning curve for laparoscopic major hepatectomy. *Br J Surg* 2015; 102: 796-804. <https://doi.org/10.1002/bjs.9798>
13. Machado MAC, Surjan RC, Basseres T, Schadde E, Costa FP, Makdissi FF. The laparoscopic Glissonian approach is safe and efficient when compared with standard laparoscopic liver resection: results of an observational study over 7 years. *Surgery* 2016; 160: 643-51. <https://doi.org/10.1016/j.surg.2016.01.017>
14. Fretland ÅA, Dagenborg VJ, Bjørnelv GMW, Kazaryan AM, Kristiansen R, Fagerland MW. Laparoscopic versus open resection for colorectal liver metastases. *Ann Surg* 2017; 267: 199-207. <https://doi.org/10.1097/SLA.0000000000002353>



### ORJİNAL ÇALIŞMA-ÖZET

Turk J Surg 2022; 38 (1): 18-24

## Laparoskopik karaciğer sağ arka kesitektomiler; tek cerrah deneyiminin cerrahi tekniği ve klinik sonuçları

Muharrem Öztaş<sup>1</sup>, Emin Lapsekili<sup>1</sup>, Mehmet Fatih Can<sup>2</sup>

<sup>1</sup> Sağlık Bilimleri Üniversitesi, Gülhane Eğitim ve Araştırma Hastanesi, Genel Cerrahi Anabilim Dalı, Ankara Türkiye

<sup>2</sup> Lokman Hekim Üniversitesi Tıp Fakültesi, Genel Cerrahi Anabilim Dalı, Ankara, Türkiye

### ÖZET

**Giriş ve Amaç:** Laparoskopik karaciğer rezeksiyonları, son yıllarda artan sıklıkla uygulanan ameliyatlardandır. Artan cerrahi deneyim ve teknolojik gelişmelerle birlikte giderek daha kompleks laparoskopik karaciğer rezeksiyonları uygulama alanı bulabilmektedir. Laparoskopik sağ posterior sektörektomi (LSPS), parankim transeksiyon hattının uzunluğu ve laparoskopik cerrahide kamera açısı dışında kalması nedeniyle sofistike ve yüksek zorluk derecesine sahip bir cerrahi teknik gerektirmektedir.

**Gereç ve Yöntem:** 2015-2019 yılları arasında ardışık olarak yapılan laparoskopik majör karaciğer rezeksiyonlarımızı değerlendirdik. Rezeksiyonlar esasında üç farklı inflow kontrol tekniği kullandık; intraparakimal, hiler ve glassonian yaklaşım.

**Bulgular:** Dört yılda 12 adet LSPS ameliyatı gerçekleştirildi. Hastaların ortalama yaşı 51'di, ortalama ameliyat süresi 290 (140-380) dakikaydı. Tüm hastalara pringle manevrası uygulandı, ortalama pringle süresi 55 (30-75) dakika olarak belirlendi. Ortalama perioperatif kanama 297 (140-550) ml ölçüldü. Hastaların yarısına (6 hasta) aynı seansta ek cerrahi işlem uygulandı. Ameliyatların tamamı laparoskopik olarak tamamlandı ve hastalarda perioperatif mortalite gözlenmedi.

**Sonuç:** LSPS uygulanabilir, verimli ve güvenlidir. Bununla birlikte, teknik olarak zor bir işlemdir ve hem karaciğer cerrahisi hem de laparoskopik cerrahide ileri beceriler gerektirir. Cerrahlar, öğrenim eğrisini doğru sayı ve türde laparoskopik karaciğer cerrahisi yaparak tamamlamalı ve lezyonun yeri ve doğasına bağlı olarak farklı avantajlar sunan bu yöntemi uygulamayı düşünmelidir.

**Anahtar Kelimeler:** Hepatobilier cerrahi, laparoskopik karaciğer rezeksiyonu, sağ posterior sektörektomi, teknik

**DOI:** 10.47717/turkjsurg.2022.5623