





# Coexisting of small bowel perforation and abdominal cocoon syndrome: A case report

Emrah Akın<sup>1</sup> , Fatih Altıntoprak<sup>1</sup> , Emre Gönüllü<sup>2</sup> , Fahri Yılmaz<sup>3</sup> , Yasin Alper Yıldız<sup>3</sup> 

<sup>1</sup> Department of General Surgery, Sakarya University Faculty of Medicine, Sakarya, Türkiye

<sup>2</sup> Department of General Surgery, Sakarya Training and Research Hospital, Sakarya, Türkiye

<sup>3</sup> Department of Pathology, Sakarya University Faculty of Medicine, Sakarya, Türkiye

## ABSTRACT

Abdominal cocoon syndrome (ACS) is a rare situation and has an unknown etiology. Patients are characterized by the development of intraabdominal fibrotic tissue surrounding the small intestine as a result of chronic inflammation of the peritoneum. Small bowel perforations due to foreign bodies are not frequent in clinical practice. The coexistence of these two rare situations are extremely uncommon. In this article, the radiological findings and treatment process of the patient who presented with acute abdomen syndrome findings and the association of these two rare conditions are presented.

**Keywords:** Abdominal cocoon syndrome, fishbone, perforation, intestinal obstruction

## INTRODUCTION

Abdominal cocoon syndrome (ACS) is a rare clinical condition that causes intestinal obstruction. Syndrome is also known, such as peritonitis chronica fibrosa incapsulata, sclerosing encapsulating peritonitis (1). Although the physiopatology described in 1908 as the development of fibrosis with chronic inflammation in the peritoneum and subsequently enclosure of small intestines by this tissue, which causes partial or complete intestinal obstruction, the syndrome defined in detail on a case in 1978 (2). ACS is defined in two forms as primary in which etiological factors cannot be determined and secondary form in which underlying etiological causes determined (previous abdominal surgery, peritonitis, tuberculosis, sarcoidosis, or peritoneal dialysis) (3). Clinical presents with small bowel obstruction findings (nausea, vomiting, abdominal distension, and the inability of defecation) in acute condition, but after careful questioning is done, it is typical that such attacks are repeated occasionally, albeit lighter over the years. Small bowel obstructions are frequent all over the world, and the most common cause is adhesions. Obstructions due to foreign bodies (such as bezoars) are less frequent situations (4). Small bowel perforation due to accidentally ingested foreign bodies during meals has been reported in the literature, and in fact, fishbone has an essential place among these foreign bodies (5). Such cases are seen among seafarers or in geographic areas, that usually coast to the oceans where fishes which have larger and harder fishbones are consumed (6). This study aims to present the radiological findings and the treatment process of a case that has the concurrent occurrence of these two conditions, which are rare in the literature, were determined.

## CASE REPORT

A 63-year-old male patient admitted to the emergency department with abdominal pain, nausea, and vomiting lasting one week. At the time of admission, physical examination findings of the patient who had no history of comorbid disease and previous abdominal surgery were asymmetric abdominal distention and peritoneal irritation findings more prominent in the upper level of the umbilicus. Laboratory examinations were normal except leukocytosis (16.200 mm<sup>3</sup>/L). The patients whose conventional abdominal X-ray showed air-fluid levels, an abdominal com-

**Cite this article as:** Akın E, Altıntoprak F, Gönüllü E, Yılmaz F, Yıldız YA. Coexisting of small bowel perforation and abdominal cocoon syndrome: A case report. Turk J Surg 2023; 39 (3): 274-277.

### Corresponding Author

Emrah Akın

E-mail: emrahakin@sakarya.edu.tr

Received: 15.12.2019

Accepted: 24.04.2020

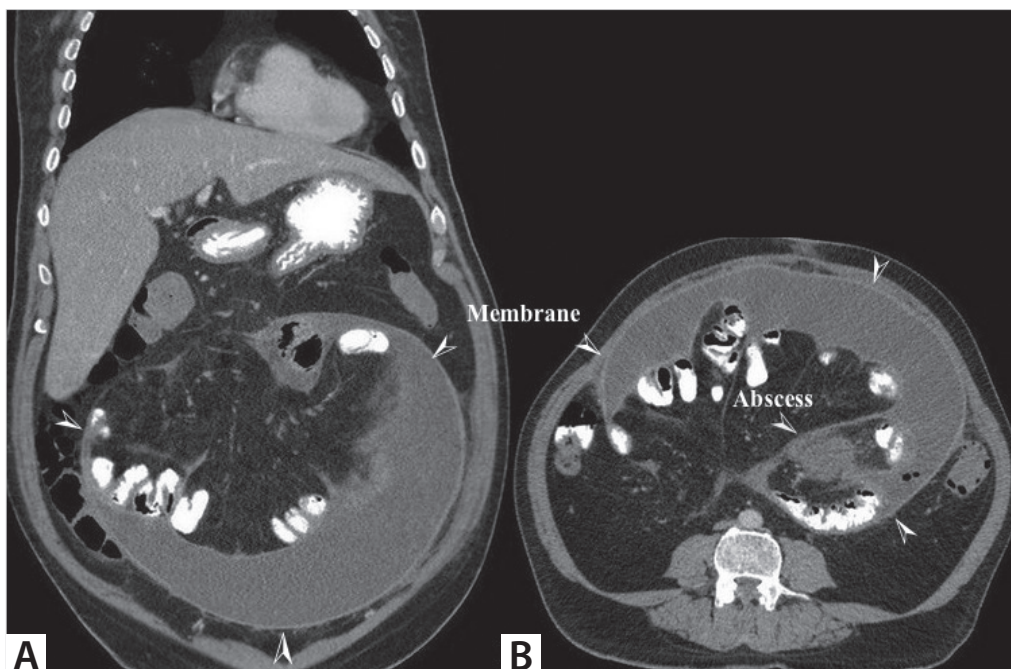
Available Online Date: 27.09.2023

© Copyright 2022 by Turkish Surgical Society Available online at www.turkjsurg.com

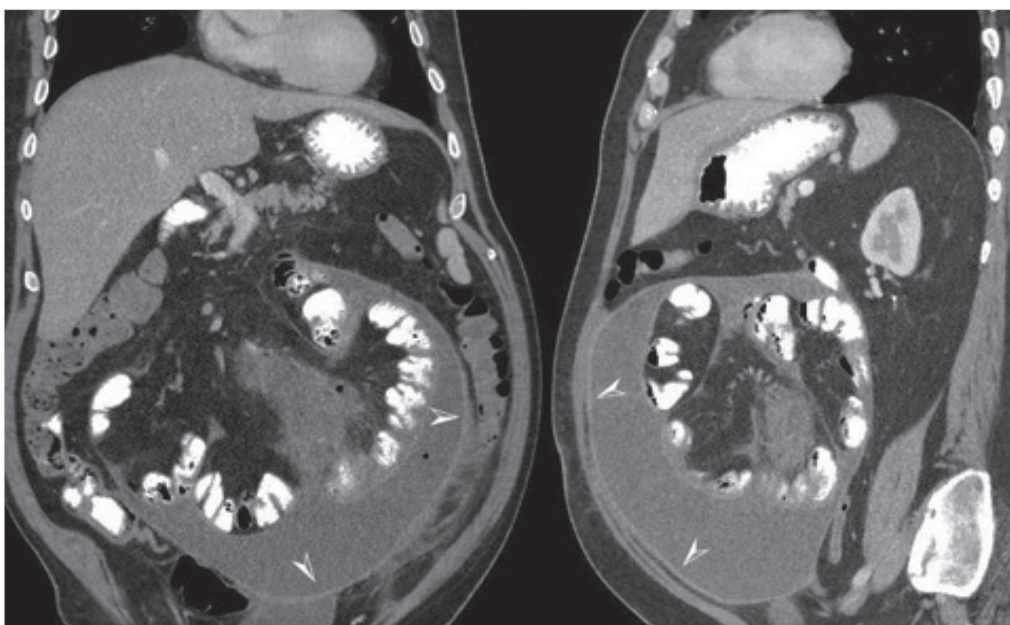
DOI: 10.47717/turkjsurg.2022.4687

puted tomography (CT) examination revealed that a thin membrane surrounded the small intestines gathered in the periumbilical region (Figure 1A). Within this membranous structure, localized free fluid and free air particles were found around the small intestine segments. Also, a 3 x 6 cm abscess appearance was detected in the proximal jejunum mesentery localization (Figure 1B).

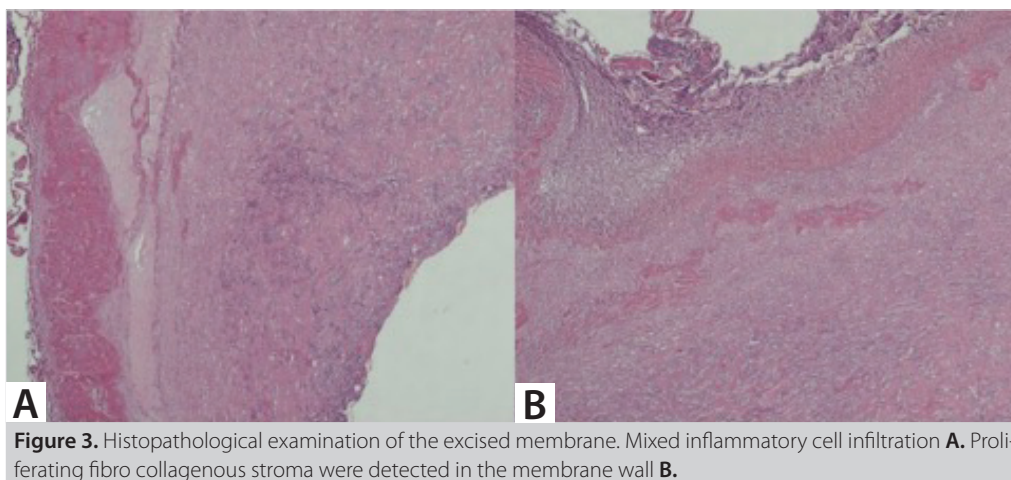
Laparoscopic exploration planned to the patient who has had an urgent surgery decision for due to peritoneal irritation findings. When the camera is entered tho the abdomen through the 10 mm port placed subumbilical, encountered with a smooth surfaced membrane surrounded by column segments seen, and it determined that all small intestine segments were settled in this membrane (Figure 2).



**Figure 1.** A thin membrane surrounded the small intestines gathered in the periumbilical region **A.** abscess appearance was detected in the proximal jejunum mesentery localization **B.**



**Figure 2.** All small intestine segments were settled in this membrane.



**Figure 3.** Histopathological examination of the excised membrane. Mixed inflammatory cell infiltration **A**. Proliferating fibro collagenous stroma were detected in the membrane wall **B**.

When the membrane was opened with a sharp dissection at the apex, purulent fluid was discharged. Intensive adhesions between the small intestine segments and the existing membrane were determined during the exploration, and conventional surgery was decided. A median incision was made to enter the abdomen, adhesions between the membrane and small intestine were dissected, abscess drained. In further exploration, it was determined that perforation existed in the small intestine 90 cm away from the Treitz ligament due to the foreign body, which was thought to be a fishbone. Following anastomosis after segmental resection, the membrane surrounding the small intestine was partially excised because of the intense adhesions. When the preoperative abdominal CT examination was re-evaluated, it was observed that the foreign body, which caused to perforation, could be observed on CT, but it was overlooked in the preoperative period. The postoperative period was uneventful, and the patient was discharged on the sixth day. At the histopathological examination of the excised membrane, mixed inflammatory cell infiltration, and proliferating fibro collagenous stroma were detected in the membrane wall (Figure 3). In the 10<sup>th</sup> month of follow-up, the patient is being followed up without any problems.

## DISCUSSION

ACS is a rare cause of intestinal obstruction, and it is challenging to diagnose clinically. According to Yip and Lee's article, small bowel obstruction without any other reason, similar history of attacks, unclear or asymmetric abdominal distention, and palpation of soft abdominal mass without abdominal tenderness were reported to be clinical signs of ACS (7). In our case, there were all findings above said except abdominal palpation. We think that we could not evaluate this finding due to the presence of peritoneal irritation findings at admission. However, these findings are non-specific and may be similar in patients with small bowel obstruction due to any cause. Therefore, we think that these findings may be useful only in patients who

are suspected to be abdominal cocoon. The disease is rare and presents with nonspecific symptoms; therefore, it is difficult to diagnose in the preoperative period. Small intestine conglomerations with membrane-covered loops at contrast-enhanced abdominal radiographs are typical, but the radiological diagnosis of ACS requires advanced experience (8). In a retrospective study in which 24 patients were analyzed, only 16% of the patients were diagnosed preoperatively. Diagnosis is usually made during surgery (9). The combination of careful clinical history, detailed physical examination, and radiological imaging results is the way of determination in the preoperative period, but most importantly, having met ACS previously. Thanks to our previous clinical experience, we were able to decide on surgery with ACS diagnosis preoperatively (10). Medical treatments such as steroids, immunosuppressive agents, and colchicine have been tried, but surgery is the main treatment modality (11). Although various comments have been made for the type and limits of the surgery to be performed in the literature, such as removal of the membrane totally by wide aggressive adhesiolysis, it is likely to encounter intense adhesions on the intestinal segments (12). Therefore, it should be kept in mind that extensive adhesions and total removal of the membrane may result in intestinal injuries or fistula development (13). Even though, recurrent intestinal obstruction attacks may be seen, albeit rarely, after limited adhesiolysis and partial excision of the membrane, it is not clear that these attacks, whether due to residual membrane or because of adhesions owing to previous abdominal surgery which are the most common cause of small bowel obstructions. In our case, we performed partial membrane excision and adhesiolysis due to severe adhesions, concurrently small bowel resection, because of the presence of a perforation.

## CONCLUSION

ACS is a rare clinical condition for which preoperative diagnosis is challenging. Diagnosis can be made by the combination of careful evaluation of the clinical history, questioning the recur-

rent character of the disease, careful physical examination, and careful radiological examinations. The necessity of early and rapid surgical treatment should be kept in mind.

**Peer-review:** Externally peer-reviewed.

**Author Contributions:** Concept - E.A., F.A.; Design - E.A., F.A.; Supervision - E.G.; Materials - E.G., Y.A.Y.; Data Collection and/or Processing - E.G., Y.A.Y., F.Y.; Analysis and/or Interpretation - E.A., F.A., F.Y., E.G.; Literature Search - E.A., E.G.; Writing Manuscript - E.A., F.A.; Critical Reviews - F.A.

**Conflict of Interest:** The authors have no conflicts of interest to declare.

**Financial Disclosure:** The authors declared that this study has received no financial support.

## REFERENCES

1. Sharma D, Nair RP, Dani T, Shetty P. Abdominal cocoon-a rare cause of intestinal obstruction. *Int J of Surg Case Rep* 2013; 4: 955-7. <https://doi.org/10.1016/j.ijscr.2013.08.004>
2. KT Foo, KC Ng, Rauff A, Foong WC, Sinniah R. Unusual small intestine obstruction in adolescent girls: The abdominal cocoon. *BJS* 1978; 65(6): 427-30. <https://doi.org/10.1002/bjs.1800650617>
3. Akbulut S. Accurate definition and management of idiopathic sclerosing encapsulating peritonitis. *World J Gastroenterol* 2015; 21(1): 675- 87. <https://doi.org/10.3748/wjg.v21.i2.675>
4. Diaz JJ Jr, Bokhari F, Mowery NT, Acosta JA, Block EF, Bromberg WJ, et al. Guidelines for management of small bowel obstruction. *J Trauma* 2008; 64(6): 1651-64. <https://doi.org/10.1097/TA.0b013e31816f709e>
5. Mora Guzman I, Valdes de A, Martin Perez E. Intra-abdominal abscess due to fish bone perforation of small bowel. *Acta Chir Belg* 2019; 119(1): 66-7. <https://doi.org/10.1080/00015458.2018.1493822>
6. Taguchi T, Kitagawa H. Fish bone perforation. *N Eng J Med*. 2019; 381(1): 762. <https://doi.org/10.1056/NEJMicm1900442>
7. Yip FWK, Lee SH. The abdominal cocoon. *Aus and New Zealand J Surg* 1992; 62(8): 638-42. <https://doi.org/10.1111/j.1445-2197.1992.tb07536.x>
8. Yeniay I, Karaca CA, Çalışkan C, Firat O, Ersin SM, Akgün E. Abdominal cocoon syndrome as a rare cause of mechanical obstruction: Report of two cases. *Ulus Travma Acil Cerrahi Derg* 2011; 17(6): 557-60. <https://doi.org/10.5505/tjtes.2011.39018>
9. Wei B, Wei HB, Guo WP, Aheng ZH, Huang Y, Hu BG, et al. Diagnosis and treatment of abdominal cocoon: a report of 24 cases. *Am J Surg* 2009; 198(3): 348-53. <https://doi.org/10.1016/j.amjsurg.2008.07.054>
10. Uzunoğlu Y, Altıntoprak F, Yalkın O, Gündüz Y, Çakmak Y, Özkan OV, et al. Rare etiology of mechanical intestinal obstruction: Abdominal cocoon syndrome. *World J Clin Cases* 2014; 2: 728-31. <https://doi.org/10.12998/wjcc.v2.i11.728>
11. Tarquini R, Colagrande S, Rosselli M, Novelli M, Dolenti S, Valoriani A, et al. Complete resolution of primary sclerosing peritonitis ("abdominal cocoon") following long term therapy for Tropheryma whipplei: A case report and review of literature. *BMJ Case Rep* 2009; 2009: bcr04.2009.1810. <https://doi.org/10.1136/bcr.04.2009.1810>
12. Renko AE, Witte SR, Cooper AB. Abdominal cocoon syndrome: An obstructive adhesiolytic metamorphosis. *BMJ Case Rep* 2019; 12(4). <https://doi.org/10.1136/bcr-2018-228593>
13. Sovatzidis A, Nikolaidou E, Katsourakis A, Chatzis I, Noussios G. Abdominal cocoon syndrome: Two cases of an anatomical abnormality. *Case Rep Surg* 2019; 2019: 3276919. <https://doi.org/10.1155/2019/3276919>



## OLGU SUNUMU-ÖZET

Turk J Surg 2023; 39 (3): 274-277

## İnce bağırsak perforasyonu ve abdominal cocoon sendromunun birlikte görülmesi: Bir olgu sunumu

Emrah Akin<sup>1</sup>, Fatih Altıntoprak<sup>1</sup>, Emre Gönüllü<sup>2</sup>, Fahri Yılmaz<sup>3</sup>, Yasin Alper Yıldız<sup>3</sup>

<sup>1</sup> Sakarya Üniversitesi Tıp Fakültesi, Genel Cerrahi Anabilim Dalı, Sakarya, Türkiye

<sup>2</sup> Sakarya Eğitim ve Araştırma Hastanesi, Genel Cerrahi Kliniği, Sakarya, Türkiye

<sup>3</sup> Sakarya Üniversitesi Tıp Fakültesi, Patoloji Anabilim Dalı, Sakarya, Türkiye

## ÖZET

Abdominal cocoon sendromu (ACS) nadir görülen ve nedeni bilinmeyen bir sendromdur. Hastalar peritonun kronik enflamasyonu sonucu ince bağırsakları saran intraabdominal fibrotik doku gelişimi ile karakterizedir. Yabancı cisme bağlı ince bağırsak perforasyonları da klinik pratikte sık karşılaşılan olgular değildir. Bu iki nadir durumun bir arada bulunması ise son derece ender bir durumdur. Bu yazıda, akut batın sendromu bulguları ile başlayan ve bu iki nadir durumun birlikteliği saptanan olgunun radyolojik bulguları ve tedavi süreci sunulmaktadır.

**Anahtar Kelimeler:** Abdominal cocoon sendromu, balık kılıçığı, perforasyon, intestinal obstrüksiyonu

**DOI:** 10.47717/turkjsurg.2022.4687