



Utility of positron emission tomography for determination of axillary metastasis of breast cancer

Gökhan Pösteği^{ID}, Alican Güreşin^{ID}, Sertaç Ata Güler^{ID}, Turgay Şimşek^{ID}, Nuh Zafer Cantürk^{ID}

Department of General Surgery, Kocaeli University Faculty of Medicine, Kocaeli, Türkiye

ABSTRACT

Objective: The involvement of axillary lymph nodes plays a key role in breast cancer staging. Positron emission tomography is a promising modality for detecting axillary lymph node metastasis. In addition, nomograms are used to predict the status of axillary lymph nodes. In this study, the role of positron emission tomography in determining axillary metastasis and its correlation with the nomogram was evaluated.

Material and Methods: The axillary maximum standard uptake value (SUVmax) values of the patients in the preoperative period, the features in the perioperative and postoperative specimen and Memorial Sloan Kettering Cancer Center nomogram data were evaluated.

Results: As axillary SUVmax detected by Positron emission tomography in the preoperative period increased, so did the likelihood of lymph node involvement. Axillary SUVmax value were compared with Memorial Sloan Kettering Cancer Center nomogram data but no correlation was found. Age, lymph node number, histopathology results, mass diameter, presence or absence of lymphovascular invasion and/or perineural invasion, tumor type, estrogen receptor status, Ki67 and Cerb-B2 statuses were not correlated. However, axillary SUVmax was inversely correlated with grade and progesterone receptor status.

Conclusion: Results from positron emission tomography of axillary lymph nodes in breast cancer patients showed that SUVmax was only inversely related to cancer grade and progesterone receptor status while not correlating with other accepted parameters for tumor assessment. Thus there is insufficient reliability for the use of axillary SUVmax alone for accurate assessment of tumor characteristics at present.

Keywords: Axillary metastasis, breast cancer, positron emission tomography

INTRODUCTION

Breast cancer is the most common type of invasive cancer among women. The status of the axillary lymph nodes is important for staging and local control of the disease. Therefore, in breast cancer patients, axillary lymph node dissection (ALND) is performed in order to aid treatment decision-making and for prognostic purposes. Prognostic and predictive factors for breast cancer are various, including the number of axillary lymph nodes involved. Although patients with palpable tumor may have clinically negative axilla, approximately 30% are positive on histopathological assessment after axillary dissection, and this figure is 10% in non-palpable tumors. Thus, ALND is performed unnecessarily in the remaining 70% or 90% of patients each group, respectively. The low positivity rate after dissection in patients with clinically negative axilla has raised the question of the necessity of performing ALND in this group, which may be associated with many adverse effects and could be considered unnecessary overtreatment (1).

At the present time, breast-conserving surgery (BCS) is almost ubiquitous. In addition, many surgeons are more selective about performing ALND and may prefer sentinel lymph node biopsy (SLNB), and take Z011 clinical trial to attention.

Imaging methods including 18F-fluorodeoxyglucose tomography by combined positron emission tomography/computed tomography (PET/CT), are used to provide anatomical information for various disorders. While PET was only in research in the first years, PET/CT were developed with integration of CT and began to be used in routine clinical evaluations with high diagnostic potential in the following years.

Nomograms have been used in breast cancer diagnosis and can be used to predict axillary lymph node metastasis in the light of preoperative demographic and

Cite this article as: Pösteği G, Güreşin A, Güler SA, Şimşek T, Cantürk NZ. Utility of positron emission tomography for determination of axillary metastasis of breast cancer. Turk J Surg 2023; 39 (4): 293-299.

Corresponding Author

Gökhan Pösteği

E-mail: gokhanposteki-dr@hotmail.com

Received: 20.12.2021

Accepted: 22.12.2023

Available Online Date: 29.12.2023

© Copyright 2023 by Turkish Surgical Society Available online at www.turkjsurg.com

DOI: 10.47717/turkjsurg.2023.5600

pathological findings. One of these is the Memorial Sloan Kettering Cancer Center (MSKCC) calculation chart. The MSKCC uses seven variables: tumor size, lymphatic invasion, tumor histology, nuclear grade, multifocality, estrogen receptor status and progesterone receptor status (2).

The aim was to determine the preoperative SUVmax value of axillary lymph nodes in PET/CT for predicting the axillary metastasis and to compare the findings with the MSKCC nomogram.

MATERIAL and METHODS

Patients

Patients who underwent surgery for breast cancer at our clinic between February 2015 and November 2016 were recruited to the study. The inclusion criteria were: clinically node negative, absence of any other primary neoplasm; and preoperative PET/CT performed. Patients were excluded if they had either diabetes mellitus or inflammatory breast cancer. A total of 70 patients were excluded from the study and the study was conducted with 51 patients (Figure 1). Ethics approval for the study was obtained from the clinical ethical committee of our university and our study has been performed with the appropriate participants' informed consent in compliance with the Helsinki Declaration.

Mean age of the patients was 52.4 ± 12.4 . Forty-three patients were diagnosed with invasive ductal cancer, six patients with invasive lobular cancer, and the remaining patients with other rare breast tumors. Sentinel lymph node biopsy was evaluated as positive in pathology specimens of 38 patients. Eight patients were evaluated as grade 1, 28 patients as grade 2, and

17 patients as grade 3. Estrogen receptor (ER) in 36 patients and progesterone receptor (PR) in 32 patients were evaluated positive.

Methods

Axillary SUV (standard uptake value) values of the all patients were recorded. The prediction of lymph node metastasis with MSKCC nomograms was preoperatively performed. Nomogram data were taken as age, size of the mass according to the preoperative images, location of the tumor, and lymph vascular invasion status in the preoperative pathological specimen, the unifocality or multifocality feature, estrogen and progesterone receptor status. The probability of axillary involvement was calculated by entering these criteria to the MSKCC Breast Cancer nomogram. The preoperative axillary SUVmax values in PET/CT were recorded for each case.

The axillary SLNB with dual methods including preoperatively applied radioactive tracer and perioperative injections of methylene blue to the areola was performed according to guidelines and specimens handled following incision to axilla were evaluated by using the frozen section. Axillary lymph node dissection was performed to the patients whose SLNB results were reported as metastatic. Post-operative pathology reports of the patients were obtained and tumor mass size, tumor type, histological grade, lymphovascular invasion status, ER percentage, PR percentage, Cerb-B2 and Ki67 percentage were recorded as data. The data obtained were statistically compared with the prognostic and predictive values of the patients and their axillary lymph node status.

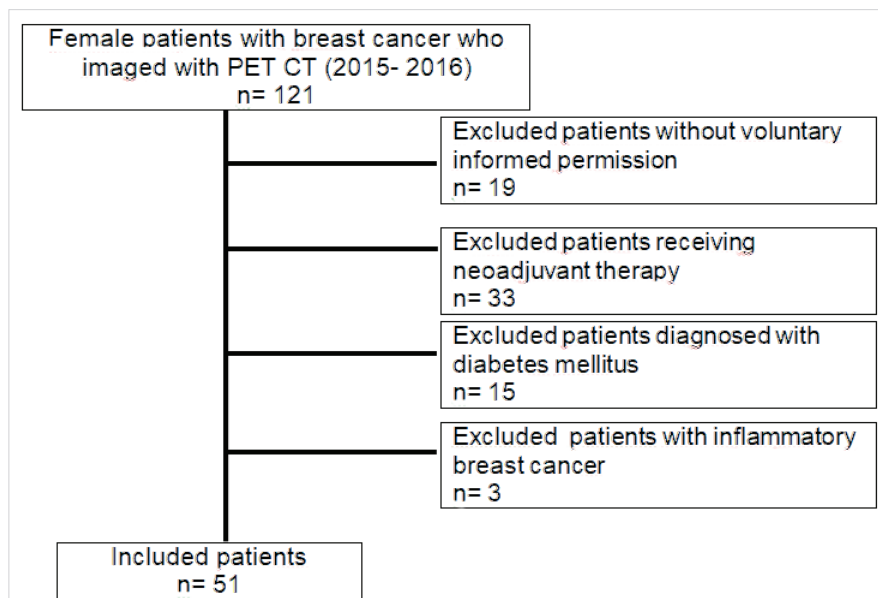


Figure 1. Distribution of patients with exclusion criteria.

Main (primary) implications are the preoperative axillary SUVmax value for predicting axillary metastasis and comparison of it with MSKCC nomogram. Secondary implications: Determination of the relationship between preoperative axillary SUVmax value and ER, PR, HER2/neu, Ki67, tumor size, tumor grade, axillary status, molecular subgroups, lymphovascular invasion and age.

Statistical Analysis

Statistical evaluation was made with IBM SPSS 20.0 (SPSS Inc., Chicago, IL, USA) Package Program. The normal distribution test was done by using the Kolmogorov-Smirnov test. Numerical variables were given as mean \pm standard deviation and median (25th percentile-75th percentile) and frequency (percentiles). Differences between the groups were evaluated with the Mann-Whitney U test for numerical variables that did not have a normal distribution. The relationship between the numerical variables was evaluated using Spearman correlation analysis. $p < 0.05$ was considered enough for statistical significance. In addition, ROC analysis was performed to evaluate axilla SUVmax uptake by positron emission tomography.

RESULTS

SUVmax values of the axilla were examined with PET/CT in the preoperative period and the postoperative axillary sentinel lymph node status. It was observed that the possibility of sentinel lymph node involvement in the axilla increased when the SUVmax value was high in preoperative PET/CT ($p = 0.000$). According to ROC analysis, its sensitivity was calculated as 80.95%, specificity 88.89%, positive predictive value 97.1%, and negative predictive value 50%. The cut-off value for axillary SUVmax was 2.3 (Figure 2).

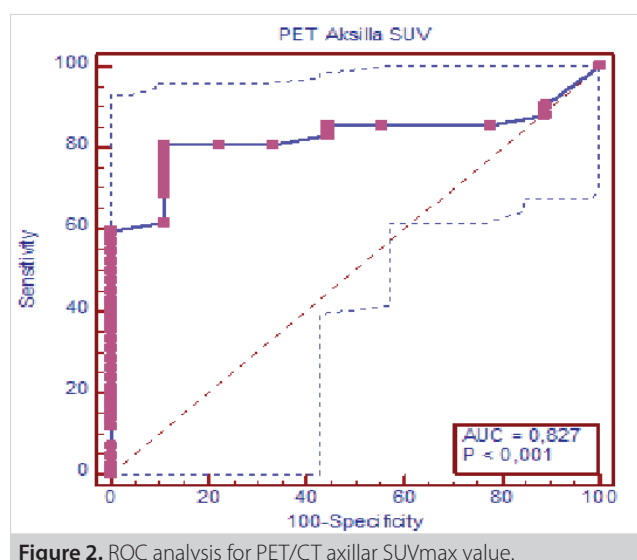


Figure 2. ROC analysis for PET/CT axillary SUVmax value.

The comparison of MSKCC nomogram data with axilla PET/CT SUVmax value was done. In the correlation analysis, it was seen that the increase in the axillary SUVmax value was not statistically similar to the increase in the percentage of the nomogram ($p = 0.061$). SUVmax values were evaluated according to age and parameters reported in pathology reports. With the comparison of age and axillary SUVmax value, there was no significant relation ($r = -0.125$, $p = 0.382$). With the correlation analysis, the number of metastatic lymph nodes and axillary SUVmax value were found to be insignificantly different ($r = -0.070$, $p = 0.660$). In other words, the increase in the number of metastatic lymph nodes did not affect the SUVmax values. When the pathological tumor size and axillary SUVmax value were compared, the correlation between them was not found significant ($r = -0.176$, $p = 0.217$). It means that the increase of tumor size did not increase the axillary SUVmax value. The correlation analysis between grade and axillary SUVmax value showed significant changes ($r = 0.439$, $p = 0.001$). The high tumor grade showed to be related with the high axillary SUVmax value (Figure 3).

With the evaluation of data, it was observed that the relationship between lymphovascular invasion and axillary SUVmax value was insignificant ($r = -0.231$, $p = 0.315$), the axillary SUVmax values were insignificant, when compared with histological tumor types ($r = 0.075$, $p = 0.603$). With correlation analysis, comparison of ER positivity and axillary SUVmax value was found to be insignificant (true $r = -0.157$, $p = 0.270$) (code $r = -260$, $p = 0.065$). There was significant and inverse difference between PR and axillary SUVmax values (true $r = -0.285$, $p = 0.043$) (code $r = -302$, $p = 0.031$) (Figure 4). So, while the PR level decreased, the axillary SUVmax value increased.

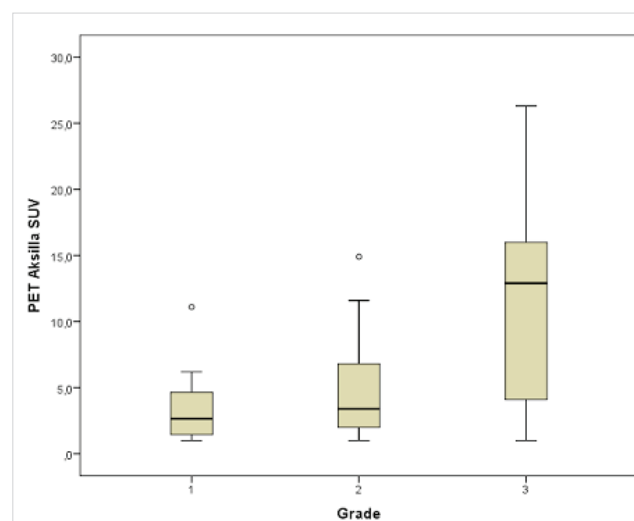


Figure 3. Correlation analysis between grade and axillary SUVmax value.

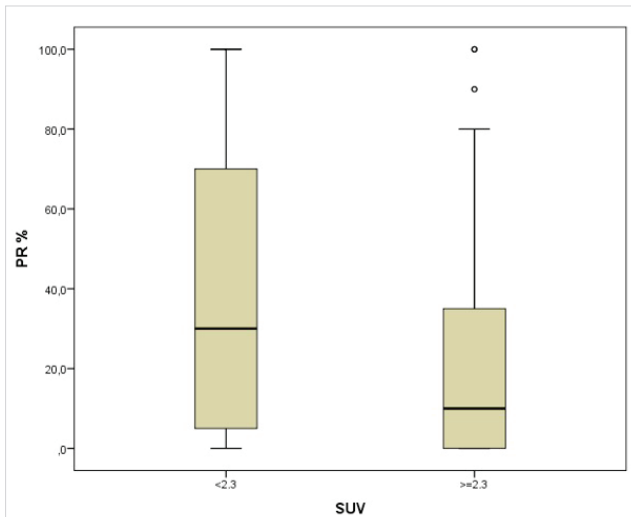


Figure 4. Correlation analysis between PR with axillary SUVmax value.

There was not any significant relation between Ki67 results and axillary SUVmax values when compared ($r = -0,220, p = 0.167$). The correlation analysis between Cerb-B2 positivity and axillary SUVmax value was also similarly insignificant ($r = -0.082, p = 0.569$). Statistical analysis also showed that there was no relationship between perineural invasion and axillary SUVmax values ($r = 0.143, p = 0.625$) (Table 1).

DISCUSSION

Determining axillary lymph node involvement in breast cancer patients is still one of the most controversial issues today. It is known that breast cancer can spread first to regional axillary lymph nodes and then to other body parts (bone, liver, lung, brain). Therefore, determining the metastasis status in axillary lymph nodes is important in terms of staging, treatment planning and prediction of prognosis for breast cancer.

Table 1. Patient characteristics in low- and high-zinc groups

	Axillary SUVmax < 2.3	Axillary SUVmax > 2.3	p
Age	54.0 (50-64)	51 (43-60.75)	0.391
Number of metastatic lymph nodes	5.50 (3.00-7.75)	5.50 (2.75-9.00)	0.987
Pathology mass diameter (mm)	30.00 (22.00-35.00)	30.00 (17.00-44.25)	0.756
Grade			
1	3 (20%)	5 (13.9%)	0.001
2	9 (60%)	17 (47.2%)	
3	3 (20%)	14 (38.9%)	
Lymphovascular invasion			0.315
No	2 (40%)	7 (43.7%)	
Yes	3 (60%)	9 (56.2%)	
Perineural invasion			0.625
No	3 (100%)	5 (45.5%)	
Yes	0 (0%)	6 (54.5%)	
Tumor type			0.603
Invasive ductal	14 (93.3%)	29 (80.6%)	
Invasive lobular	1 (6.7%)	5 (13.9%)	
Other	0 (0%)	2 (5.6%)	
ER			0.065
Positive	12 (80%)	24 (66.7%)	
Negative	3 (20%)	12 (33.3%)	
PR			0.031
Positive	12 (80%)	20 (55.6%)	
Negative	3 (20%)	16 (44.4%)	
Ki67			0.563
Positive	9 (60%)	21 (58.3%)	
Negative	6 (40%)	15 (41.7%)	
Cerb-B2			0.837
0	11 (73.3%)	25 (69.4%)	
1	0 (0%)	1 (2.8%)	
2	0 (0%)	2 (5.6%)	
3	4 (26.7%)	8 (22.7%)	

The best clinical procedure to determine the metastasis status in lymph nodes is still ALND. However, it is known that adverse events occur due to ALND including lymphedema, limitation of arm and shoulder movements, numbness in the upper arm, etc. in 20% of patients. On the other hand, in patients with T1 and T2 breast cancer, only 3-20% of those who undergo routine ALND is reported to have metastases. This means that routine axillary lymph node dissection is unnecessary for the most of the patients (3,4). In the light of this information, SLNB has been developed over the years and entered clinical practice. With the introduction of the SLNB to the clinical use, unnecessary ALND were significantly reduced and unnecessary complications were prevented. Sentinel lymph node evaluation requires a multidisciplinary approach with participation at nuclear medicine specialist, surgeon, and an experienced pathologist (5,6).

The success of SLNB depends on the experience of the surgeon (7). Despite all care, there is 10-15% false negativity in SLNB (8). This situation has led to the development of some non-invasive, simple, easy-to-use and reproducible imaging methods to detect axillary and other lymph node metastases (9,10).

PET/CT, one of the modern imaging methods, is one of the noninvasive techniques in detecting lymph nodes and other organ metastases in cancer patients. This technique has been shown to be useful in the detection of many subclinical metastases in cancer patients. PET/CT has been found useful in showing metastasis to normal size and anatomical lymph nodes when compared to other radiological methods (11). A preclinical study showed that PET/CT was a feasible method to show lymph node metastases (12). Although various clinical studies have been conducted to evaluate axillary staging with PET/CT in patients with breast cancer, these studies have conflicting results (13,14). The study of the Milan Cancer Institute encouraged use of PET/CT for preoperative evaluation. In the evaluation made in this study, PET/CT was performed preoperatively in 167 patients who were previously decided to undergo axillary lymph node dissection and compared with the patients' existing pathologies. In the study, the accuracy of PET/CT in axillary lymph node staging was 94.4% and its positive predictive value was 84%. False negativity was expressed as result of patients with a low tumor burden or microscopic lymph node metastasis (15). Utech et al. correctly detected the axillary status of 44 patients with stages 1-3 breast cancer with PET/CT and reported the sensitivity as 100% (14). In the other studies, sensitivity ranged between 70% and 100% (16,17).

There were few studies that compared SLNB and PET/CT. In 100 PET/CT with negative axillary involvement; Zornosa et al. reported 17 positive axillary metastasis with SLNB (sensitivity

84%) (18). In our study, as the axillary SUVmax value in PET/CT increased, so did the possibility of axillary sentinel lymph node metastasis. The sensitivity was calculated as 80.95% and positive predictive value as 97.1%.

Greco et al. suggested that the sensitivity of PET/CT for detection of axillary lymph node metastasis was 98% if tumor size was 21-50 mm, and 84% in tumors with a diameter of 10 mm or less. On the other hand, negative predictive and positive predictive values were respectively 93.5-97.5% and 54.5%-94.1% (15). In present study, we did not observe any significant relationship between the diameter of the pathological mass and the axillary SUVmax value.

As known, invasive lobular cancers have significantly lower FDG uptake and higher false negativity than those of invasive ductal cancers. This was reported to be associated with low GLUT1 expression and low proliferation rate of this type cancer cells (19). On the other hand, invasive ductal carcinoma has higher SUVmax values than other types of breast cancers (20). In our study, axillary SUVmax values were compared for different types of breast cancer and we suggested that the difference of axillary SUVmax values due to tumor types was statistically insignificant.

Yoon HJ et al. reported that SUVmax values for ER and PR negative breast cancer were approximately 50% higher than the positive cases in their study where they included 43 patients with large or locally advanced invasive ductal cancer (21). Other studies have also shown higher SUVmax values for ER and PR negative breast cancers (22,23). We also determined that ER positivity did not affect the axillary SUVmax value, but there was an inversely significant relationship between the PR receptor value and axillary SUVmax value, consistent with previous studies.

Groheux et al. found that SUVmax values of the primary lesion for 132 preoperative breast cancer patients were higher in patients without ER, PR negative and Cerb-B2 expression. Cerb-B2 positivity indicates tumor aggressiveness and is a sign of hormone and chemotherapy resistance and poor prognosis (24). A positive relationship between Cerb-B2 positivity and F-FDG uptake was reported (25,26), but some of publications did not support this significant relationship (23). We also demonstrated that Cerb-B2 positivity did not affect the axillary SUVmax value.

Ekmekçioğlu et al. compared prognostic factors in 140 breast cancer cases, primary tumor F-FDG uptake was determined by histological type, histological grade, pleomorphism, mitosis number, lymphatic invasion, necrosis, estrogen receptor negativity, high Ki-67 level, axillary lymph node involvement that it has a high correlation (27). In our study, the relationship between axillary SUVmax value and histological grade of

primary tumor was statistically significant. However, there was no relationship between lymphovascular invasion, and Ki67 level with axillary SUVmax. As it is known, the usage of nomograms is easy and helpful in many conditions. Any study comparing nomogram and axillary SUVmax values was not found in the literature. In this study, when the MSKCC nomogram and axillary SUVmax value were compared statistically, there was not any significant relationship between them.

CONCLUSION

Today, use of PET/CT in the axillary evaluation of breast cancer is among the promising non-invasive methods. Its usability can be evaluated in new nomograms to be developed in the future. Its reliability may increase with new and sophisticated development in the future due to advances in techniques. Unfortunately, its reliability alone is currently debatable.

Ethics Committee Approval: This study was approved by the Kocaeli University Noninvasive Clinical Research Ethics Committee (Decision no: GOKA-EK 2016, Date: 30.11.2016).

Peer-review: Externally peer-reviewed.

Author Contributions: Concept - GP, AG; Design - GP; Supervision - NZC; Data Collection and/or Processing - GP, SAG; Analysis and/or Interpretation - GP, SAG; Literature Search - GP, AG; Writing Manuscript - GP; Critical Reviews - TŞ, NZC.

Conflict of Interest: The authors have no conflicts of interest to declare.

Financial Disclosure: The authors declared that this study has received no financial support.

REFERENCES

1. Trentham-Dietz A, Newcomb PA, Egan KM, Titus-Ernstoff L, Baron JA, Storer BE, et al. Weight change and risk of postmenopausal breast cancer. *Cancer Causes Control* 2000; 11: 533-42. <https://doi.org/10.1023/A:1008961931534>
2. Houpu Y, Fei X, Yang Y, Fuzhong T, Peng L, Bo Z, et al. Use of Memorial Sloan Kettering Cancer Center nomogram to guide intraoperative sentinel lymph node frozen sections in patients with early breast cancer. *J Surg Oncol* 2019; 120(4): 587-92 <https://doi.org/10.1002/jso.25638>
3. Liberman L. Clinical management issues in percutaneous core breast biopsy. *RCNA* 2000; 138: 791-807. [https://doi.org/10.1016/S0033-8389\(05\)70201-3](https://doi.org/10.1016/S0033-8389(05)70201-3)
4. Agnese DM. Advances in breast imaging. *Surg Technol Int* 2005; 14: 51-6.
5. Boissierie-Lacroix M, Ranchon N. Contribution of high resolution breast ultrasonography in the characterization of ambiguous mammograms. *Gynecol Obstet Fertil* 2002; 30: 147-53.
6. Further Revisions to Guidance Notes for Ultrasound Scanners used in the Examination of the Breast, with Protocol for Quality Testing. Evaluation Reprt MDA/98/52. London: Medical Devices Agency 1999.
7. Stavros AT, Thickman D, Rapp CL, Dennis MA, Parker SH, Sisney GA. (1995) Solid breast nodules: use of sonography to distinguish between benign and malignant lesions. *Radiology* 1995; 196: 123-34. <https://doi.org/10.1148/radiology.196.1.7784555>
8. Tofts PS, Berkowitz B, Schnall MD. Quantitative analysis of dynamic Gd - DTPA enhancement in breast tumours using a permeability model. *Magnetic Resonance Imaging* 1995; 33: 564-8. <https://doi.org/10.1002/mrm.1910330416>
9. Rankin S. MRI of the breast. *Br Radiol* 2000; 73: 806-18. <https://doi.org/10.1259/bjr.73.872.11026854>
10. Berg W, Gutierrez L, NessAiver M, Carter W, Bhargavan M, Lewis R, et al. Diagnostic accuracy of mammography, clinical examination, US, and MR Imaging in preoperative assessment of Breast Cancer. *Radiology* 2004; 233: 830-49. <https://doi.org/10.1148/radiol.2333031484>
11. Orel SG, Schnall MD. MR imaging of the breast for the detection, diagnosis, and staging of the breast cancer. *Radiology* 2001; 220: 13-30. <https://doi.org/10.1148/radiology.220.1.r01j13113>
12. Hirose M, Hashizume T, Seino N, Kubota H, Nobusawa H, Gokan T. Atlas of breast magnetic resonance imaging. *Curr Probl Diagn Radiol* 2007; 36: 51-65. <https://doi.org/10.1067/j.cpradiol.2006.10.003>
13. Hochman MG, Orel SG, Powell CM, Schnall MD, Reynolds CA, White LN. Fibroadenomas: MR imaging appearances with radiologic-histopathologic correlation. *Radiology* 1997; 204: 123-9. <https://doi.org/10.1148/radiology.204.1.9205233>
14. Utech CI, Young CS, Winter PF. Prospective evaluation of fluorine- 18 fluorodeoxyglucose positron emission tomography in breast cancer for staging of the axilla related to surgery and immunocytochemistry. *Eur J Nucl Med* 1996; 23: 1588-93. <https://doi.org/10.1007/BF01249621>
15. Greco M, Crippa F, Agresti R, Seregini E, Gerali A, Giovanazzi R, et al. Axillary lymph node staging in breast cancer by 2-fluoro-2-deoxy-D-glucose positron emission tomography: Clinical evaluation and alternative management. *J Natl Cancer Inst* 2001; 93: 630-5. <https://doi.org/10.1093/jnci/93.8.630>
16. Nunes LW, Schnall MD, Orel SG, Hochman MG, Langlotz CP, Reynolds CA, et al. Breast MR imaging: Interpretation model. *Radiology* 1997; 202: 833-41. <https://doi.org/10.1148/radiology.202.3.9051042>
17. Liberman L, Morris EA, Dershaw DD, Abramson AF, Tan LK. Ductal enhancement on MR imaging of the breast. *AJR* 2003; 181: 519-25. <https://doi.org/10.2214/ajr.181.2.1810519>
18. Zornoza G, Garcia-Velloso MJ, Sola J, Regueira FM, Pina L, Beorlegui C. 18F-FDG PET complemented with sentinel lymph node biopsy in the detection of axillary involvement in breast cancer. *Eur J Surg Oncol* 2004; 30: 15-9. <https://doi.org/10.1016/j.ejso.2003.10.010>
19. Puglisi F, Follador A, Minisini AM, Cardellino GG, Russo S, Andreatta C. Baseline staging tests after a new diagnosis of breast cancer: Further evidence of their limited indications. *Ann Oncol* 2005 16: 263-6. <https://doi.org/10.1093/annonc/mdl063>
20. Jung NY, Kim SH, Choi BB, Kim SH, Sung MS. Associations between the standardized uptake value of (18) F-FDG PET/CT and the prognostic factors of invasive lobular carcinoma: In comparison with invasive ductal carcinoma. *World J Surg Oncol* 2015; 13: 113. <https://doi.org/10.1186/s12957-015-0522-9>

21. Yoon HJ, Kang KW, Chun IK, Cho N, Im SA, Jeong S, et al. Correlation of breast cancer subtypes, based on estrogen receptor, progesterone receptor, and HER2, with functional imaging parameters from 68Ga-RGD PET/CT and 18F-FDG PET/CT. *Eur J Nucl Med Mol Imaging* 2014; 21. <https://doi.org/10.1007/s00259-014-2744-4>
22. Ulaner GA, Castillo R, Wills J, Gönen M, Goldman DA. 18F-FDG-PET/CT for systemic staging of patients with newly diagnosed ER-positive and HER2-positive breast cancer. *Eur J Nucl Med Mol Imaging* 2017; 44(9): 1420-7. <https://doi.org/10.1007/s00259-017-3709-1>
23. Liu C, Gong C, Liu S, Zhang Y, Zhang Y, Xu X, et al. 18F-FES PET/CT Influences the staging and management of patients with newly diagnosed estrogen receptor-positive breast cancer: A retrospective comparative study with 18F-FDG PET/CT. *Oncologist* 2019; 24(12): e1277-e85. <https://doi.org/10.1634/theoncologist.2019-0096>
24. Groheux D, Giacchetti S, Moretti JL, Porcher R, Espié M, Lehmann-Che J, et al. Correlation of high 18F-FDG uptake to clinical, pathological and biological prognostic factors in breast cancer. *Eur J Nucl Med Mol Imaging* 2011; 38(3): 426-35. <https://doi.org/10.1007/s00259-010-1640-9>
25. Ulaner GA, Castillo R, Goldman DA, Wills J, Riedl CC, Pinker-Domenig K, et al. F-FDG-PET/CT for systemic staging of newly diagnosed triple-negative breast cancer. *Eur J Nucl Med Mol Imaging* 2016; 43(11): 1937-44. <https://doi.org/10.1007/s00259-016-3402-9>
26. Groheux D, Martineau A, Teixeira L, Espié M, de Cremoux P, Bertheau P, et al. 18FDG-PET/CT for predicting the outcome in ER+/HER2- breast cancer patients: Comparison of clinicopathological parameters and PET image-derived indices including tumor texture analysis. *Breast Cancer Res* 2017; 19(1): 3. <https://doi.org/10.1186/s13058-016-0793-2>
27. Ekmekcioglu O, Aliyev A, Yilmaz S, Arslan E, Kaya R, Kocael P, et al. Correlation of 18F-fluorodeoxyglucose uptake with histopathological prognostic factors in breast carcinoma. *Nucl Med Commun* 2013; 34(11): 1055-67. <https://doi.org/10.1097/MNM.0b013e3283658369>



ORJİNAL ÇALIŞMA-ÖZET

Turk J Surg 2023; 39 (4): 293-299

Meme kanserinin aksiller metastazının belirlenmesinde pozitron emisyon tomografisinin kullanılabilirliği

Gökhan Pösteki, Alican Güreşin, Sertaç Ata Güler, Turgay Şimşek, Nuh Zafer Cantürk

Kocaeli Üniversitesi Tıp Fakültesi, Genel Cerrahi Anabilim Dalı, Kocaeli, Türkiye

ÖZET

Giriş ve Amaç: Aksiller lenf nodlarının tutulumu meme kanseri evrelemede anahtar rol oynar. Pozitron emisyon tomografisi, aksiller lenf nodu metastazını saptamak için umut verici bir yöntemdir. Ek olarak, aksiller lenf nodlarının durumunu tahmin etmek için nomogramlar kullanılır. Bu çalışmada pozitron emisyon tomografisinin aksiller metastaz belirlemedeki rolü ve nomogram ile ilişkisi değerlendirildi.

Gereç ve Yöntem: Hastaların preoperatif dönemde aksiller maksimum standart uptake (SUVmax) değerleri, peroperatif ve postoperatif spesimenlerdeki özellikler ve Memorial Sloan Kettering Cancer Center nomogram verileri değerlendirildi.

Bulgular: Pozitron emisyon tomografisi ile preoperatif dönemde saptanan aksiller SUVmax arttıkça lenf nodu tutulumu olasılığı da arttı. Aksiller SUVmax değeri Memorial Sloan Kettering Cancer Center nomogram verileri ile karşılaştırıldı ancak korelasyon bulunamadı. Yaş, lenf nodu sayısı, histopatoloji sonuçları, kütle çapı, lenfovasküler invazyon ve/veya perinöral invazyon varlığı veya yokluğu, tümör tipi, östrojen reseptör durumu, Ki67 ve Cerb2 durumları korele değildi. Bununla birlikte, aksiller SUVmax, tümörün derecesi ve progesteron reseptör durumu ile ters orantılıydı.

Sonuç: Meme kanseri hastalarında aksiller lenf nodlarının pozitron emisyon tomografisinden elde edilen sonuçlar, SUVmax'ın kanser derecesi ve progesteron reseptör durumu ile sadece ters orantılı olduğunu ve tümör değerlendirmesi için kabul edilen diğer parametrelerle korele olmadığını gösterdi. Bu nedenle, şu anda tümör özelliklerinin doğru bir şekilde değerlendirilmesi için aksiller SUVmax'ın tek başına kullanımı için yeterli güvenilirlik yoktur.

Anahtar Kelimeler: Aksiller metastaz, meme kanseri, pozitron emisyon tomografisi

DOI: 10.47717/turkjsurg.2023.5600