



Repair of stoma prolapse with the “peristomal cerclage” method using vessel tape

Arif Hakan Demirel , İbrahim Kurtoğlu , Saygın Altiner , Recep Aydın 

Clinic of General Surgery, Ankara Training and Research Hospital, Ankara, Türkiye

ABSTRACT

Stoma prolapse is one of the most common late complications following stoma construction. Although prolapses can be managed conservatively, they often require surgical revision. This study aimed to describe a revision method called *peristomal cerclage* applied with local anesthesia to treat stoma prolapse. A 66-year-old male patient with advanced rectal cancer underwent sigmoid loop colostomy one year ago due to a distal occlusive tumor. A revision of the colostomy prolapse that developed postoperatively was planned. After the reduction of the 12 cm prolapse into the abdomen under local anesthesia, a repair was performed in the form of peristomal wrapping of a vessel tape; except for short-term abdominal distension, no complications developed in the patient. He is currently in the postoperative 26th month and terminal period, and his colostomy is working normally. The present report aimed to describe the *peristomal cerclage* method, a minimally invasive revision procedure applied to patients with stoma prolapse, and to deliver its long-term results. It is important to report the results obtained with the more widespread use of this method.

Keywords: Stoma, colostomy, prolapse, cerclage

INTRODUCTION

Stoma prolapse is one of the late complications of stoma construction and is defined as the invagination of the proximal intestine through the mouth of the stoma. It is more common, especially in transverse loop colostomies. It is relatively less common in the extraperitoneal colostomy technique (1,2). Although it does not pose a vital risk for the patient, apart from cosmetic negativities and stoma care difficulties, ischemia, ulceration and necrosis are seen as a result of incarceration developing in prolapse, though uncommon. In these cases, urgent surgical intervention is required with a high probability of morbidity (3). In addition to resection operations performed by laparotomy or laparoscopy to repair prolapsed stoma, local revision and resection techniques have been described (4,5). Conservative interventions such as placing prolapsed bowel loops in the abdomen and fixing them to the colostomy opening in the abdominal wall have also been described in elderly patients or temporary colostomies (1,2,6). The report presented here aimed to describe a conservative local revision procedure performed by placing a silicone vessel tape around the colostomy after pushing the prolapsed loop into the abdomen under local anesthesia.

CASE EXAMPLE and TECHNICAL DETAILS

A 66-year-old patient with an obstructive mass in the rectum was evaluated as inoperable in an external center due to lung and liver metastases and bladder invasion, and chemotherapy was started. Our clinic re-evaluated the patient, and it was decided to open a colostomy due to the tendency of the intestinal passage to be obstructed, and a loop colostomy was performed on the sigmoid colon under general anesthesia. The patient developed colostomy prolapse, which started to develop six months after the operation and reached approximately 12 cm in size (Figure 1). It was decided to perform a revision with local anesthesia for the prolapse. The patient was operated on with cefazolin (2 gr/IV) prophylaxis without bowel preparation after eight hours of fasting. Ten mL of prilocaine/lidocaine local

Cite this article as: Demirel AH, Kurtoğlu İ, Altiner S, Aydın R. Repair of stoma prolapse with the “peristomal cerclage” method using vessel tape. Turk J Surg 2023; 39 (4): 373-376.

Corresponding Author

Arif Hakan Demirel

E-mail: ahakandemirel@hotmail.com

Received: 23.06.2023

Accepted: 30.08.2023

Available Online Date: 29.12.2023

© Copyright 2023 by Turkish Surgical Society Available online at www.turkjsurg.com

DOI: 10.47717/turkjsurg.2023.6154

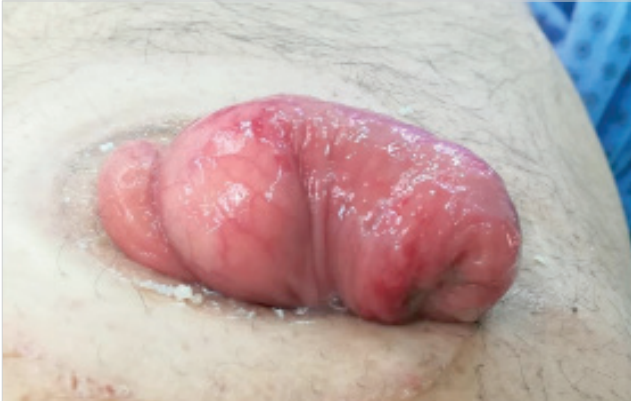

Figure 1. Stoma prolapse observed in sigmoid loop colostomy.

anesthesia was applied around the colostomy. The pressure was applied on the colostomy section protruding from the stoma, and it was sent into the abdomen, and the lumen was checked with a touch. Four 1 cm radial incisions were made around the colostomy, and a circumferential tunnel was created on the fascia around the stoma using these incisions (Figure 2). A silicone vessel tape with a diameter of 5 mm was placed in the tunnel in a double layer surrounding the stoma. In order to prevent the recurrence of the prolapse and not have difficulty in defecation, the vascular tape was adjusted to cover the index finger (new stoma diameter, approximately 1.7 cm) and tied with a silk suture, the skin incisions were closed, and the operation was terminated. Postoperative pain was minimal, and the patient was discharged on the same day, with continued oral nutrition in the form of watery food. The patient had mild abdominal distension and difficulty defecating on the second postoperative day, oral intake was restricted, and the colostomy started to work 48 hours later. No obstruction, recurrence of prolapse, or other complications developed at the 26-month follow-up (Figure 3). The perineum of the patient, who is currently in the terminal period, is in a necrotic state, and a bladder fistula has developed into the wound. However, the patient's oral feeding continues, and the colostomy works well after the revision procedure called the *peristomal cerclage*.

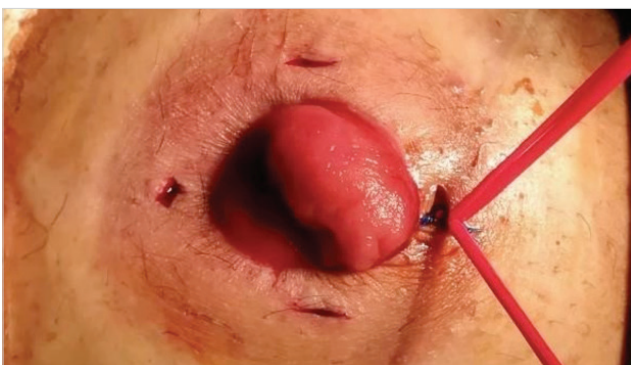


Figure 2. Application of "peristomal cerclage" technique.

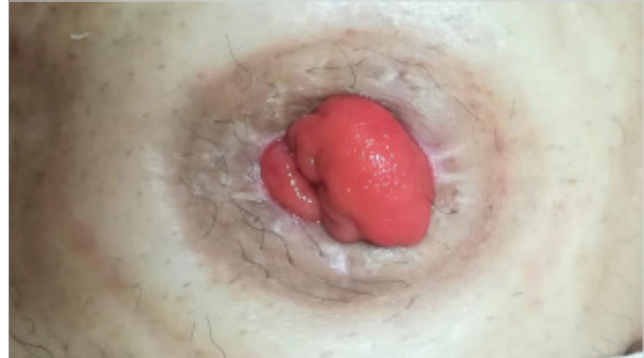

Figure 3. Appearance six months after revision of stoma prolapse.

DISCUSSION

The overall complication rate after stoma construction is between 21-70% (2,3,7). Colostomy prolapse is one of the most common late complications. The incidence rates are 2-26% and depend on long-term follow-up (7,8). Stoma prolapse is most common in transverse loop colostomies and relatively less common in end colostomies and extraperitoneal colostomies (2,7,9). Distal obstruction is important among the etiological factors (1). In addition to obesity and increased intra-abdominal pressure, there are factors such as the excessively large opening of the fascial defect and the redundant and tortuous nature of the proximal sigmoid colon (7). Asymptomatic or minimally symptomatic patients are initially approached conservatively; no intervention is required unless complications develop. However, surgical treatment can be planned if the prolapse is severe, accompanied by parastomal hernia, and cosmetic problems or stoma care difficulties are in question. Rarely, intussusception and necrosis may develop in a prolapsed stoma, in which case urgent surgical intervention is required (10).

Surgical treatment can be performed with an abdominal or peristomal approach. In the abdominal approach, resectioning the prolapsed colon and creating a new stoma is the definitive procedure (1). In the peristomal approach, the modified Altemeier procedure to resect the prolapsed bowel segment or the modified Delorme's procedure for mucosal resection/plication can be applied (4,11). Recently, local revision techniques have been defined with linear stapler devices, which shorten the operation time. Although this technique can be applied safely, it brings an additional cost (4,5,12).

Conservative interventions, which are also applied peristomal, such as placing the prolapsed loops in the abdomen and fixing them to the colostomy opening in the abdominal wall, have also been described, but recurrence is common in this technique (1,2,6).

The Thiersch procedure, a treatment method applied in patients who cannot handle general anesthesia and laparotomy in rectal prolapse, may be an alternative to use in colostomy

prolapse (13). This conservative method applied in rectal prolapses constituted a prototype for the *peristomal cerclage* technique we applied in our case. The described technique is a low-cost method that can be applied under local anesthesia, is minimally invasive, does not require a stapler device, and is applied only with vessel tape. During the patient's long-term follow-up of 26 months, it functioned as a satisfactory definitive treatment method. The Sao Paulo study, similar to this method, was applied in 10 male patients, and a polypropylene mesh strip was used peristomal, and no recurrence was observed in the applied cases (14). Since the material they use is not elastic and healing is by fibrosis, this technique may cause colostomy stricture in the long term. The vascular tape we use is a silicone material used in the seton treatment of anal fistulas, and it is an important advantage that it does not cause fibrosis around the stoma. In addition, it is preferable due to its stretching feature during passive defecation from the colostomy. However, this procedure is not suitable for ischemic or ulcerated prolapse cases due to the risk of necrosis and perforation.

CONCLUSION

Peristomal cerclage, which is applied under local anesthesia and with daily hospitalization to repair colostomy prolapse, was defined in this report. This technique can be applied in suitable cases due to its advantages, such as satisfactory postoperative recovery, low cost, and no recurrence and complications in the present case in the long postoperative period of 26 months.

Peer-review: Externally peer-reviewed.

Author Contributions: Concept - AHD; Design - SA; Supervision - AHD; Data Collection and/or Processing - İK, SA, RA; Analysis and/or Interpretation - RA; Literature Search - SA, İK; Writing Manuscript - SA, AHD; Critical Reviews - AHD.

Conflict of Interest: The authors have no conflicts of interest to declare.

Financial Disclosure: The authors declared that this study has received no financial support.

REFERENCES

1. Harford FJ, Harford DS. (1997) *Intestinal Stomas*. In: Beck DE. *Handbook of Colorectal Surgery*, St Louis, Missouri, Quality Medical Publishing, pp: 105-25.
2. Gordon PH, Rolstad BS, Bublick MP. (1999) *Intestinal Stomas*. In: Gordon PH, Nivatvongs V. *Principles and Practice of Surgery for the Colon, Rectum, and Anus*, St Louis, Missouri, Quality Medical Publishing, pp: 1117-231.
3. Park JJ, Del Pino A, Orsay CP, Nelson RL, Pearl RK, Cintron JR, et al. *Stoma complications*. *Dis Colon Rectum* 1999; 42(12): 1575-80. <https://doi.org/10.1007/BF02236210>
4. Papadopoulos V, Bangeas P, Xanthopoulou K, Paramythiotis D, Michalopoulos A. *Stoma prolapse handmade repair under local anesthesia with variation in the Altemeier method in severe patients: A case report and review of the literature*. *J Surg Case Rep* 2017; 2017(2): rjx027. <https://doi.org/10.1093/jscr/rjx027>
5. Monette MM, Harney RT, Morris MS, Chu DI. *Local repair of stoma prolapse: Case report of an in vivo application of linear stapler devices*. *Ann Med Surg (Lond)* 2016; 11: 32-5. <https://doi.org/10.1016/j.amsu.2016.08.018>
6. Zinkin LD, Rosin JD. *Button colopexy for colostomy prolapse*. *Surg Gynecol Obstet* 1981; 152(1): 89-90.
7. Shabbir J, Britton DC. *Stoma complications: A literature overview*. *Colorectal Dis* 2010; 12(10): 958-64. <https://doi.org/10.1111/j.1463-1318.2009.02006.x>
8. Husain SG, Cataldo TE. (2008) *Late stomal complications*. *Clin Colon Rectal Surg* 2008; 21(1): 31-40. <https://doi.org/10.1055/s-2008-1055319>
9. Londono-Schimmer EE, Leong AP, Philips RK. *Life table analysis of stomal complications following colostomy*. *Dis Colon Rectum* 1994; 37(9): 916-20. <https://doi.org/10.1007/BF02052598>
10. Alquraish FA, Ibrahim AH, Alshammari T. *Appendix and ascending colon intussusception through a prolapsed transverse colostomy: A case report with literature review*. *Int J Surg Case Rep* 2022; 98: 107549. <https://doi.org/10.1016/j.ijscr.2022.107549>
11. Abulafi AM, Sherman IW, Fiddian RV. *Delorme operation for prolapsed colostomy*. *Br J Surg* 1989; 76(12): 1321-2. <https://doi.org/10.1002/bjs.1800761234>
12. Masumori K, Maeda K, Koide Y, Hanai T, Sato H, Matsuoka H, et al. *Simple excision and closure of a distal limb of loop colostomy prolapse by stapler device*. *Tech Coloproctol* 2012; 16(2): 143-5. <https://doi.org/10.1007/s10151-011-0785-2>
13. Dody G. (1996) *Rectal Prolapse*. In: Dody G, Spencer RJ. eds. *Outpatient Coloproctology, Textbook and Color Atlas*, Padova, Piccin Nuova Libraria, pp: 336-51.
14. Sobrado Junior CW, Guzela VR, Sobrado LF, Nahas SC, Cecconello I. *Local treatment of colostomy prolapse with the mesh strip technique: A novel and highly efficient day hospital technique*. *Clinics (Sao Paulo)* 2020; 75: e1353. <https://doi.org/10.6061/clinics/2020/e1353>

**TEKNİK SUNUM-ÖZET**

Turk J Surg 2023; 39 (4): 373-376

Damar teypini kullanarak “peristomal serklaj” yöntemiyle stoma prolapsusunun onarımı

Arif Hakan Demirel, İbrahim Kurtođlu, Saygın Altınar, Recep Aydın

Ankara Eğitim ve Araştırma Hastanesi, Genel Cerrahi Kliniđi, Ankara, Türkiye

ÖZET

Stoma prolapsusu, stoma yapımını takiben en sık görülen geç komplikasyonlardan biridir. Prolapsuslar konservatif olarak tedavi edilebilmelerine rağmen, sıklıkla cerrahi revizyon gerektirirler. Bu çalışmada, stoma prolapsusunu tedavi etmek için lokal anestezi ile uygulanan “peristomal serklaj” adı verilen bir revizyon yöntemi tanımlanmıştır. Örnek olguda ileri rektum kanseri olan 66 yaşındaki erkek hastaya bir yıl önce distalde tıkaçıcı tümör nedeniyle sigmoid loop kolostomi açılmıştı. Ameliyat sonrası gelişen kolostomi prolapsusunun revizyonu planlandı. Lokal anestezi altında 12 cm’lik prolapsus batın içine redükte edildikten sonra subkutan yerleştirilen damar teypinin peristomal sarılması şeklinde bir onarım yapıldı; kısa süreli batın distansiyonu dışında hastada herhangi bir komplikasyon gelişmedi. Hasta şu anda postoperatif 26. ay ve terminal dönemdedir ve kolostomisi normal olarak çalışmaktadır. Bu çalışma, stoma prolapsusu olan hastalara uygulanan minimal invaziv bir revizyon prosedürü olan peristomal serklaj yöntemini tanımlamayı ve uzun dönem sonuçlarını bildirmeyi amaçlamaktadır. Bu yöntemin daha yaygın kullanımı ile elde edilen sonuçların bildirilmesi önemlidir.

Anahtar Kelimeler: Stoma, kolostomi, prolapsus, serklaj**DOI:** 10.47717/turkjsurg.2023.6154