









Adult idiopathic hypertrophic pyloric stenosis presenting with gastroduodenal intussusception: A rare case report

Loo Guo Hou¹ , Baharudin Nadia Nafasha¹ , Hameed Sultan Mohamed Arif¹ , Rajan Reynu¹ , Ritza Kosai Nik¹ ,
Rasul Hamidi Lizawati² 

¹ Department of General Surgery, National University of Malaysia Faculty of Medicine, Bandar Tun Razak, Malaysia

² Department of Pathology, National University of Malaysia Faculty of Medicine, Bandar Tun Razak, Malaysia

ABSTRACT

Adult idiopathic hypertrophic pyloric stenosis (AIHPS) is a rare entity first described by Cruveilhier in 1835. There are only approximately 200 cases reported in the English literature to date. Histologically, it may be mistaken for spindle cell neoplasms such as gastrointestinal stromal tumour (GIST). Patients with AIHPS usually present with early satiety, abdominal fullness, postprandial vomiting, epigastric pain, and eructations. Adult intussusception is rare and only accounts for 5% of all intussusceptions. Gastroduodenal intussusception is one of the rare types of adult intussusception. This is more likely to occur when a benign or malignant stomach lesion acts as a lead point. We report a case of AIHPS in a 70-year-old lady presenting with gastroduodenal intussusception. An oesophagogastroduodenoscopy (OGDS) was performed, and it revealed a diffusely thickened and narrowed pyloric antrum. A contrasted computed tomography (CECT) of the thorax and abdomen showed a distended stomach with circumferential thickening of the pylorus. The pre-pyloric antrum was intussuscepting into the pylorus, and the apex is seen within the first part of duodenum. She underwent distal gastrectomy with a Roux-en-y reconstruction via laparoscopic approach and was discharged well. AIHPS is a rare condition and should be a differential in adults presenting with gastric outlet obstruction. We believe in cases of AIHPS presenting with gastroduodenal intussusception, a distal gastrectomy with reconstruction is a reasonable approach. A multidisciplinary approach is essential to obtain the best outcome.

Keywords: AIHPS, distal gastrectomy, adult intussusception, GIST, primary AIHPS

INTRODUCTION

Adult idiopathic hypertrophic pyloric stenosis (AIHPS) is a rare entity first described by Cruveilhier in 1835 (1). The primary or idiopathic form has no discernable predisposing factor while the more common secondary form is triggered by other diseases of the upper gastrointestinal tract (2,3). It is important to note that while recognizing malignant cells is often uncomplicated, spindle cell neoplasms such as gastrointestinal stromal tumour (GIST) might be challenging to differentiate from AIHPS (2).

Adult intussusception is rare and only accounts for 5% of all intussusceptions (4). Gastroduodenal intussusception is one of the rare types of adult intussusception, accounting for only 10% of cases (4). With this in mind, we report the first case of AIHPS presenting with gastroduodenal intussusception. This case has been reported in line with the SCARE criteria (5).

CASE REPORT

A healthy 70-year-old woman presented to us with reduced effort tolerance and intermittent vomiting for the past three months. It was associated with central abdominal pain, and she has progressive early satiety for the past month. Upon further history, she claims to have intermittent maelenic bowel movements as well for the past one year. She had an unintentional weight loss of three kg in the past year as well. On clinical examination, she was pale but otherwise normotensive. Her abdominal examination was unremarkable and digital rectal examination showed brownish stools. Her blood investigation revealed a haemoglobin level of 49 g/L (microcytic hypochromic picture), and she was admitted for further assessment and blood transfusion.

Cite this article as: Hou LG, Nafasha BN, Arif HSM, Reynu R, Nik RK, Lizawati RH. Adult idiopathic hypertrophic pyloric stenosis presenting with gastroduodenal intussusception: A rare case report. Turk J Surg 2023; 39 (4): 377-382.

Corresponding Author

Loo Guo Hou

E-mail: looguohou@gmail.com

Received: 12.06.2019

Accepted: 05.05.2020

Available Online Date: 29.12.2023

© Copyright 2023 by Turkish Surgical Society Available online at www.turkjsurg.com

DOI: 10.47717/turkjsurg.2023.4552

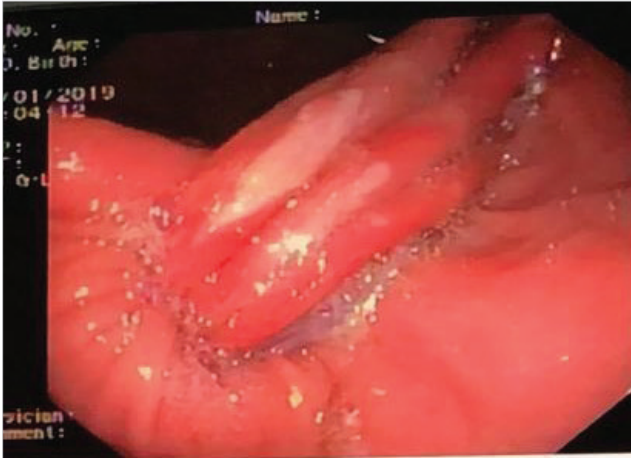

Figure 1. Upper endoscopy still images of stomach showing edematous pyloric mucosa intussuscepting into the first part of duodenum.

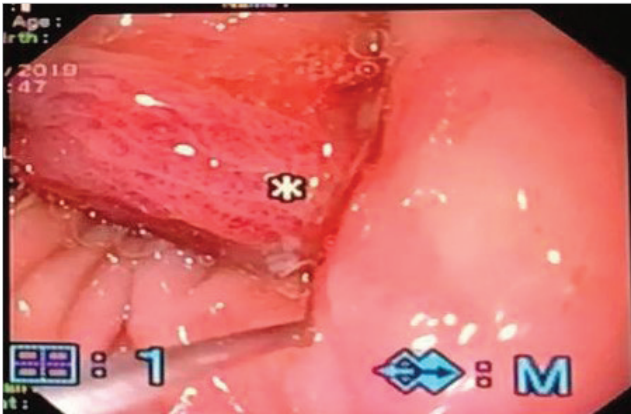


Figure 2. Upper endoscopy still images of stomach showing edematous pyloric mucosa intussuscepting into the first part of duodenum.

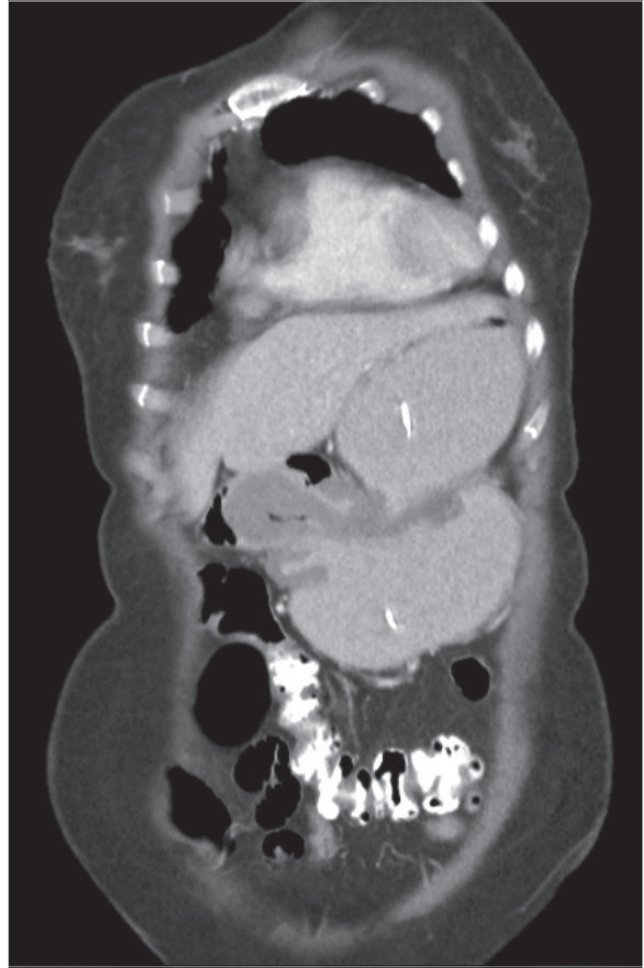


Figure 3. Coronal view of the CECT of the abdomen showing a distended stomach with circumferential thickening of the pylorus measuring 1.6 cm.

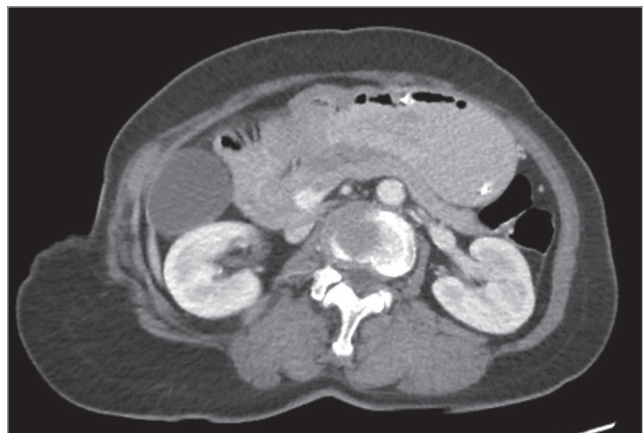


Figure 4. Axial and sagittal view of CECT of the abdomen showing pre-pyloric antrum intussuscepting into the pylorus, and the apex is seen within the first part of duodenum.

An oesophagogastroduodenoscopy (OGDS) was performed, and it revealed a distorted anatomy of the stomach. The pyloric antrum was diffusely thickened and oedematous with its mucosa intussuscepting into the first part of duodenum (Figures 1,2). We were unable to perform duodenal intubation because of that. A presumptive diagnosis of the pre-pyloric gastric tumour was made. Tissue biopsy taken from the pre-pyloric antrum suggested it to be a GIST with the background of chronic active gastritis. A contrasted computed tomography (CECT) of the thorax and abdomen was done, and it showed a distended stomach with circumferential thickening of the pylorus measuring 1.6 cm (Figure 3). The pre-pyloric antrum was intussuscepting into the pylorus, and the apex is seen within the first part of duodenum (Figures 4,5). There were no suspicious features from the soft tissue mass, and there was no distant metastasis seen.

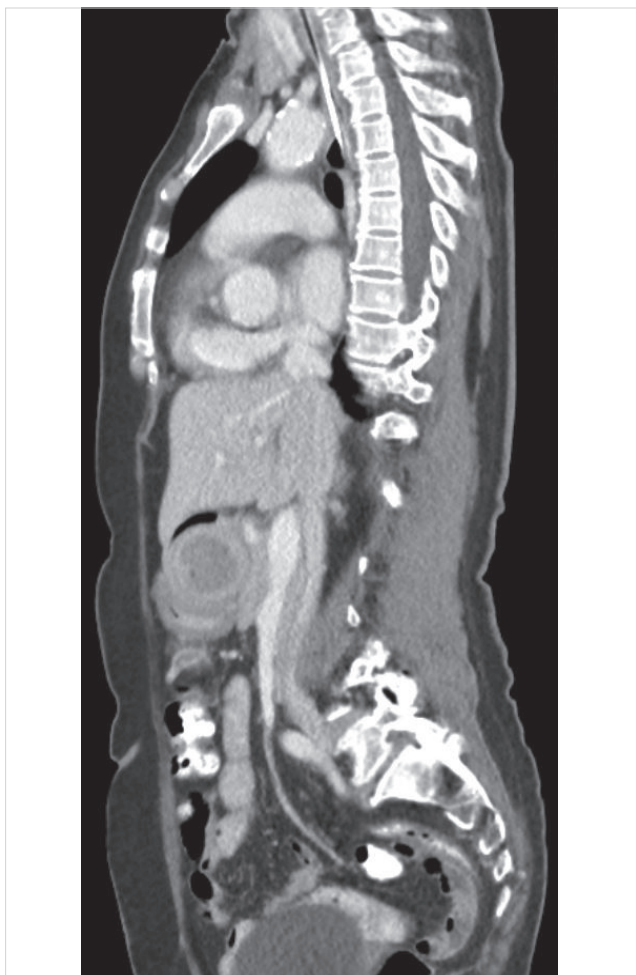

Figure 5. Axial and sagittal view of CECT of the abdomen showing pre-pyloric antrum intussuscepting into the pylorus, and the apex is seen within the first part of duodenum.

After a multidisciplinary meeting, we performed a distal gastrectomy with a Roux-en-y reconstruction via a laparoscopic approach. Her postoperative recovery was complicated with acute coronary syndrome, which required care in the intensive care unit for two days. She was subsequently discharged well on postoperative day nine. The histopathological report of the resected specimen did not show any GIST cells. The circumferential thickened pylorus showed hypertrophied circular layer of the muscularis propria with evidence of acute and chronic inflammatory cells infiltration. The duodenal mucosa showed eroded mucosa with congested blood vessels. There are no surface ulcerations, neutrophils, crypt abscess or evidence of malignancy (Figure 6,7). With the final pathology report, we came to the diagnosis of AIHPS causing gastroduodenal intussusception. During her last follow up at the outpatient clinic, she remained well and asymptomatic.

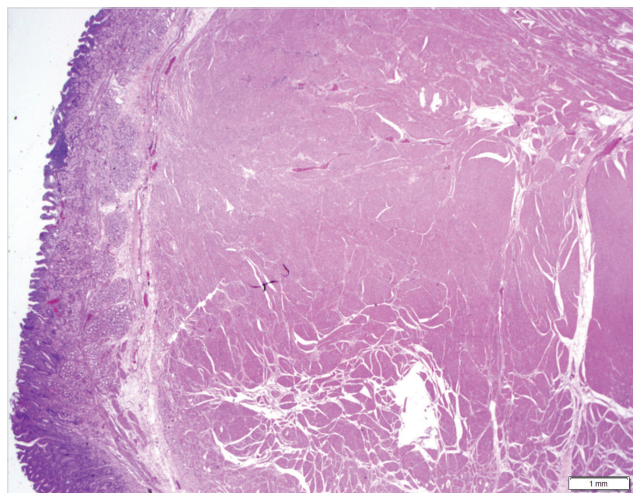


Figure 6. Microscopic examination of the sections from thickened pylorus at 1.25x and 20x magnification show hypertrophied circular layer of the muscularis propria mildly infiltrated with acute and chronic inflammatory cells.

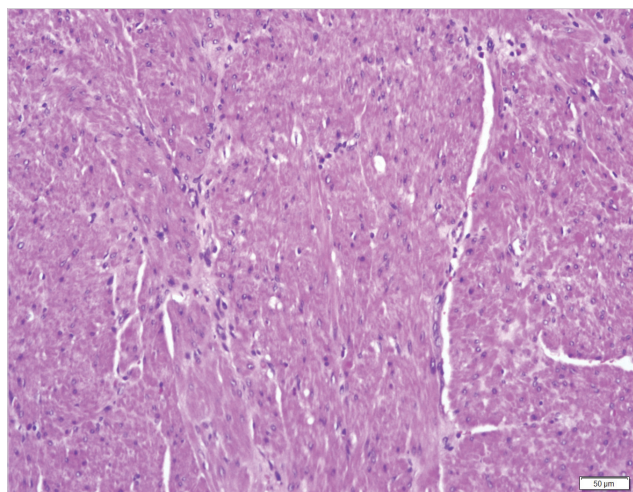


Figure 7. Microscopic examination of the sections from thickened pylorus at 1.25x and 20x magnification show hypertrophied circular layer of the muscularis propria mildly infiltrated with acute and chronic inflammatory cells.

DISCUSSION

AIHPS is a rare entity first described by Cruveilhier in 1835 (1). There are only approximately 200 cases reported in the English literature to date (2). The commonly accepted etiological classification is into a primary and secondary form (2). The primary or idiopathic form has no discernable predisposing factor while the more common secondary form is triggered by other diseases of the upper gastrointestinal tract (2,3). These include excessive healing of previous gastric or proximal duodenal ulcers, GIST, vagal hyperactivity, previous operation causing extrinsic adhesions, carcinoma and bezoars (2).

On microscopic examination, the primary form demonstrates substantial hypertrophy of the pyloric muscles while in the secondary form, there is localized replacement by fibrous tissues, with scanty or no smooth muscle hypertrophy. Differentiation of these two forms is usually the task of the pathologist. It is important to note that while recognizing malignant cells is often uncomplicated, spindle cell neoplasms such as GIST might be challenging to differentiate from AIHPS (2). As in our case, it is possible that the initial tissue biopsy was mistaken for GIST.

Intussusception is defined as an invagination of one part of the gastrointestinal tract into another. Adult intussusception only accounts for 5% of all intussusceptions (4). Unlike intussusception in children, 80-90% of intussusception in adults have an identifiable cause (6). Gastroduodenal intussusception is one of the rare types of adult intussusception, accounting for only 10% of cases (4). It occurs when part of the stomach invaginates through the pylorus into the duodenum (7). Various pathologies such as an inflammatory fibrinoid polyp, hamartoma, adenoma, leiomyoma, lipoma, adenocarcinoma and leiomyosarcoma may serve as a lead point (4,6,7). In a review of gastroduodenal intussusception caused by gastric tumours, it was found that epithelial tumours cause almost 70% (8). To the best of our knowledge, this is the first reported case of AIHPS causing gastroduodenal intussusception.

Patients with AIHPS usually present with early satiety, abdominal fullness, postprandial vomiting, epigastric pain, and eructations (9,10). Associated anorexia and unintentional weight loss are also common (11). An uncommon presenting complaint of our patient is symptomatic iron deficiency anemia, which is a more common complaint seen in GIST (8). We postulated this might have occurred due to three reasons. The first reason is that our patient was malnourished due to inadequate dietary intake, which is caused by the existing AIHPS leading to chronic gastric outlet obstruction. The concomitant gastroduodenal intussusception, which may cause mucosal ulceration due to pressure necrosis, may lead to blood loss as well. Microscopic examination of the resected duodenal mucosa did show erosion suggestive of ischemia. Lastly, iron absorption takes place predominantly at the duodenum and upper jejunum. As our patient has gastroduodenal intussusception, this might have interfered with the dietary iron absorption.

The diagnosis of AIHPS is made based on clinical history, examination, upper endoscopic examination, imaging studies and tissue biopsy (12). Abdominal examination is usually unremarkable unless the stomach is dilated, unlike its juvenile counterpart where an "olive sign" can be elicited (10,11). An OGDS examination is essential for a thorough visual inspection of the upper gastrointestinal tract. A fixed, narrow pylorus with a smooth border has been described as cervix sign may be seen. This sign persists after anticholinergic therapy and can be differentiated from pylorospasm when pressure is applied via

OGDS (13). Often, duodenal intubation can be challenging with a standard gastroscope (10). Endoscopic findings are non-specific for AIHPS as it may be mistaken for GIST or diffusely infiltrating adenocarcinoma due to the normal appearing mucosa (11). Tissue biopsy is therefore essential, but as the gastric mucosa is normal, submucosal malignancy cannot be ruled out (11).

Various imaging modalities have been employed to aid the diagnosis of AIHPS. This includes plain radiographs, upper gastrointestinal contrast studies, CECT of the abdomen, and video capsule endoscopy. Plain radiographs of the abdomen may show a distended stomach, mottled appearance of gastric content, an indentation of gastric air shadow by the peristaltic wave and hypertrophy of the gastric rugae just proximal to the pylorus (14). The findings, however, are not specific to AIHPS and can be seen in any patient with gastric outlet obstruction (15). Kirklin or mushroom sign, a convex indentation at the duodenal bulb base, if present, is highly suggestive of AIHPS (12).

Upper GI contrast studies if performed, frequently show delayed gastric emptying with an elongated pyloric canal and a distended stomach (15). CECT of the abdomen is essential to exclude secondary causes of gastric wall thickening such as malignancy or GIST. In AIHPS, a CECT scan may show thickening of the distal gastric wall, but it is non-specific (9,15). In our case, a CECT helped us diagnose the pyloric wall thickening as well as the resulting gastroduodenal intussusception, although, at that time, a pyloric tumour was our likely diagnosis. Of note, CT enterography, a modern diagnostic tool used for small bowel disorders, may be helpful in the diagnosis of AIHPS (10).

Surgical resection is the mainstay treatment for patients presenting with AIHPS. Various surgical procedures have been employed, and these include distal gastrectomy with Billroth I or II reconstruction, gastroenterostomy, and pyloromyotomy with or without pyloroplasty (3,11,15). A more conservative endoscopic dilatation has also been attempted, but these ultimately result in a recurrence (11,15). If a preoperative diagnosis of AIHPS can be accurately made, laparoscopic pyloroplasty is a safe and effective procedure, with less morbidity than a gastrectomy (3). In our case, however, the patient presents acutely with symptomatic gastroduodenal intussusception, and we are unable to exclude malignancy of the pylorus. Hence, a more extensive surgical resection is undertaken.

CONCLUSION

AIHPS is a rare condition and should be a differential in adults presenting with gastric outlet obstruction. In the treatment of AIHPS, it is suggested that laparoscopic pyloroplasty may be less invasive. We believe in cases of AIHPS presenting with gastroduodenal intussusception, a distal gastrectomy with reconstruction is a more reasonable approach. A multidisciplinary approach is essential in dealing with rare diseases, and tailored management is required to obtain the best outcome.

Peer-review: Externally peer-reviewed.

Author Contributions: Concept - RKN, RR; Design - RKN, LGH; Supervision - LGH, RR; Materials - LGH, RHL; Data Collection and/or Processing - LGH, BNN, HSMA, RHL; Analysis and/or Interpretation - LGH, BNN, HSMA; Literature Search - LGH, BNN, HL; Writing Manuscript - LGH, HSMA; Critical Reviews - RKN, RR.

Conflict of Interest: The authors have no conflicts of interest to declare.

Financial Disclosure: The authors declared that this study has received no financial support.

REFERENCES

1. Cruveilhier J. *Anatomie Pathologique du Corps Humain*. Paris: Bailliere; 1835.
2. Zarineh A, Leon ME, Saad RS, Silverman JF. Idiopathic hypertrophic pyloric stenosis in an adult, a potential mimic of gastric carcinoma. *Patholog Res Int* 2010; 2010: 614280. <https://doi.org/10.4061/2010/614280>
3. Danikas D, Geis WP, Ginalis EM, Gorcey SA, Stratoulis C. Laparoscopic pyloroplasty in idiopathic hypertrophic pyloric stenosis in an adult. *JSLS* 2000; 4(2): 173-5.
4. Stubenbord W, Thorbjarnarson B. Intussusception in adults. *Annals of Surgery* 1970; 172(2): 306-10. <https://doi.org/10.1097/0000658-197008000-00019>
5. Agha RA, Borrelli MR, Farwana R, Koshy K, Fowler A, Orgill DP. For the Scare Group. The SCARE 2018 statement: Updating consensus surgical Case Report (SCARE) Guidelines. *Int J Surg* 2018; 60: 132-6. <https://doi.org/10.1016/j.ijssu.2018.10.028>
6. Paskauskas S, Pavalkis D. Adult Intussusception. In: Lule G. *Current Concepts in Colonic Disorders*. Rijeka, Croatia: InTech; 2012. pp: 1-22. <https://doi.org/10.5772/25416>
7. Jameel ARA, Segamalai D, Murugaiyan G, Shanmugasundaram R, Obla NB. Gastroduodenal intussusception due to gastrointestinal stromal tumour (GIST). *J Clin Diagn Res* 2017; 11(8): PD09-PD10. <https://doi.org/10.7860/JCDR/2017/26292.10398>
8. Gyedu A, Reich SB, Hoyte Williams PE. Gastrointestinal stromal tumour presenting acutely as gastroduodenal intussusception. *Acta Chirurgica Belgica* 2011; 111(5): 327-8. <https://doi.org/10.1080/00015458.2011.11680764>
9. Hassan SM, Mubarik A, Muddassir S, Haq F. Adult idiopathic hypertrophic pyloric stenosis - a common presentation with an uncommon diagnosis. *J Community Hosp Intern Med Perspect* 2018; 8(2): 64-7. <https://doi.org/10.1080/20009666.2018.1444905>
10. Gurvits GE, Tan A, Volkov D. Video capsule endoscopy and CT enterography in diagnosing adult hypertrophic pyloric stenosis. *World J Gastroenterol* 2013; 19(37): 6292-5 <https://doi.org/10.3748/wjg.v19.i37.6292>
11. Richards S, Farrant G, McCarthy G. Adult idiopathic hypertrophic pyloric stenosis. *N Z Med J* 2016 1; 129(1437): 77-9.
12. Boules M, Corcelles R, Batayyah E, Rodriguez J, Kroh M. Adult idiopathic hypertrophic pyloric stenosis. *CRSLS e2014.00252*. <https://doi.org/10.4293/JSLS.2014.00252>
13. Schuster MM, Smith VM. The pyloric "cervix sign" in adult hypertrophic pyloric stenosis. *Gastrointest Endosc* 1970; 16: 210-1.
14. Holder J, Zinn D, Samin A. Adult-onset idiopathic hypertrophic pyloric stenosis associated with osteoglophonic dysplasia and HIV: Case report and review of literature. *Ultrasound Q*. 2017; 33(1): 77-81. <https://doi.org/10.1097/RUQ.0000000000000238>
15. Hsien Ping L, Yu Chiang L, Chen Yun K. Adult idiopathic hypertrophic pyloric stenosis. *J Formos Med Assoc* 2015; 114: 659-62. <https://doi.org/10.1016/j.jfma.2012.07.001>

**OLGU SUNUMU-ÖZET**

Turk J Surg 2023; 39 (4): 377-382

Gastroduodenal intussusepsiyon ile başvuran bir hastada görülen yetişkin idiyopatik hipertrofik pilor stenozu: Nadir bir olgu sunumuLoo Guo Hou¹, Baharudin Nadia Nafasha¹, Hameed Sultan Mohamed Arif¹, Rajan Reynu¹, Ritza Kosai Nik¹, Rasul Hamidi Lizawati²¹ Ulusal Malezya Üniversitesi Tıp Fakültesi, Genel Cerrahi Anabilim Dalı, Bandar Tun Razak, Malezya² Ulusal Malezya Üniversitesi Tıp Fakültesi, Patoloji Anabilim Dalı, Bandar Tun Razak, Malezya**ÖZET**

Yetişkin idiyopatik hipertrofik pilor stenozu (AIHPS), ilk olarak 1835 yılında Cruveilhier tarafından tarif edilen nadir bir durumdur. İngilizce yayımlanan literatürlerde bugüne kadar bildirilen yaklaşık 200 vaka vardır. Histolojik olarak, gastrointestinal stromal tümör gibi iğ hücre neoplazmalarıyla karıştırılabilir. AIHPS'li hastalarda genellikle erken doyunluk, karında dolgunluk, postprandiyal kusma, epigastrik ağrı ve geçirme şikayetleri görülür. Yetişkinlerde görülen intussusepsiyon nadirdir ve tüm intussusepsiyonların yalnızca %5'ini oluşturur. Gastroduodenal intussusepsiyon, nadir görülen yetişkin intussusepsiyon tiplerinden biridir. Bu durumun, benign veya malign bir mide lezyonu öncü bir odak oluşturduğunda ortaya çıkması daha olasıdır. Bu çalışmada, gastroduodenal intussusepsiyon ile başvuran 70 yaşında bir kadında gözlenen bir AIHPS vakasını sunuyoruz. Hastaya yapılan özofagogastroduodenoskopide yaygın olarak kalınlaşmış ve daralmış bir pilorik antrum saptandı. Kontrastlı bilgisayarlı tomografide, pilorda çevresel kalınlaşma ile birlikte dilate bir mide görüldü. Prepilorik antrum pilorun içine doğru invajine olmuş ve apeksi duodenumun ilk bölümünde görülüyordu. Laparoskopik yaklaşımla Roux-en-Y rekonstrüksiyonu ile distal gastrektomi yapıldı ve hasta iyilik haliyle taburcu edildi. AIHPS nadir görülen bir durumdur ve gastrik çıkış tıkanıklığı görülen erişkinlerde ayırıcı tanıda yer almalıdır. Gastroduodenal intussusepsiyon ile başvuran AIHPS vakalarında, rekonstrüksiyonun eşlik ettiği bir distal gastrektominin makul bir yaklaşım olduğuna inanıyoruz. En iyi sonucu elde etmek için multidisipliner bir yaklaşım esastır.

Anahtar Kelimeler: Yetişkin idiyopatik hipertrofik pilor stenozu, Roux-en-Y rekonstrüksiyonu ile distal gastrektomi, yetişkinlerde görülen intussusepsiyon, gastrointestinal stromal tümör

DOI: 10.47717/turkjsurg.2023.4552