



Radiofrequency ablation of metastatic lymph nodes in a patient requiring secondary operation for papillary thyroid carcinoma metastasis

Gizem Öner¹ , Beyza Özçınar² , Orhan Ağcaoğlu³ , Nihat Aksakal² , Artur Salmalıoğlu⁴ , Cem Yücel⁵ , Yeşim Erbil² 

¹ Multidisciplinary Oncologic Centre for Oncological Research, Antwerp University Hospital, Antwerp, Belgium

² Department of General Surgery, İstanbul University Faculty of Medicine, İstanbul, Türkiye

³ Department of General Surgery, Koç University Faculty of Medicine, İstanbul, Türkiye

⁴ Department of Radiology, İstanbul University Faculty of Medicine, İstanbul, Türkiye

⁵ Department of Radiology, Gazi University Faculty of Medicine, Ankara, Türkiye

ABSTRACT

Radiofrequency ablation is a minimally invasive modality performed as an alternative to surgery in patients with benign thyroid nodules and recurrent thyroid cancers. As far we know there is scant data regarding the safety of radiofrequency ablation for metastatic lymph nodes. In this report, our aim was to evaluate the safety and efficacy of radiofrequency ablation for metastatic lymph nodes in patients with recurrent papillary thyroid cancer metastasis. A 63-year old man, who underwent bilateral total thyroidectomy procedure in a different hospital with the diagnosis of papillary thyroid cancer one year ago, was diagnosed to have papillary thyroid cancer metastasis in single lymph nodes bilaterally in his follow-up. He underwent percutaneous radiofrequency ablation under ultrasound guidance. He was discharged home on post-operative day one uneventfully and his first control ultrasonography revealed a decrease in nodule size larger than 50% in right side of the neck and also the nodule in the left side disappeared. In conclusion, radiofrequency ablation is a safe and feasible technique for the treatment of metastatic lymph nodes in patients requiring secondary surgery due to papillary thyroid cancer metastasis.

Keywords: Radiofrequency ablation, recurrent thyroid cancer, lymph node, thyroid cancer metastases, ultrasound, complication

INTRODUCTION

Thyroid cancer is the most common endocrine malignancy and post-operative recurrence rates vary between 15% and 67% depending on the stage of the disease and the type of tumor. Cervical lymph node metastases are seen in up to 30% of patients with differentiated thyroid carcinoma (1). The treatment modalities for lymph node metastasis include surgical excision, irradiation, chemical injection and thermal ablation techniques (2). However, the literature is inconsistent as to which treatment is more effective for local recurrence or metastasis of thyroid carcinoma. Due to increased risk of damaging recurrent laryngeal nerves and parathyroid glands in secondary operations, it has been showed that, radiofrequency ablation (RFA) can be used alternative to surgery for treating thyroid cancers. In addition to less invasiveness and reduction of morbidity, it has been noted that even repeated RFA did not increase the complication rate (3).

The aim of this case report is to evaluate the safety and effectiveness of RFA in the treatment of metastatic lymph nodes in patients with metastatic papillary thyroid cancer.

CASE REPORT

A 63-year-old male patient underwent bilateral total thyroidectomy for the papillary thyroid cancer in another hospital. There was multicentric papillary cancer detected one cm in right lobe and 0.6 cm in the left lobe with thyroid capsule invasion. His thyroglobulin (TG) level was 0.057 ng/mL after surgery. He did not take radioactive iodine treatment (RAI) after surgery. One year later, during his follow-up imaging studies, ultrasonography (US) revealed a 12.8 x 10.4 x 9.2 mm sized patho-

Cite this article as: Öner G, Özçınar B, Ağcaoğlu O, Aksakal N, Salmalıoğlu A, Yücel C, et al. Radiofrequency ablation of metastatic lymph nodes in a patient requiring secondary operation for papillary thyroid carcinoma metastasis. Turk J Surg 2024; 40 (2): 174-177.

Corresponding Author

Gizem Öner

E-mail: onergizem@hotmail.com

Received: 11.10.2019

Accepted: 07.06.2020

Available Online Date: 20.01.2023

© Copyright 2024 by Turkish Surgical Society Available online at www.turkjsurg.com

DOI: 10.47717/turkjsurg.2023.4631

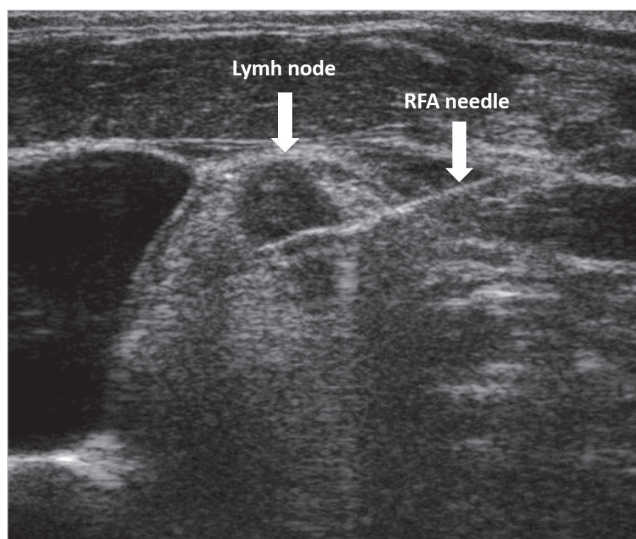


Figure 1. Ultrasonography image showing the metastatic lymph node that was adjacent to the jugular vein and radiofrequency needle.

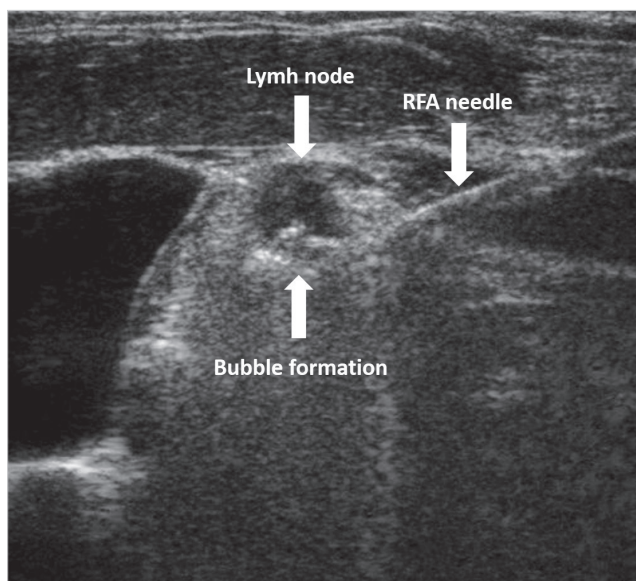


Figure 2. Ultrasonography image showing the bubbling effect due to ablation on the inferior part of the lymph node that was adjacent to the jugular vein.

logic lymph node in left neck region 4-5b junction. In addition, a 9.8 mm diameter pathologic lymph node that was adjacent to the jugular vein was detected in the right side of the neck. Fine needle aspiration biopsy result revealed papillary thyroid cancer metastasis. His TG level was 0.052 ng/mL and anti Tg level was 608 IU/mL. The risk and complications were discussed with the patient for bilateral central and lateral lymph node dissection and RFA was performed because the patient did not accept the surgery. He underwent radiofrequency ablation under ultrasound guidance and discharged home on the first day after

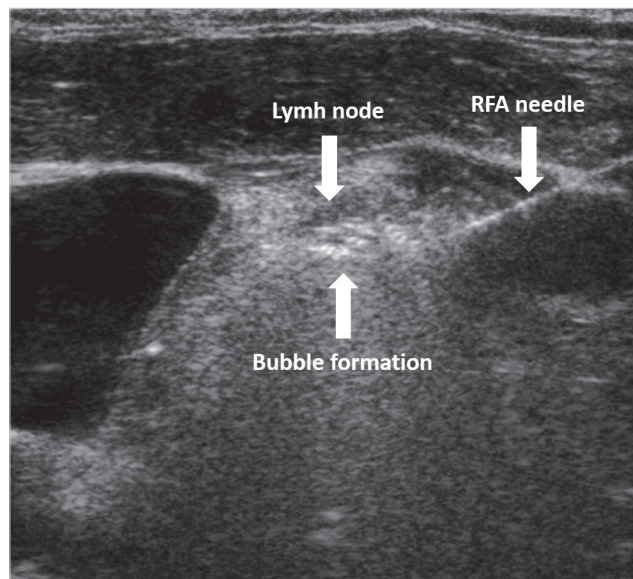


Figure 3. Ultrasonography image showing the complete ablation of the lymph node.

RFA uneventfully, there was no voice change or loss after the procedure and in his first control US revealed that the nodules disappeared. His last TG level was 0.04 ng/mL.

RFA Technique

RFA was performed by an interventional radiologist experienced in RFA procedures. During the ablation process an RF generator (Viva RF System-StarMed/Korea) and an 18 G, 7 mm RF electrode (star RF electrode-StarMed/Korea) were used (Figure 1-3). No complications were observed during or after the procedure. The control US performed one month after the procedure showed that the nodule on the right side of the neck decreased more than 50%, while the nodule on the left side of the neck completely disappeared. Thyroglobulin level was measured as 0.04 ng/mL. Both pathological lymph nodes disappeared completely during the follow-up after RFA.

DISCUSSION

Surgical resection is the gold standard for the treatment of malignant tumors but surgical resection is not always a preferable option for patients such as metastatic disease or in whom resection is associated with a high morbidity and mortality. Recently, a variety of minimally invasive local ablative methods, including chemical (ethanol, acetic acid) and thermal ablation (laser ablation, cryoablation, radiofrequency ablation, and microwave ablation) have been used as treatment options to eliminate cancer cells. The first use of ethanol ablation as an alternative treatment modality was reported by Rozman et al. in 1989 (4). Ethanol ablation is an effective method for the treatment of cystic nodules, but is less effective for solid nodules. Previous studies have reported that the efficacy of ethanol ablation was 85-98% in cystic nodules and 38-47% in solid nodules (5).

In addition, multiple treatment sessions have associated with an increased risk of complications. Laser ablation is another method of choice for the treatment of thyroid nodules. However, when RFA and laser ablation techniques compared to each other, the safety and long-term volume reduction rate of RFA was superior to that of laser ablation. This is 90% in RFA versus 48% in laser ablation, as reported in the three-year follow-up data of two studies in the literature (6).

RFA was first used in the treatment of thyroid nodules in 2006. Due to its minimal invasive access and low complication rate, RFA is increasingly used for the treatment of benign and malignant thyroid cancers including recurrent thyroid cancers in the operation bed and lymph nodes (7).

The term radiofrequency refers to alternating electric current including low frequency (460-480 kHz) and long wavelength, which causes thermal coagulation necrosis by generating heat within a tumor mass. RFA differs from other local minimally invasive techniques. High frequency electrical currents are passed through an electrode in the needle and the electrode stimulates the ions in the tissue to produce frictional heat in RFA. As a result, clotting necrosis occurs.

The results of studies after RFA have shown mean nodule volume reduction of 56-93%, complete nodule disappearance of 42-58%, and decrease in the serum thyroglobulin level in the majority of the cases (3,8). Jeong et al. reported for 236 patients who underwent RFA for thyroid nodules a volume reduction of >50% in 91% and complete disappearance of nodules in 28% of the cases (9). On the other hand, incomplete treatments have been reported because of increased pain during the procedure, anterior calcifications of the nodule and closeness of the nodule to vagus nerve (3,8). Park et al. also indicated that the RFA procedure was not effective when the ablation area was surrendered by vascular sheath or there was massive calcification in a nodule (8). In addition, despite incomplete treatment, recurrence rates have been reported in 0 to 25% of patients in the literature (3).

US imaging is relevant for the characterization of the nodule and the evaluation of the surrounding important anatomical structures. Each diameter of a nodule should be measured by US in order to calculate nodule volume. Thermal damage of laryngeal nerve during the procedure should be checked by talking with patient during the procedure. In literature, reported complications related with RFA include pain, hemorrhage, voice change, skin burn, infection and nodule rupture. In our case we did not encounter any of these complications. In RFA of thyroid nodules, 1-2% lidocaine is used in most treatment centers without any premedication. On the other hand, Monchik et al. have reported the intravenous use of combination of fentanyl citrate and midazolam as a possible anesthetic (10). However, we believe that painkillers and anesthesia will delay early detection of complications by masking some symptoms during the proce-

cedure. Especially within lateral neck region, vagus nerve is one of the most important structures. The location of the nerve is usually posterior-lateral to common carotid artery and posteromedial to internal jugular vein that can easily detect by US. In our case, the metastatic lymph nodes were away from vagus nerve. In addition, we used the hydro-dissection technique during the procedure to prevent complications due to any variation in the nerve. The recurrent tumors in central neck region are usually close to, or attached to the trachea, esophagus or recurrent laryngeal nerve, so it is more difficult to perform RFA in central area than lateral region (3). In the literature, no complications were reported in the esophagus and trachea following RFA for recurrent thyroid cancer. In our case, RFA was easily applied because pathological lymph nodes were located in the bilateral neck region.

We recommend that the patients should be followed-up at the first, the sixth and the 12th month after RFA depending on the treated metastatic lymph nodes. The efficacy of RFA can be evaluated by volume reduction of the nodule and serum thyroglobulin concentrations (8,10).

CONCLUSION

In conclusion, we believe that RFA can be as effective as surgery with less risk of complications in selected patients for thyroid cancer treatment. RFA may be preferred as an alternative treatment option to surgery for eligible patients.

Informed Consent: Informed consent was obtained from patient who participated in this case.

Peer-review: Externally peer-reviewed.

Author Contributions: Concept - GÖ, BÖ, OA, NA, YE; Design - GÖ, BÖ, AS; Supervision - YE, CY, NA, BÖ; Materials - GÖ, BÖ, YE; Data Collection and/or Processing - GÖ, BÖ, OA, AS, NA; Analysis and/or Interpretation - GÖ, BÖ, OA; Literature Search - GÖ, BÖ, OA; Writing Manuscript - All of authors; Critical Reviews - All of authors.

Conflict of Interest: The authors have no conflicts of interest to declare.

Financial Disclosure: The authors declared that this study has received no financial support.

REFERENCES

1. Loh KC, Greenspan FS, Gee L, Miller TR, Yeo PP. Pathological tumor-node-metastasis (pTNM) staging for papillary and follicular thyroid carcinomas: A retrospective analysis of 700 patients. *J Clin Endocrinol Metab* 1997; 82: 3553-62. <https://doi.org/10.1210/jcem.82.11.4373>
2. Frasoldati A, Pesenti M, Gallo M, Caroggio A, Salvo D, Valcavi R. Diagnosis of neck recurrences in patients with differentiated thyroid carcinoma. *Cancer* 2003; 97: 90-6. <https://doi.org/10.1002/cncr.11031>
3. Baek JH, Kim YS, Sung JY, Choi H, Lee JH. Locoregional control of metastatic well-differentiated thyroid cancer by ultrasound-guided radiofrequency ablation. *AJR Am J Roentgenol* 2011; 197: W331-6. <https://doi.org/10.2214/AJR.10.5345>

4. Rozman B, Bence Zigman Z, Tomic Brzac H, Skreb F, Pavlinovic Z, Simonovic I. Sclerosation of thyroid cyst by ethanol. *Period Biol* 1989; 91: 453.
5. Kim JH, Lee HK, Lee JH, Ahn IM, Choi CG. Efficacy of sonographically guided percutaneous ethanol injection for treatment of thyroid cysts versus solid thyroid nodules. *AJR Am J Roentgenol* 2003; 180: 1723-6. <https://doi.org/10.2214/ajr.180.6.1801723>
6. Lim HK, Lee JH, Ha EJ, Sung JY, Kim JK, Baek JH. Radiofrequency ablation of benign non-functioning thyroid nodules: 4-year follow-up results for 111 patients. *Eur Radiol* 2013; 23: 1044-9. <https://doi.org/10.1007/s00330-012-2671-3>
7. Agcaoglu O, Aliyev S, Karabulut K, El-Gazzaz G, Aucejo F, Pelley R, et al. Complementary use of resection and radiofrequency ablation for the treatment of colorectal liver metastases: An analysis of 395 patients. *World J Surg* 2013; 37: 1333-9. <https://doi.org/10.1007/s00268-013-1981-1>
8. Park KW, Shin JH, Han BK, Ko EY, Chung JH. Inoperable symptomatic recurrent thyroid cancers: Preliminary result of radiofrequency ablation. *Ann Surg Oncol* 2011; 18: 2564-8. <https://doi.org/10.1245/s10434-011-1619-1>
9. Jeong WK, Baek JH, Rhim H, Kim YS, Kwak MS, Jeong HJ, et al. Radiofrequency ablation of benign thyroid nodules: Safety and imaging follow-up in 236 patients. *Eur Radiol* 2008; 18: 1244-50. <https://doi.org/10.1007/s00330-008-0880-6>
10. Monchik JM, Donatini G, Iannuccilli J, Dupuy DE. Radiofrequency ablation and percutaneous ethanol injection treatment for recurrent local and distant well-differentiated thyroid carcinoma. *Ann Surg* 2006; 244: 296-304. <https://doi.org/10.1097/01.sla.0000217685.85467.2d>



OLGU SUNUMU-ÖZET

Turk J Surg 2024; 40 (2): 174-177

Papiller tiroid karsinomi metastazlı hastada ikincil ameliyat yerine metastatik nodlarının radyofrekans ile ablasyonu

Gizem Öner¹, Beyza Özçınar², Orhan Ağcaoğlu³, Nihat Aksakal², Artur Salmaslıoğlu⁴, Cem Yücel⁵, Yeşim Erbil²

¹ Antwerp Üniversitesi Hastanesi, Onkolojik Araştırmalar İçin Multidisipliner Onkoloji Merkezi, Antwerp, Belçika

² İstanbul Üniversitesi Tıp Fakültesi, Genel Cerrahi Anabilim Dalı, İstanbul, Türkiye

³ Koç Üniversitesi Tıp Fakültesi, Genel Cerrahi Anabilim Dalı, İstanbul, Türkiye

⁴ Koç Üniversitesi Tıp Fakültesi, Radyoloji Anabilim Dalı, İstanbul, Türkiye

⁵ Gazi Üniversitesi Tıp Fakültesi, Radyoloji Anabilim Dalı, Ankara, Türkiye

ÖZET

Radyofrekans ablasyonu, iyi huylu tiroid nodülü ve tekrarlayan tiroid kanserli hastalarda ameliyata alternatif olarak uygulanan minimal invaziv bir yöntemdir. Metastatik lenf nodları için radyofrekans ablasyon tedavisinin etkinliğine ilişkin az veri bulunmaktadır. Bu yazı, tekrarlayan papiller tiroid kanseri metastazı olan hastalarda metastatik lenf nodları için radyofrekans ablasyonun güvenliğini ve etkinliğini değerlendirmektedir. Bir yıl önce papiller tiroid kanseri tanısıyla farklı bir hastanede bilateral total tiroidektomi işlemi uygulanan 63 yaşında bir erkek hastanın kontrolleri sırasında bilateral lenf nodlarında papiller tiroid kanseri metastazı saptandı. Ultrason eşliğinde perkütan radyofrekans ablasyonu yapıldı. Hasta postoperatif birinci günde sorunsuz bir şekilde taburcu edildi ve ilk kontrol ultrasonografisinde nodül boyutunda boynun sağ tarafında %50'den daha büyük bir azalma olduğu ve sol taraftaki nodülün kaybolduğu görüldü. Sonuç olarak, radyofrekans ablasyon, papiller tiroid kanseri metastazı nedeniyle sekonder cerrahi gerektiren hastalarda metastatik lenf nodlarının tedavisi için güvenli ve uygulanabilir bir tekniktir.

Anahtar Kelimeler: Radyofrekans ablasyonu, nüks tiroid kanseri, lenf nodu, tiroid kanseri metastazı, ultrason, komplikasyon

DOI: 10.47717/turksurg.2023.4631