

# Appendix mucocele mimicking a complex ovarian cyst

Rojbin Karakoyun Demirci<sup>1</sup>, Mani Habibi<sup>1</sup>, Barış Rafet Karakaş<sup>1</sup>, Hakan Buluş<sup>2</sup>, Muzaffer Akkoca<sup>2</sup>, Osman Zekai Öner<sup>1</sup>

## ABSTRACT

Appendiceal mucocele is a rare entity which is characterized by cystic dilatation due to abnormal accumulation of mucus in the lumen of the appendix. Patients are often diagnosed incidentally by abdominal screening or abdominal surgery for other causes. Pain in the right lower quadrant of the abdomen, which may present as acute or chronic appendicitis, is the most common symptom of appendix mucocele, when the patient is symptomatic. This study describes the case of a 26-year-old female for whom surgical intervention for a complex ovarian cyst was planned, but who instead underwent laparoscopic appendectomy because appendiceal mucocele was determined during laparoscopic exploration.

**Key Words:** Appendix, mucocele, cystadenoma

## INTRODUCTION

Appendiceal mucocele is a rare entity that is characterized by cystic dilatation in the lumen of the appendix. The diagnosis is often made based on clinical signs and symptoms of acute appendicitis or coincidentally via imaging methods when it is asymptomatic. However, it may rarely receive a definitive diagnosis before surgery in spite of all technical possibilities, and it may be encountered during abdominal surgery performed with another indication (1). This study presents a 26-year-old female patient who was operated on with the pre-diagnosis of complicated ovarian cyst and received laparoscopic appendectomy since appendiceal mucocele was observed during laparoscopic exploration.

## CASE PRESENTATION

The 26-year-old female patient, who had been under follow-up for the past six months by gynaecologists with the diagnosis of ovarian cyst due to cramp-like pain in the lower right abdominal quadrant, presented to the emergency service of our hospital with severe pain in her lower right quadrant. During her physical examination, no pathological signs were found apart from significant tenderness in the lower right quadrant. Her complete blood count and laboratory results were as follows: leucocyte: 10160/mm<sup>3</sup>, Hb: 12.9 g/dL, platelet: 225.000/mm<sup>3</sup>, β-hCG: 1.5, and the values for other parameters were found to be within normal ranges.

Since a 3 x 3 cm complicated cyst in the right ovary and para-ovarian free fluid were observed in the trans-vaginal ultrasound examination done by the gynaecologists, the patient was admitted to the gynaecology clinic for follow-up purposes. During her follow-up exams, the decision was taken to perform diagnostic laparoscopy since her tenderness in the lower right abdominal quadrant continued.

The patient was operated on under general anaesthesia; during exploration, bilateral adnexa and uterus were observed to appear normal. A mass originating from the appendix lateral to the cecum was identified and it was thought that the mass could be an appendiceal mucocele. It was decided to conduct laparoscopic appendectomy on the patient. The specimen was taken out of the abdomen within an endo-bag (Figure 1).

As a result of the pathological examination, the lesion was identified as a mucinous cystadenoma of the appendix with mild-moderate dysplasia (Figure 2). In the colonoscopic examination performed in the 1<sup>st</sup> post-operative month, no pathological findings were identified. In the follow-up examination in the 3<sup>rd</sup> post-operative month, no problems were identified.

## DISCUSSION

Appendiceal mucocele is a descriptive term referring to distention of the appendix with mucus, which develops secondary to mucinous cystadenoma (63%), mucosal hyperplasia (25%), mucinous cystad-

<sup>1</sup>Clinic of General Surgery, Antalya Training and Research Hospital, Antalya, Turkey

<sup>2</sup>Clinic of General Surgery, Keçiören Training and Research Hospital, Ankara, Turkey

### Address for Correspondence Dr. Muzaffer Akkoca

Clinic of General Surgery, Keçiören Training and Research Hospital, Ankara, Turkey  
Phone: +90 312 356 90 00  
e-mail: muzafferakk@gmail.com

Received: 22.01.2012

Accepted: 07.03.2012

Available Online Date: 28.05.2013

©Copyright 2015  
by Turkish Surgical Association

Available online at  
www.ulusalcerahidergisi.org

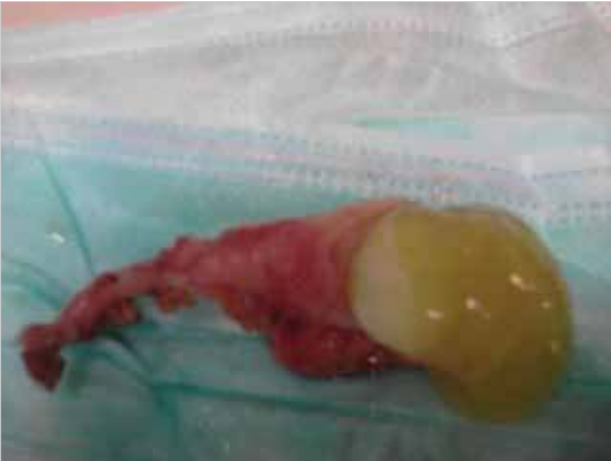

Figure 1. Macroscopic view of the mucocele

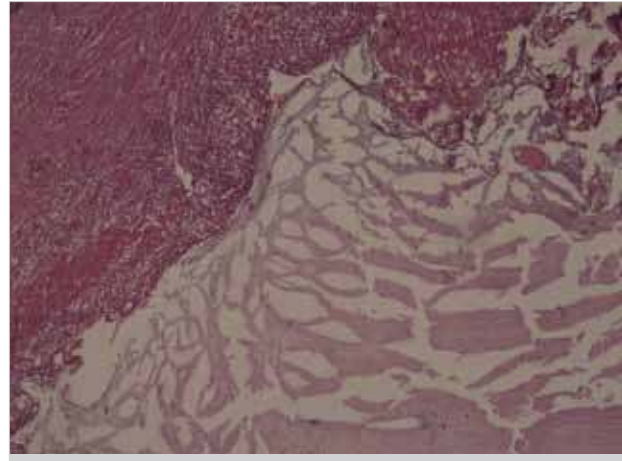


Figure 2. Microscopic view of the mucocele

enocarcinoma (11%) and retention cysts (1%) of the appendix lumen (2). Mucocele may also develop when the lumen is obstructed due to endometriosis or carcinoid tumors.

It is reported that the incidence of appendiceal mucocele in appendectomy specimens is 0.2-0.3% (3). Patients are generally above the age of 50, and it is 4 times more common among women (4). Approximately 25-30% of the patients are symptomatic, and it is incidentally identified during radiological studies, endoscopic examinations or surgery (3, 5). The most frequent manifestation among patients with symptomatic appendiceal mucocele is acute or chronic lower right quadrant pain (4). In our case, the patient was taken to surgery with a diagnosis of ovarian cyst rupture due to increase in lower right quadrant pain, which had been present for 6 months, and was diagnosed during laparoscopic exploration.

The mass may be palpated in the lower right quadrant in approximately half of the patients (6). Other symptoms include nausea, vomiting and change in bowel habits (7). It is difficult to correctly diagnose appendiceal mucocele before surgery due to non-specific symptoms (8, 17). Ultrasonography (US) and computerized tomography may aid in diagnosis. It is generally hypoechogenic in US; however, echogenicity may also be seen depending on the amount of acoustic interfaces caused by the mucus. The onion skin-like appearance is considered to be specific for appendiceal mucocele (9). Computerized tomography (CT) is more sensitive in recognizing and assessing appendiceal mucoceles. In CT, it is observed in the form of a cystic, encapsulated mass with a thin wall, which sometimes has mural calcifications, in the localization of the appendix (10).

There may be synchronous neoplasms with the appendiceal mucocele (11, 12). The most frequent synchronous neoplasm is that of the colon, however, it may also be present in other localizations such as gall bladder, breast, kidney, ovary and thyroid. In 19.4%-25.4% of the cases, appendiceal mucocele was found to be associated with colon adenocarcinoma (11). For that reason, cases identified to have appendiceal mucocele should be assessed carefully with regards to colon neoplasms. We also did not observe any pathology during the control colonoscopy performed in the post-operative 1<sup>st</sup> month on our patient, who did not have any signs related to neoplasm of the colon during laparoscopic exploration.

The treatment for appendiceal mucocele is surgery. Surgery may be performed via laparoscopy or laparotomy. It is important to be aware of the mucocele pre-operatively, and to avoid any manipulations during surgery, which may result in cystic rupture or leakage of the cystic fluid; because, a potential rupture during surgery may cause pseudomyxoma peritonei. The 5-year survival rate with pseudomyxoma peritonei due to mucinous cystadenocarcinoma may be as low as 20% (13). Therefore, there are some publications which oppose the use of laparoscopy in surgery for mucocele, while there are other publications emphasizing that laparoscopic surgery can be successfully performed (14, 15). The reported case results and literature indicate that there are no contraindications for laparoscopic surgery in appendiceal mucocele. However, caution should be exercised to prevent its rupture during laparoscopy (16). In our case, we took the decision to proceed with laparoscopic surgery after the identification of an appendiceal mucocele during laparoscopic exploration conducted in our patient by gynaecologists. We excised the appendix without rupture, with great care using gentle dissections and removed it from the abdomen without any contaminations within an endo-bag.

## CONCLUSION

Appendiceal mucocele is a rather rare entity and it does not have a specific clinical presentation. Therefore, it is not considered as part of the differential diagnosis of lower right quadrant pain, and it is difficult to reach a pre-operative diagnosis. Appendiceal mucocele should definitely be considered especially in cases where an elderly woman is observed to have a mass with atypical appearance in US or a mass is identified in the right iliac fossa. For this group of patients, laparoscopic excision performed with care following diagnostic laparoscopy may be a good option. Mucocele may often be associated with a concomitant colon cancer. Surgeons should always remember this and follow-up the patient with this in mind.

**Peer-review:** Externally peer-reviewed.

**Author Contributions:** Study concept and design - R.K.D.; Acquisition of data - M.H.; Analysis and interpretation of data - B.R.K.; Preparation of the manuscript - H.B., M.A.

**Conflict of Interest:** No conflict of interest was declared by the authors.

**Financial Disclosure:** The authors declared that this study has received no financial support.

## REFERENCES

1. Kılıc K, Arac M, Ozer S, Ozakpınar E. Appendiksin musinoz kistadenomu. Tanısal ve Girişimsel Radyoloji 2001; 7: 128-130.
2. Bartlett C, Manoharan M, Jackson A. Mucocele of the appendix-a diagnostic dilemma: a case report. J Med Case Rep 2007; 1: 183. [\[CrossRef\]](#)
3. Dachman AH, Lichtenstein LE, Friedman AC. Mucocele of the appendix and pseudomyxoma peritonei. Am J Roentgenol 1985; 144: 923-929. [\[CrossRef\]](#)
4. Minni F, Petrella M, Morganti A, Santini D. Giant mucocele of the appendix. Dis Colon Rectum 2001; 44: 1034-1036. [\[CrossRef\]](#)
5. Soweid AM, Clarkston WK, Andrus CH, Jannet CG. Diagnosis and management of appendiceal mucoceles. Dig Dis 1998; 16: 183-186. [\[CrossRef\]](#)
6. Coulier B, Pestieau S, Hamels J, Lefebvre Y. US and CT diagnosis of complete cecocolic intussusception caused by an appendiceal mucocele. Eur Radiol 2002; 12: 324-328. [\[CrossRef\]](#)
7. Carr NJ, McCarthy WF, Sobin LH. Epithelial non carcinoid tumors and tumor-like lesions of the appendix. A clinicopathologic study of 184 patients with a multivariate analysis of prognostic factors. Cancer 1995; 75: 757-768. [\[CrossRef\]](#)
8. Shukunami K, Kaneshima M, Kotsuji F. Preoperative diagnosis and radiographic findings of a freely movable mucocele of the vermiform appendix. Can Assoc Radiol J 2000; 51: 281-282.
9. Caspi B, Cassif E, Auslender R, Herman A, Hagay Z, Appelman Z. The onion skin sign: a specific sonographic marker of appendiceal mucocele. J Ultrasound Med 2004; 23: 117-121.
10. Fujiwara T, Hizuta A, Iwagaki H, Matsuno T, Hamada M, Tanaka N, et al. Appendiceal mucocele with concomitant colonic cancer. Report of two cases. Dis Colon Rectum 1996; 39: 232-236. [\[CrossRef\]](#)
11. Pitiakoudis M, Tsaroucha AK, Mimidis K, Polychronidis A, Minopoulos G, Simopoulos C. Mucocele of the appendix: a report of five cases. Tech Coloproctol 2004; 8: 109-112. [\[CrossRef\]](#)
12. Moreno SG, Shmookler BM, Sugarbaker PH. Appendiceal mucocele. Contraindication to laparoscopic appendectomy. Surg Endosc 1998; 12: 1177-1179. [\[CrossRef\]](#)
13. Chiu CC, Wei PL, Huang MT, Wang W, Chen TC, Lee WJ. Laparoscopic resection of appendiceal mucinous cystadenoma. J Laparosc Adv Surg Tech A 2005; 15: 325-328. [\[CrossRef\]](#)
14. Rangarajan, M. Palanivelu C, Kavalakat AJ, Parthasarathi R. Laparoscopic appendectomy for mucocele of the appendix: report of 8 cases. Indian J Gastroenterol 2006; 25: 256-257.
15. Navarra G, Asopa V, Basaglia E, Jones M, Jiao LR, Habib NA. Mucous cystadenoma of the appendix: is it safe to remove it by a laparoscopic approach? Surg Endosc 2003; 17: 833-834. [\[CrossRef\]](#)
16. Lau H, Yuen WK, Loong F, Lee F. Laparoscopic resection of an appendiceal mucocele. Surg Laparosc Endosc Percutan Tech 2002; 12: 367-370. [\[CrossRef\]](#)
17. Göksoy E, Geçioğlu A. Appendiks mukoseli: Olgu bildirisi. Cerrahpaşa Tıp Fak Derg 1990; 21: 129-132.