

The techniques of sphincter-saving extrasphincteric dissection and proximal segmental sphincteric excision in low rectal cancer surgery

Ali Naki Yücesoy

ABSTRACT

Objective: To define the techniques used in lower rectal cancer surgery, by transvaginal and transperineal approach; extrasphincteric dissection, proximal segmental sphincteric excision and transsphincteric rectal resection.

Material and Methods: Between 2007 and 2013, 7 patients (4 female, 3 male with lower rectal cancer were operated by sphincter-saving extrasphincteric dissection and proximal sphincteric excision techniques. After completion of the rectosigmoid dissection and total mesorectal excision up to the puborectal muscle level; extrasphincteric rectal dissection, transsphincteric rectal resection and ultra-low coloanal anastomosis were performed by using the transvaginal and transperineal approach in the sublevator phase of the operation.

Results: Seven patients were operated with sublevator access for lower rectal cancer. Bowel continuity has been provided in all patients. One patient died due to surgical complications in the early postoperative period. One patient developed anastomotic leakage and there were two patients with anastomotic stricture. Circumferential resection margin and tumoral perforation were found negative in all of the patients. Tumoral deposits at the distal resection line was observed in one patient.

Conclusion: The techniques of sublevator rectal resection may be considered as an alternative sphincter-saving surgical method, especially in lower rectal cancer surgery.

Key Words: Lower rectal cancer, sphincter-saving extrasphincteric dissection, proximal segmental sphincteric excision, transsphincteric rectal resection

INTRODUCTION

Colorectal cancer is the third most common tumor in men and women in the Western world, while it ranks as the second leading cause of cancer-related deaths (1). In approximately 25-30% of all cases of colorectal cancer, the tumor is located in the rectum (2), and in 70-80% of patients with rectal cancer it is located in the 2/3 of the rectum (3). In 90% of rectal cancer cases, the tumor is limited to the rectum and peri-rectal lymphatic tissue, thus surgical treatment is the primary option. Low rectal cancers have high rates of abdominoperineal resection and local recurrence as compared to those located in other parts (4, 5).

The rectum is approximately 20 cm in length from the anal verge, and is evaluated in three sections of equal length (upper, middle and lower) (6). The lower rectum can be divided into two sections depending on the level of the puborectal muscle as supralevator and sublevator. The sublevator section constitutes distal 2/3 of the lower rectum, and is approximately 4-6 cm long. Sublevator access enables direct vision of the rectal segment that is below the levator muscle and performing surgical procedures. The distal rectum at the sublevator level is completely surrounded by the external sphincter complex that is located perpendicularly and shaped as pulleys, forming two intertwined cylindrical muscular structure. According to the anatomy described by Ahmed Shafik (7), the upper and wide portion of the perpendicular seated pulley-like external sphincter complex is created by the puborectal muscle, the middle narrow portion is composed of the deep external anal sphincter muscle and the lower broad and wide portion formed by the superficial external anal sphincter muscle.

In lower rectum cancer surgery, the current surgical techniques are based on inter-sphincteric dissection described by Schiessel et al. (8). Rectal resections performed via the sublevator access have been built on different anatomical and surgical principles than inter-sphincteric dissection techniques. Sphincter

Clinic of General Surgery,
Private Batı Bahat Hospital,
İstanbul, Turkey

Address for Correspondence Dr. Ali Naki Yücesoy

Clinic of General Surgery,
Private Batı Bahat Hospital,
İstanbul, Turkey
Phone: +90 532 613 99 93
e-mail:
alinakiyucesoy@gmail.com

Received: 06.12.2013
Accepted: 24.11.2013

©Copyright 2014
by Turkish Surgical Association
Available online at
www.ulusalcerahidergisi.org

preserving extra-sphincteric dissection and proximal segmental anal sphincter excision are primary surgical techniques for trans-sphincteric rectal resection via sublevator access.

MATERIAL AND METHODS

Seven patients (4 female, 3 male) with lower rectal cancer were operated by sublevator access. Patients who underwent surgery, have been offered Miles operation for lower rectal cancer. Detailed written informed consent was obtained from all patients including possible complications during or after surgery and functional problems. Our application for the Institutional Review Board was not processed due to our center's not qualifying as an institution.

The surgery was carried out in two stages as supralelevator and sublevator. In the supralelevator stage, the rectosigmoid was mobilized down to the level of puborectal muscles through the abdomen and total mesorectal excision was performed. Although, we have preferred open surgery, laparoscopic surgery can be used in this stage. After completion of the supralelevator stage, it was moved to the sublevator stage. The access to the sublevator level was provided with either transvaginal or transperineal procedures (Figure 1a, b).

Once the sublevator rectum was accessed, the sublevator lower rectal segment that was completely surrounded by the external sphincter complex was visualized. At the sublevator level, the external sphincter muscle structure surrounding the rectum was found to be significantly thicker in male patients as compared to females. At this level, rectal dissection was carried out in the extra-sphincteric plane, outside the external sphincteric system that surrounds the rectum.

The lower rectum was separated from the surrounding tissues through the extra-sphincteric plane, the dissection was carried on proximally until the puborectal muscle level has been reached. At this level, the fibrous connective tissue between the puborectal muscle and the proximal portion of the deep external anal sphincter muscles should be mobilized by dissection, the supralelevator and sublevator compartments should be combined, and total rectal mobilization should be provided. In women, the fibrous attachment between the puborectal muscle and the proximal portion of the deep external anal sphincter muscles were looser than in men, and the mobilization at the level of the puborectal muscle was found to be

much more easily performed in female patients than in males.

When rectal resection is performed at the sublevator level, the external sphincteric muscle complex and the two cylindrical intertwined muscular structure formed at the sublevator portion of the lower rectum can be viewed (Figure 2a, b). The external sphincter complex creates the outer cylindrical structure, and the lower rectum forms the inner cylindrical structure. The intersphincteric plane creates the potential gap between the two cylindrical muscular structures, where the inter-sphincteric dissection is performed. Therefore, either transvaginal or transperineal, in all the lower rectal resections done at the sublevator level, first the outermost external sphincter muscle is transected. In other words, all sublevator rectal resections are performed in the transsphincteric plane.

Following distal trans-sphincteric resection that was performed at the sublevator level, the proximal sphincteric segment that surrounds the rectum segment between the puborectal muscle and the distal resection line, was transected along with the rectal segment it surrounds. In this way, segmental proximal sphincter excision was completed. The distal segment of the external anal sphincter complex and internal anal sphincter or according to the level the distal segment of the internal anal sphincter were therefore preserved. In the distal anal segment, in order to prevent retraction of the external sphincter, the sphincteric muscle was sutured to the distal intestinal segment (Figure 3a, b). After rectosigmoid resection, a coloanal anastomosis between the colon and the distal anal segment was completed via the sublevator route (Figure 4a, b). In patients with protective ileostomy, the ileostomy was taken down after completion of anastomotic healing. Patients were oncologically followed up in their postoperative period.

Statistical Analysis

NCSS 2007 & PASS 2008 Statistical Software program was used for analysis. Descriptive statistical methods were used as well as Mann-Whitney U test for comparison of quantitative data. The relationships between parameters were analyzed with Spearman's correlation.

RESULTS

Seven patients with low rectal cancer (3 male and 4 female-mean age 66 years) were operated between 2007 and 2013 by the sublevator approach (Table 1). In the preoperative pe-

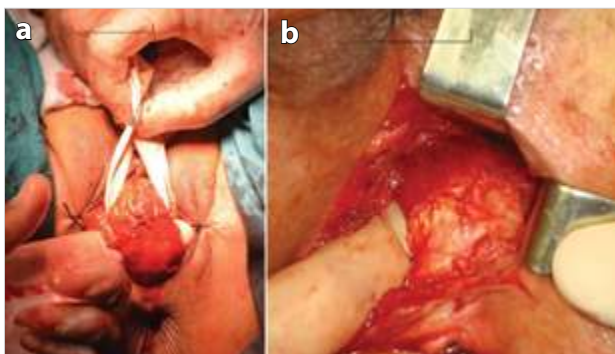


Figure 1a. Transvaginal extra-sphincteric rectal dissection in a female with lower rectal cancer. b) Transperineal extra-sphincteric rectal dissection in a male with lower rectal cancer

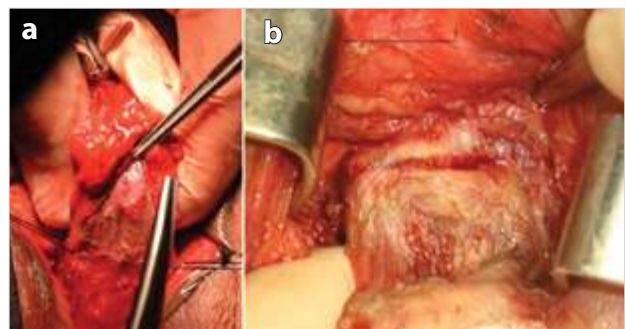


Figure 2a. Trans-sphincteric rectal resection at the sublevator level in a female with lower rectal cancer. b) Trans-sphincteric rectal resection at the sublevator level in a male with lower rectal cancer

riod, local invasion was evaluated by pelvic MRI and distant metastasis by tomography. None of the patients received preoperative chemoradiotherapy. Preoperative chemoradiotherapy was not preferred since local invasion was detected as low stage by pelvic MRI and the surgeries being carried out on the basis of extra-sphincteric dissection. Anal canal-tumor

distance varied from 2.5 to 5 cm, with a mean of 4.07 ± 1.02 cm and the median of 4 cm. The number of lymph nodes removed by total mesorectal excision ranged from 14 to 30, the mean was 21.14 ± 5.52 and the median 22. The mean Kelly continence score was 3.71 ± 1.8 and the median was 4. 57.1% of patients received protective ileostomy, and the proportion of cases without protective ileostomy was 42.9%. In 14.3% of patients, the distal resection line harbored tumor cells, while in 85.7% resection margin was negative. Circumferential margin positivity, tumor perforation, local recurrence and distant metastases were not detected in any patient.

At the supralelevator stage of surgery, mobilization of the recto-sigmoid and total mesorectal excision was performed by open abdominal approach. The sublevator access was achieved by transvaginal route in women and perineal route in males. In all patients, sphincter preserving extra-sphincteric dissection technique and proximal segmental sphincteric excision was performed at various levels. Protective ileostomy was performed in four patients. Protective ileostomy was applied in cases where the surgeon had concerns about the safety of coloanal anastomosis. Intestinal continuity was achieved in all patients. Perioperative abdominoperineal rectum amputation was not required in any patients. Patients were followed postoperatively between 6 to 78 months. The mean follow-up period was 25 months.

In one patient, an intestinal perforation in the colonic segment proximal to the coloanal anastomosis was observed, which we think was secondary to venous thrombosis induced ischemic necrosis. The patient was re-operated. After resection of the necrotic colon segment, an end colostomy was performed. The patient was lost due to septic complications in the early postoperative period. One patient died from cardiac causes on the 13th postoperative month without any local recurrence or distant metastasis. An anastomotic leak occurred in one patient with protective ileostomy. After a prolonged recovery period, the protective ileostomy was taken down. In the patient with anastomotic leakage and another patient, anastomotic stricture that narrowed the lumen by 50% developed. The

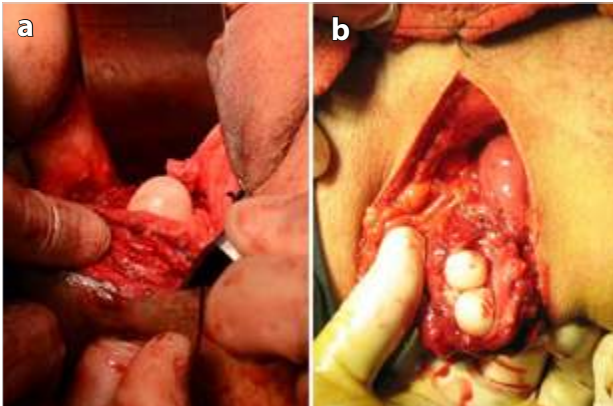


Figure 3a. Distal anal segment after resection in a female with lower rectal cancer. b) Distal anal segment after resection in a male with lower rectal cancer

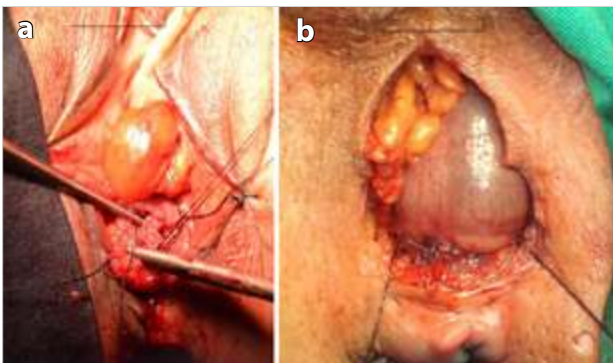


Figure 4a. Transvaginal colo-anal anastomosis after resection in a female with lower rectal cancer. b) Transperineal colo-anal anastomosis after resection in a male with lower rectal cancer

Table 1. Clinical and oncological results of patients with sublevator rectal resection

	Age gender	Follow-up	Anal canal tumor distance	Pathologic stage	Protective ileostomy	Tumor in the circumferential margin	Tumor in the distal resection margin	Tumor perforation	Kelly continence score	Mortality and morbidity	Local recurrence distant metastasis
H ₁	65, F	78 month	5 cm	T ₃ , N ₀ (0/14), M ₀	(-)	(-)	(-)	(-)	5	-	(-)
H ₂	53, M	41 month	3 cm	T ₂ , N ₀ (0/24), M ₀	(-)	(-)	(-)	(-)	3	Anastomotic stricture	(-)
H ₃	66, M	(-)	5 cm	T ₃ , N ₀ (0/24), M ₀	(+)	(-)	(-)	(-)	(-)	Postop ex	(-)
H ₄	78, F	13 month	4 cm	T ₂ , N ₀ (0/16), M ₀	(+)	(-)	(-)	(-)	5	-	(-)
H ₅	69, M	22 month	4 cm	T ₃ , N ₀ (0/22), M ₀	(+)	(-)	(-)	(-)	4	Anastomotic leak, anastomotic stricture	(-)
H ₆	62, F	15 month	5 cm	T ₃ , N ₁ (3/18), M ₀	(-)	(-)	(-)	(-)	4	-	(-)
H ₇	69, F	6 month	2.5 cm	T ₃ , N ₀ (0/30), M ₀	(+)	(-)	(+)	(-)	5	-	(-)

anastomotic strictures were treated with repeated anal dilatation. Urinary retention or incontinence was not observed. Rectovaginal fistula was not observed in any of the 4 female patients in whom the transvaginal access was used for sublevator access. Only half of these patients had a protective ileostomy.

The oncologic reliability of the surgical technique were evaluated by using criteria such as tumor perforation, circumferential resection margin positivity, presence of tumor in the distal resection margin, the number of removed lymph nodes, local recurrence and distant metastasis development. Circumferential resection margin was negative in all our patients and tumor perforation was not detected. Only one patient, tumor deposits were observed on the distal resection line. Local recurrence or distant metastasis was not observed in any patients during follow-up. The number of lymph nodes removed can be accepted as an indicator of effective total mesorectal excision. In this series, the mean number of lymph nodes removed by total mesorectal excision was identified as 22.

In the postoperative period, the anal sphincter continence was followed by using the Kelly continence scores. The mean Kelly continence score in this series was 4.3. The patient with a postoperative Kelly continence score of 3, already had continence problems due to multiple sclerosis in the preoperative period. Although segmental proximal anal sphincter excision was performed at various levels in all our patients, the distal anal segment provided sufficient continence.

DISCUSSION

Transvaginal rectal access has been used for nearly a century in surgical procedures of the rectum. Charles Ball mentions rectal polyp excision by the transvaginal route in his book 'The rectum: It's a disease and developmental defects' (9). Castro first described rectal resection and anastomosis through the vaginal access in rectal cancer (10).

The transvaginal low anterior resection for low rectal cancer was previously presented as a case report (11). Similarly, we published anatomical description of the main surgical techniques in a male patient with lower rectal cancer, in whom we performed low anterior resection using the perineal access (12). In the same period, rectal resection techniques performed at the sublevator level by vaginal and perineal approaches have been published in rectal cancer treatment (13, 14). However, the surgical technique or the anatomical basis have not been described in any of these articles. Rectal resections performed with transvaginal and transperineal routes are based on the same anatomical principles and surgical techniques, with the main goal of providing access to the sublevator level.

Rectal cancer spreads circumferentially in the bowel wall. In lower rectum cancer, circumferential resection margin (CRM) positivity is the leading factor in predicting locoregional tumor recurrence. In other words, a positive circumferential resection margin indirectly indicates presence of tumor cells in perirectal residual tissues after resection. As local stage (T) increases in lower rectum tumor, circumferential resection margin positivity increases. In lower rectal cancers operated

with intersphincteric dissection technique, there is a close correlation between locoregional recurrence and circumferential resection margin positivity (5, 15).

In lower rectum cancer patients who were operated by cylindrical abdominoperineal amputation method, a significant decrease was observed in circumferential resection margin positivity and locoregional recurrence rates (16-18). The cylindrical abdominoperineal amputation technique is based on extra-sphincteric dissection. The rectum is amputated following dissection from the surrounding tissues in the extra-sphincteric plane. In rectal resections performed by the sublevator approach, sphincter preserving extra-sphincteric dissection is applied. Therefore, in rectal resections performed in the sublevator level due to lower rectal cancer, both sphincter preserving rectal resections can be accomplished at very low levels and a significant reduction in locoregional recurrence rate can be achieved. The sublevator region does not include mesorectal tissues or lymph nodes, therefore total mesorectal excision is a surgical procedure that belongs to the abdominal part of the operation.

Oncologic and pathologic results of patients who underwent sphincter preserving extra-sphincteric dissection for lower rectal cancer are similar to the results of patients with cylindrical abdominoperineal rectal amputation (16-18). Following resection, circumferential margin positivity and tumor perforation are the primary factors that influence the development of locoregional recurrence (19).

In patients who were operated by inter-sphincteric dissection technique, the mean circumferential margin positivity rate was 30% and tumor perforation was detected in 16% (5), however circumferential margin positivity and tumor perforation was not found in any patients in our series. The total number of lymph nodes determined by pathological examination is an indicator of the effectiveness of the total mesorectal excision procedure. In order to mention an effective total mesorectal excision, at least 12 lymph nodes should be removed. Locoregional recurrence or distant metastasis was not detected during follow-up. Despite all these positive follow-up criteria, a higher number of cases are required to be able to conclude on the effectiveness of this surgical technique.

Study limitations

The most important limitation of this study was the low number of patients who underwent this type of surgery, since our hospital is not a referral center. Although patient number was insufficient, the long period to obtain enough patients to reach significance a long follow-up period was obtained, providing an advantage.

CONCLUSION

Although there are no large series that have investigated the results of surgery performed with sublevator access, especially in lower rectum cancer surgery, this method should be considered as an alternative surgical method.

Ethics Committee Approval: Our Institutional Review Board application was not accepted because our hospital was not a research and education hospital.

Informed Consent: Written informed consent was obtained from all patients who participated in this study.

Peer-review: Externally peer-reviewed.

Conflict of Interest: No conflict of interest was declared by the author.

Financial Disclosure: The author declared that this study has received no financial support.

REFERENCES

1. Cancer. World Health Organisation. February 2006.
2. Piscatelli N, Hyman N, Osler T. Localizing colorectal cancer by colonoscopy. *Arch Surg* 2005; 140: 932-935. [\[CrossRef\]](#)
3. Goligher JC. *Surgery of the anus, rectum and colon*. Bailliere Tindall, London. 1984.
4. Di Betta E, D'Hoore A, Filez L, Penninckx F. Sphincter saving rectum resection is the standard procedure for low rectal cancer. *Int J Colorectal Dis* 2003; 18: 463-469. [\[CrossRef\]](#)
5. Nagtegaal ID, van de Velde CJ, Marijnen CA, van Krieken JH, Quirke P; Dutch Colorectal Cancer Group; Pathology Review Committee. Low rectal cancer: a call for a change of approach in abdominoperineal resection. *J Clin Oncol* 2005; 23: 9257-9264. [\[CrossRef\]](#)
6. Moore KL, Dalley AF. *Clinically Oriented Anatomy*. 3rd ed. Lippincott Williams@Wilkins, 1992.
7. Ahmed S. A new concept of the anatomy of the anal sphincter mechanism and the physiology of defecation. *Dis Colon Rectum* 1980; 23: 37-43. [\[CrossRef\]](#)
8. Schiessel R, Karner-Hanusch J, Herbst F, Teleky B, Wunderlich M. Intersphincteric resection for low rectal tumours. *Br J Surg* 1994; 81: 1376-1378. [\[CrossRef\]](#)
9. Holm T, Ljung A, Haggmark T, Juvell G, Lagergren J. Extended abdominoperineal resection with gluteus maximus flap reconstruction of the pelvic floor for rectal cancer. *Br J Surg* 2007; 2: 232-238. [\[CrossRef\]](#)
10. Stelzner S, Hellmich G, Schubert C, Puffer E, Haroske G. Short-term outcome of extra-levator abdominoperineal excision for rectal cancer. *Int J Colorectal Dis* 2011; 26: 919-925. [\[CrossRef\]](#)
11. West NP, Finan PJ, Anderin C, Lindholm J, Holm T, Quirke P. Evidence of the oncologic superiority of cylindrical abdominoperineal excision for low rectal cancer. *J Clin Oncol* 2008; 26: 3517-3522. [\[CrossRef\]](#)
12. Adam IJ, Mohamdee MO, Martin IG, Scott N, Finan PJ, Johnston D, et al. Role of circumferential margin involvement in the local recurrence of rectal cancer. *Lancet* 1994; 10: 707-711. [\[CrossRef\]](#)
13. Ball C. *The Rectum: Its disease and developmental defects*. London: Oxford University Press 1908; 277-278.
14. Castro AF. Vaginal approach in resection of low-lying malignant rectal lesions. *Tex Med* 1973; 69: 65-69.
15. Yücesoy AN, Bülbül E, Bahat R. Transvaginal low anterior resection for rectal cancer. *Tech Coloproct* 2008; 12: 83-85. [\[CrossRef\]](#)
16. Yücesoy AN, Kadioğlu B. Abdomino-transsphincteric low anterior resection for distal rectal cancer in a male patient. *Tech Coloproct* 2012; 16: 179-181. [\[CrossRef\]](#)
17. Williams NS, Murphy J, Knowles CH. Anterior perineal plane for ultra-low anterior resection of the rectum (the APPEAR technique): a prospective clinical trial of a new procedure. *Ann Surg* 2008; 247: 750-758. [\[CrossRef\]](#)
18. Agrawal V, Mishra A, Raina VK, Sharma D. Abdominoanterior sagittal approach or sphincter-saving low anterior resection for carcinoma of the rectum in females: a modified approach. *Tech Coloproct* 2009; 13: 145-149. [\[CrossRef\]](#)
19. Wu ZY, Wan J, Zhao G, Peng L, Du JL, Yao Y, et al. Risk factors for local recurrence of middle and lower rectal carcinoma after curative resection. *World J Gastroenterol* 2008; 14: 4805-4809. [\[CrossRef\]](#)