



# Isolated cecal necrosis: our surgical experience and a review of the literature

## İzole çekum nekrozu: cerrahi deneyimlerimiz ve literatürün gözden geçirilmesi

Ekrem Çakar<sup>1</sup>, Feyzullah Ersöz<sup>1</sup>, Murat Bağ<sup>2</sup>, Savaş Bayrak<sup>1</sup>, Şükrü Çolak<sup>1</sup>, Hasan Bektaş<sup>1</sup>, M. Emin Güneş<sup>1</sup>, Emel Çakar<sup>3</sup>

### ABSTRACT

**Objective:** Isolated cecal necrosis is a rare cause of ischemic colitis. Ischemic colitis is further divided into two groups: occlusive mesenteric ischemia and non-occlusive mesenteric ischemia. The aim of this study was to investigate the cause of isolated cecal necrosis.

**Material and Methods:** We operated on 3 male and 3 female patients with a mean age of 60.3±18.7 (38-85) years with a preliminary diagnosis of acute appendicitis between 2007 and 2012. Four of these patients were on hemodialysis, 1 patient had an aortofemoral bypass, and 1 patient had coronary artery disease with atrial fibrillation.

**Results:** The diagnosis was made intraoperatively in all cases. Five patients died postoperatively. One patient survived.

**Conclusion:** In the case of right lower quadrant pain, the possibility of isolated cecal necrosis should be kept in mind, especially in patients on hemodialysis, elderly patients with diabetes, and heart disease; surgical strategies should be planned accordingly, and it should be understood that a high mortality rate will be inevitable.

**Key Words:** Isolated cecal necrosis, non-occlusive mesenteric ischemia, appendicitis

### ÖZET

**Amaç:** İzole çekum nekrozu iskemik kolitin nadir görülen bir nedenidir. İskemik kolit ise oklüziv ve non-oklüziv mezenterik iskemik olmak üzere ikiye ayrılır. Bu çalışmanın amacı izole çekum nekrozunun nedenlerini araştırmaktır.

**Gereç ve Yöntemler:** 2007-2012 tarihleri arasında yaş ortalamaları 60,3±18,7 (38-85) yıl olan 3 erkek ve 3 kadın hasta akut apandisit ön tanısı ile ameliyat edildi. Bu hastaların 4'ü hemodiyaliz hastası, 1'i aortofemoral bypasslı, 1'i atriyal fibrilasyonlu koroner hastalığı olan hastalardı.

**Bulgular:** Tüm olgularda tanı intraoperatif olarak konuldu. Beş hasta postoperatif dönemde kaybedildi. Bir hasta yaşadı.

**Sonuç:** Özellikle hemodiyaliz, diyabet ve kalp hastalığı olan yaşlı hastalarda sağ alt kadranda ağrısı olması durumunda izole çekum nekrozu olasılığı akıldan tutulmalı, ameliyat stratejileri buna göre planlanmalı ve yüksek mortalitenin kaçınılmaz olacağı bilinmelidir.

**Anahtar Kelimeler:** İzole çekum nekrozu, non-oklüziv mezenter iskemisi, apandisit

<sup>1</sup>Clinic of General Surgery, İstanbul Training and Research Hospital, İstanbul, Turkey

<sup>2</sup>Clinic of General Surgery, Kocaeli State Hospital, Kocaeli, Turkey

<sup>3</sup>Department of Nursing, İstanbul Gelişim University, İstanbul, Turkey

### Address for Correspondence

#### Yazışma Adresi

Ekrem Çakar

Clinic of General Surgery, İstanbul Training and Research Hospital, İstanbul, Turkey

Phone: +90 505 578 40 57

e-mail:

ekremcakar@hotmail.com

Received / Geliş Tarihi: 10.01.2014

Accepted / Kabul Tarihi: 05.04.2014

©Copyright 2014

by Turkish Surgical Association

Available online at

www.ulusalcerrahidergisi.org

©Telif Hakkı 2014

Türk Cerrahi Derneği

Makale metnine

www.ulusalcerrahidergisi.org

web sayfasından ulaşılabilir.

### INTRODUCTION

Isolated cecal necrosis is a rare condition that occurs secondary to multiple causes. It develops especially when the anterior and posterior cecal arteries do not originate from a vascular arcade but from the colic branch of ileocolic artery. Vaso-occlusive infarcts have been reported to occur after atheroembolic or thromboembolic occlusions of the cecal arteries in this anatomical variation (1, 2). On the other hand, non-occlusive cecal infarction has also been reported to be associated with shock, open-heart surgery, chronic heart disease, certain drugs, and hemodialysis (3-8).

Isolated cecal necrosis generally presents with right lower quadrant abdominal pain, and with these manifestations, it may mimic acute appendicitis. Due to high rates of morbidity and mortality, it must be considered in the differential diagnosis of pain in the right lower quadrant of the abdomen. The aim of this study is to remind that less common causes should be considered in the differential diagnosis of right lower quadrant pain and to examine 6 cases of isolated cecal necrosis seen at our clinic within a 5-year period in light of the literature.

### MATERIAL AND METHODS

Six cases of isolated cecal necrosis presented to the emergency department of İstanbul Training and Research Hospital General Surgery Clinic between 2007 and 2012 with acute abdominal pain mimicking physical examination findings of acute appendicitis were evaluated. Written informed consent was obtained from patients who participated in this study. Six patients were analyzed retrospectively. Data were obtained from hospital records. Data regarding their age, sex, diagnosis on admission, comorbid diseases, clinical and laboratory findings, and imaging techniques were reviewed according to the surgical procedures and postoperative follow-up performed (Table 1, 2). The cases consisted of 3 male and

3 female patients with a mean age of  $60.3 \pm 18.7$  (38-85) years at diagnosis. All patients had a preliminary diagnosis of acute appendicitis at diagnosis. The medical histories of these 6 patients revealed that 4 were chronic hemodialysis patients, 1

had an aortobifemoral graft due to a history of previous aortic aneurysm, and 1 patient had coronary artery disease with atrial fibrillation. All patients had a preoperative plain abdominal radiograph; air-fluid level was observed in only 1 patient, and others were normal. Three patients received an abdominal computed tomography (CT) scan; air-fluid level was present in only 1 patient, and the other CT results were normal.

Table 1. Clinical and laboratory findings of the patients with isolated cecal necrosis

Findings	Number of cases
Abdominal pain	6
Defense in the right lower quadrant of the abdomen	6
Vomiting	2
Arterial hypotension episodes during hemodialysis	4
Fever $>37.5^{\circ}\text{C}$	2
Shock (Max. blood pressure $<80$ mm-Hg)	2
Leukocytosis	4

## RESULTS

In one patient, a diagnosis of cecal necrosis was made by diagnostic laparoscopy. At the laparotomy, isolated cecal necrosis and a normal appendix were observed (Figure 1a, b). A second examination was performed in all patients except 1; 1 patient died at postoperative 40. hour due to cardiopulmonary arrest after a sudden hypotensive episode. At the first surgery, as the first procedure, right hemicolectomy + ileotransversostomy was performed on 2 patients, right hemicolectomy + end ileostomy + mucous fistula was performed on 2 patients, cecal resection + end-to-side ileocolostomy was performed on 1 patient, and cecal resection + end ileostomy + mucous fistula

Table 2. Patient characteristics and surgical procedures

Patient	1	2	3	4	5	6
Age	63	85	60	39	38	77
Gender	M	F	F	F	F	M
Comorbid disease	- Aortobifemoral bypass patient - HT - Generalized atherosclerosis - Atrial fibrillation	- Congestive heart failure - HT - DM - Atrial fibrillation - Generalized atherosclerosis - Coronary artery disease	- CRF - DM - HT - Coronary artery disease	- CRF - DM	CRF DM	CRF HT Congestive heart failure
1 <sup>st</sup> Procedure	Right hemicolectomy end ileostomy + mucous fistula	Right hemicolectomy ileotransversostomy	Right hemicolectomy end ileostomy + mucous fistula	Right hemicolectomy ileotransversostomy	Cecal resection end-to-side ileocolostomy	Cecal resection end ileostomy mucous fistula
2 <sup>nd</sup> Examination	36 hours later Normal	24 hours later anastomosis and ischemia around the anastomosis		36 hours later ischemia on the anastomosis line	24 hours later ischemia on the anastomosis line	36 hours later Normal
2 <sup>nd</sup> Procedure	On Day 5, necrotizing fasciitis at incision site, debridement + VAC performed	End ileostomy + mucous fistula	End ileostomy + mucous fistula	Right hemicolectomy + end ileostomy + mucous fistula		
3 <sup>rd</sup> Examination		48 hours later ischemia-ileostomy revision on ileostomy end	24 hours later Normal	24 hours later Normal		
Outcome	Died on postoperative day 37	Died on postoperative day 23	Cardiopulmonary arrest on postoperative day 2	Died on postoperative day 43	Died on postoperative day 12	Discharged full recovery on postoperative day 9

HT: hypertension; DM: diabetes mellitus; CRF: chronic renal failure; VAC: vacuum assisted closure

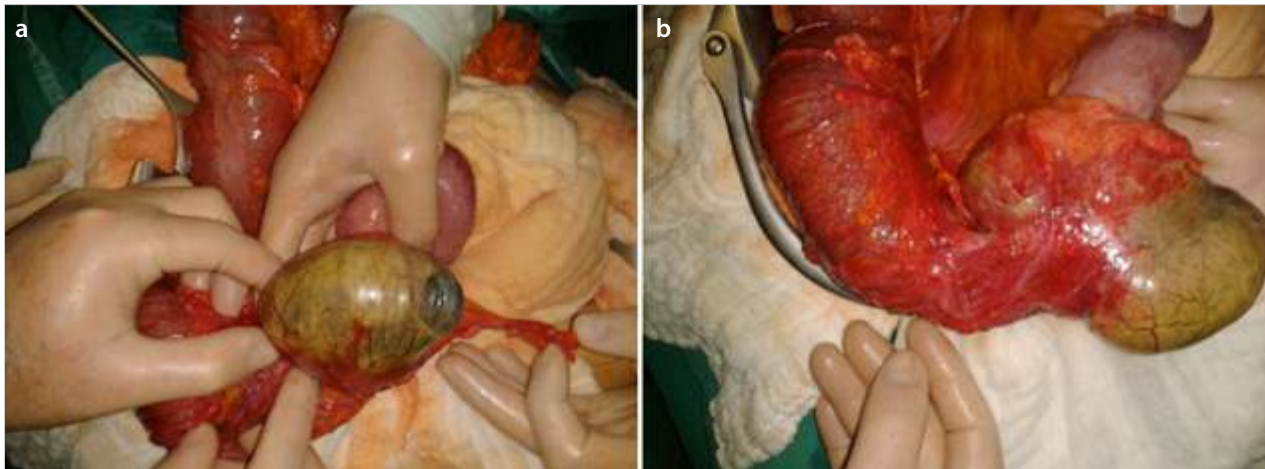


Figure 1. a, b. Isolated cecal necrosis

was performed on 1 patient. Five of our patients died at various postoperative times due to the aggressive and destructive effects of the disease; 1 patient was discharged on postoperative day 9, and there were no complications during the follow-up period. Histopathological examinations revealed isolated transmural ischemic necrosis of the cecum and hyperemia in the submucosa and subserosa-evidence of peritonitis serosa. None of the patients showed mesenteric vascular occlusion.

## DISCUSSION

Mesenteric ischemia occurs due to occlusive or non-occlusive factors, and while the occlusive type is associated with arterial embolism or venous thrombosis, the leading cause of non-occlusive mesenteric ischemia (NOMI) is mesenteric vasoconstriction (9, 10). The main setting in ischemic colitis, a well-recognized variant of NOMI, is decreased colonic blood flow, and it is divided into two types (5). In type 1, the symptoms of the disease develop spontaneously; the precipitating factors responsible for the decreased mesenteric blood flow are not identifiable. In type 2, symptoms occur secondarily, most often after episodes of hypotension or decreased cardiac output or after aortic surgery. Cecal necrosis secondary to hypotension have also been reported in dialysis or trauma patients (5, 11).

In 25% to 60% of patients with intestinal infarction, NOMI is the cause (12, 13). With mortality rates of 71% to 100%, NOMI is also the most lethal form of mesenteric ischemia. These high mortality rates are attributable to a frequent delay in diagnosis (13, 14). Smoking history, diabetes mellitus, advanced age, hypertension, dyslipidemia, and presence of arterial occlusive disease are risk factors for NOMI (15, 16).

Our 63-year-old male patient had a history of aortobifemoral bypass due to an aortic aneurysm 3 years ago. He also had hypertension and atrial fibrillation. Another case was an 85-year-old female patient. She had heart failure, coronary artery disease, atrial fibrillation, hypertension, and diabetes mellitus. Both patients had severe risk factors for NOMI.

Hemodialysis patients are a group of patients predisposed to developing NOMI (13-16). Although an intact pituitary and renal system is required for adequate mesenteric vasoconstrictive response, 9% to 20% of deaths in hemodialysis-dependent patients are attributable to NOMI or bowel infarction

(16, 17). Clark and Gewertz (18) showed that histologic injury caused by two short 15-minute periods of low-flow reperfusion was more severe than a 30-minute period of reperfusion. Decreased volume accompanied by increased hematocrit may contribute to the low-flow state (19). Four of our cases were patients with CRF. A retrospective review of their medical histories revealed that they had previous episodes of arterial hypotension during hemodialysis.

Clinical and laboratory findings of cecal necrosis, such as pain, fever, and leucocytosis, are usually non-specific, and therefore, early diagnosis is very difficult (20, 21). For this reason, at the early stage, diagnostic laparotomy is preferable in the majority of patients, and a definitive diagnosis is made intraoperatively (22). The use of colonoscopy is also controversial in such patients, but colonoscopy has been reported to increase transmural pressure, leading to decreased colonic perfusion and increased risk of perforation (23). Therefore, we did not perform colonoscopy in any of our patients (24). Appropriate incision type can be selected on the basis of the results of the diagnostic laparoscopy. In one of our patients with chronic renal failure, we performed diagnostic laparoscopy and chose a midline incision. In one patient with ileus, a midline incision was chosen; in another patient, we started with McBurney's incision and converted to a midline incision; and in three patients, we chose a right paramedian incision. A second examination was performed in all patients except one. Second examinations were performed 24-36 hours after the operation. One patient, in whom a second examination could not be performed, died at postoperative 40. hour due to cardiac causes. A third examination was performed in all patients who underwent a second examination, and for the examination, only the skin was closed in the first operation.

Resection of a necrotic bowel segment is the main objective of the surgical treatment. In treatment, partial cecal resection or right hemicolectomy are the methods chosen according to the size of necrosis in the cecum and evidence of peritonitis (21, 22). The surgical procedures performed in our series are shown in Table 2.

Ischemia on the anastomosis line was observed in the second examination of all patients who underwent anastomosis, whereupon the resection was converted to an end ileostomy

and mucous fistula procedure. The third examination performed in these patients revealed necrosis in the ileostomy end in one patient, and revision of ileostomy was performed. Other bowel loops seemed to be natural in the third examinations.

Unfortunately, we lost 5 of 6 patients in our series. The mortality rate was as high as 83%. One of 5 patients died from cardiac causes in the early period, and the other 4 patients died in the late period due to multiple organ failure due to sepsis. According to Boley et al. (25), 50% of patients diagnosed within the first 24 hours after the onset of symptoms survive; however, in cases of diagnosis later than 24 hours, less than 30% of patients survive. In their series of 5 cases, Schuler et al. (26) preferred right hemicolectomy in all patients. They performed anastomosis in 4 patients and ostomy in 1 patient who developed perforation due to necrosis. All of the 4 patients who underwent anastomosis survived, while the patient who underwent ostomy surgery died due to postoperative sepsis. In this series, the symptoms had started 24 hours before the operation in 3 patients, 48 hours before the operation in 1 patient, and 3 days before the operation in 1 patient who died. The histological examination of the cases revealed transmural ischemic necrosis only in the patient who died. In all of our cases, the symptoms had started more than 24 hours before the operation (minimum 48 hours, maximum 7 days). All of our patients had transmural ischemic necrosis. In their series of 36 cases, Sakai et al. (27) lost 21 patients and found a mortality rate as high as 58%. The mortality rate was 71% in patients with transmural necrosis; 88% of the patients who had mucosal necrosis alone survived. The degree of necrosis determines the most important role in the prognosis (28).

Based on the literature review, as well as in our series, delayed diagnosis appears to be the most important factor affecting mortality. Little is known about postoperative ischemic necrosis of the remaining intestinal segments after surgical treatment of isolated cecal necrosis. If we need to make a self-criticism through this article, we think that we should have chosen ostomy rather than anastomosis for surgical treatment of these patients who presented to the clinic late, who were diagnosed late, and whose general conditions were impaired.

The limitations of our study were its retrospective nature and inclusion of uncommon cases due to the small number of cases.

## CONCLUSION

We believe that isolated cecal necrosis should be considered in the clinical presentation of right lower quadrant abdominal pain in hemodialysis patients, elderly patients, and patients with comorbid diseases; in case of necrosis, anastomosis should be avoided after resection, and an ostomy procedure should be preferred. We also believe that a second examination would be important for early recognition of new areas of ischemic necrosis.

**Ethics Committee Approval:** This is a retrospective study. There is no application to the ethics committee.

**Informed Consent:** Written informed consent was obtained from patients who participated in this study.

**Peer-review:** Externally peer-reviewed.

**Author Contributions:** Concept - E.Ç., F.E.; Design - E.Ç., F.E., M.B.; Supervision - F.E., S.B., H.B.; Funding - Ş.Ç., Em.Ç., M.E.G.; Materials - E.Ç., F.E.; Data Collection and/or Processing - S.B., Ş.Ç., Em.Ç.; Analysis and/or Interpretation - E.Ç., F.E., H.B.; Literature Review - M.B., M.E.G., Em.Ç.; Writer - E.Ç., F.E.; Critical Review - M.B., S.B., H.B.; Other - M.E.G., Ş.Ç.

**Acknowledgements:** We would like to thank Assoc. Prof. Dr. Serkan Sarı for his contributions to this manuscript.

**Conflict of Interest:** No conflict of interest was declared by the authors.

**Financial Disclosure:** The authors declared that this study has received no financial support.

**Etik Komite Onayı:** Retrospektif bir çalışmadır. Etik kurul başvurusu yoktur.

**Hasta Onamı:** Yazılı hasta onamı bu çalışmaya katılan hastalardan alınmıştır.

**Hakem değerlendirmesi:** Dış bağımsız.

**Yazar Katkıları:** Fikir - E.Ç., F.E.; Tasarım - E.Ç., F.E., M.B.; Denetleme - F.E., S.B., H.B.; Kaynaklar - Ş.Ç., Em.Ç., M.E.G.; Malzemeler - E.Ç., F.E.; Veri toplanması ve/veya işlemesi - S.B., Ş.Ç., Em.Ç.; Analiz ve/veya yorum - E.Ç., F.E., H.B.; Literatür taraması - M.B., M.E.G., Em.Ç.; Yazıyı yazan - E.Ç., F.E.; Eleştirel inceleme - M.B., S.B., H.B.; Diğer - M.E.G., Ş.Ç.

**Teşekkür:** Doç. Dr. Serkan Sarı'ya yazının hazırlanmasından dolayı verdiği destek için teşekkür ederiz.

**Çıkar Çatışması:** Yazarlar çıkar çatışması bildirmemişlerdir.

**Finansal Destek:** Yazarlar bu çalışma için finansal destek almadıklarını beyan etmişlerdir.

## REFERENCES

1. Chan T, Levine MS, Park Y. Cholesterol embolization as a cause of cecal infarct mimicking carcinoma. *AJR Am J Roentgenol* 1998; 150: 1315-1316. [\[CrossRef\]](#)
2. Simon AM, Birnbaum BA, Jacobs JE. Isolated infarction of the cecum: CT findings in two patients. *Radiology* 2000; 214: 513-516. [\[CrossRef\]](#)
3. Flynn TC, Rowlands BJ, Gilliland M, Ward RE, Fischer RP. Hypotension induced posttraumatic necrosis of the right colon. *Am J Surg* 1983; 146: 715-718. [\[CrossRef\]](#)
4. Hargrove WC, Rosato EF, Hicks RE, Mullen JL. Cecal necrosis after open-heart operation. *Ann Thorac Surg* 1978; 25: 71-73. [\[Cross-Ref\]](#)
5. Schuler JG, Hudlin MM. Cecal necrosis: infrequent variant of ischemic colitis. Report of five cases. *Dis Colon Rectum* 2000; 43: 708-712. [\[CrossRef\]](#)
6. Rist CB, Watts JC, Lucas RJ. Isolated ischemic necrosis of the cecum in patients with chronic heart disease. *Dis Colon Rectum* 1984; 27: 548-551. [\[CrossRef\]](#)
7. Sloane CE, Anderson AA. Cecal infarction; ergot abuse as a possible etiologic factor. *Mt Sinai J Med* 1980; 47: 31-33.
8. Flobert C, Cellier C, Berger A, Ngo A, Cuillerier E, Landi B, et al. Right colonic involvement is associated with severe forms of ischemic colitis and occurs frequently in patients with chronic renal failure requiring hemodialysis. *Am J Gastroenterol* 2000; 95: 195-198. [\[CrossRef\]](#)
9. Miller L, Barbaravech C, Friedman L. Less frequent causes of lower gastrointestinal bleeding. *Gastroenterol Clin North Am* 1994; 23: 21-52.

10. Wilcox MG, Howard TJ, Plaskon LA, Unthank JL, Madura JA. Current theories of pathogenesis and treatment of nonocclusive mesenteric ischemia. *Dig Dis Sci* 1995; 40: 709-16. [\[CrossRef\]](#)
11. Rodriguez-Sanjuan JC, Naranjo A. Letter to the editor: cecal ischemia mimicking carcinoma. *Dis Colon Rectum* 1997; 40: 867-868. [\[CrossRef\]](#)
12. Berk J. Nonocclusive mesenteric vascular insufficiency. *Arch Surg* 1976; 111: 829-830. [\[CrossRef\]](#)
13. Bassiouny HS. NOMI. *Surg Clin North Am* 1997; 77: 319-326. [\[CrossRef\]](#)
14. Valentine R, Whelan T, Meyers H. Nonocclusive mesenteric ischemia in renal patients (recognition and prevention of intestinal gangrene). *Am J Kidney Dis* 1990; 15: 598-600. [\[CrossRef\]](#)
15. Zeier M, Weisel M, Ritz E. Nonocclusive mesenteric infarction in dialysis patients-risk factors, diagnosis, intervention and outcome. *Int J Artif Organs* 1992; 15: 387-389.
16. Zeier M, Wiesel M, Rambusek M, Ritz E. Nonocclusive mesenteric infarction in dialysis patients (the importance of prevention and early intervention). *Nephrol Dial Transplant* 1995; 10: 771-773.
17. USRDS 1997 Annual Report. VI. Causes of death. *Am J Kidney Dis* 1997; 30: 107-117. [\[CrossRef\]](#)
18. Clark ET, Gewertz BL. Intermittent ischemia potentiates intestinal reperfusion injury. *J Vasc Surg* 1991; 13: 606-610. [\[CrossRef\]](#)
19. Bender J, Ratner L, Magnuson T, Zenilman M. Acute abdomen in the hemodialysis patient population. *Surgery* 1995; 117: 494-497. [\[CrossRef\]](#)
20. Han SY, Kwon YJ, Shin JH, Pyo HJ, Kim AR. Nonocclusive mesenteric ischemia in a patient on maintenance hemodialysis. *Korean J Intern Med* 2000; 15: 81-84.
21. John AS, Tuerff SD, Kerstein MD. Nonocclusive mesenteric infarction in hemodialysis patients. *J Am Coll Surg* 2000; 190: 84-88. [\[CrossRef\]](#)
22. Charra B, Cuche J, Ruffet M, Terrat JC, Beurlet J, Labrosse H, et al. Segmental necrosis of ascending colon in haemodialysis patients. *Nephrol Dial Transplant* 1995; 10: 2281-2285.
23. Bradbury AW, Brittenden J, McBride K, Ruckley CV. Mesenteric ischaemia: a multidisciplinary approach. *Br J Surg* 1995; 82: 1446-1459. [\[CrossRef\]](#)
24. Perko Z, Bilan K, Vilovic K, Druzijanic N, Kraljevic D, Juriicic J, et al. Partial cecal necrosis treated by laparoscopic partial cecal resection. *Coll Antropol* 2006; 30: 937-939.
25. Boley SJ, Feinstein FR, Sammartano R, Brandt LJ, Sprayregen S. New concepts in the management of emboli of the superior mesenteric artery. *Surg Gynecol Obst* 1981; 153: 561-569.
26. Schuler JG, Margaret M, Hudlin MM. Cecal necrosis: Infrequent variant of ischemic colitis. *Dis Colon Rectum* 2000; 43: 708-712. [\[CrossRef\]](#)
27. Sakai L, Keltner R, Kaminski D. Spontaneous and shock-associated ischemic colitis. *Am J Surg* 1980; 140: 755-760. [\[CrossRef\]](#)
28. Haglund U. Gut ischemia. *Gut* 1994; 35 (suppl 1): 573-576. [\[CrossRef\]](#)