



A comparison of single-port laparoscopic cholecystectomy and an alternative technique without a suspension suture

Barlas Sülü, Tülay Diken, Hasan Altun, Turgut Anuk, Bülent Güvendi, Elif İlingi, Musa Sinan Eren, Yusuf Günerhan, Neşet Köksal

ABSTRACT

Objective: Many surgeons face difficulties during single-incision laparoscopic cholecystectomy (SILC) surgery and are forced to use an additional port. We compared the results of a technique that we developed with SILC.

Material and Methods: Fifty-four patients who were diagnosed with chronic cholelithiasis were prospectively randomized and divided into two groups. An additional 5-mm port (MCAP: with an additional port using a multi-channel device through the umbilicus) was placed in the subxiphoid area instead of a transabdominal suspension suture in one group of patients. The other group was operated on with the SILC technique. The demographic and surgical data of the patients were compared.

Results: The MCAP technique shortened the surgery duration by more than half (MCAP: 35.0 ± 12.3 , SILC: 79.1 ± 27.7 min) ($p < 0.05$). No difference was found between the two methods in terms of estimated blood loss, length of hospitalization, postoperative day 1 and 7 visual analog scale scores, need for analgesia in the postoperative period, and rate of changing to another technique due to inadequacy of the surgical technique.

Conclusion: MCAP is as safe as SILC for cholecystectomy and is easier for the surgeon to perform.

Key Words: Cholecystectomy, laparoscopic surgery, minimally invasive, cholelithiasis

INTRODUCTION

Single-incision laparoscopic surgery (SILS) was first used two decades ago. This method was then used in gynecology, urology, and also general surgery, with an emphasis on cholecystectomy (1, 2). According to the short-term results, this new method was less painful, led to fewer hernias, provided better cosmesis, and was more economical (2).

However, some disadvantages of this method were reported in recent studies (3). Baik et al. (4) reported that the complex instruments and ports used in this method caused significant difficulties and restrictions during surgery. Ma et al. (5) had to use additional ports for the vast majority of patients (67%) during single-incision laparoscopic cholecystectomy (SILC) due to technical difficulties during surgery. Additional ports were also used in rectal surgery due to technical difficulties (6).

Despite their use in numerous clinical studies, we did not come across data on the use of additional ports in the articles we could access.

We found that the surgery became easy and that suspension was not needed when a 5-mm port at the subxiphoid region was added to the SILC technique. We compared the preliminary results of this technique as planned and implemented by us for the first time with the results of patients for whom we used the SILC method.

MATERIAL AND METHODS

Study Design

The first 10 patients in whom we used SILC were evaluated in our pilot study. We found the mean duration of the surgery to be 65.5 ± 13.4 min. We aimed to reduce this duration by 10% in patients in whom we used an additional port. The number of patients needed was calculated. Considering a power of 80% and reliability of 0.05, we found that 22 patients should be present in each group. Two groups (Group 1; SILC, Group 2; MCAP) were randomized by automatic numbering from April 2012. The study was started with 54 patients for the possible loss of patients and data during the study. Some patients were excluded from the study due to the reasons presented in the flow-chart (Figure 1). The study was completed with 23 patients in each group.

Study Patients and Evaluated Data

This study was conducted in the Department of General Surgery, Kafkas University School of Medicine, between April 2012 and September 2013. All study patients were given information about the

Department of General Surgery,
Kafkas University Faculty of
Medicine, Kars, Turkey

Address for Correspondence

Barlas Sülü

Department of General Surgery,
Kafkas University Faculty of
Medicine, Kars, Turkey
Phone: +90 474 212 79 15
e-mail:
barlas.sulu36@gmail.com

Received: 16.03.2014

Accepted: 21.07.2014

©Copyright 2014
by Turkish Surgical Association

Available online at
www.ulusalcerahidergisi.org

content of the study and the surgical technique. Approval of the hospital ethical committee was obtained (Kafkas University-80576354-050-99/35), and the Helsinki Declaration principles were used. Informed patient consent forms that included their treatment protocols were taken from all patients included in this study.

Patients with an indication for elective cholecystectomy were included in this prospective randomized study. The demographic data of all patients in each group were analyzed. Of the patient-related data, the body mass index (BMI), American Society of Anesthesiologists (ASA) score, estimated blood loss (difference between the total amounts of suction and irrigation), duration of surgery and hospitalization, visual analog scale (VAS) scores on postoperative days 1 and 7 to measure the patient's pain, the need for analgesia and any complications, and the rate of changing to another technique due to inadequacy of the surgical technique were determined.

The operations were performed at the hospital by a surgical team that was experienced (with at least 100 laparoscopic surgeries) in the minimally invasive technique.

Pregnant women, patients with clotting disorders, those with a pre- or perioperative diagnosis of acute cholecystitis, and patients whose postoperative follow-up could not be performed were not included in the study.

Statistical Analysis

The Statistical Package for the Social Sciences (SPSS Inc., Chicago, IL, USA), v. 16.0 for Windows software package was used in the statistical analysis and data collection. The Shapiro-Wilk test was used for the distribution analysis of the parameters. The data with a normal distribution were expressed as mean \pm standard deviation, while data without a normal distribution were expressed with median values. The parameters with a normal distribution were compared with Student's t-test, and the parameters with an abnormal distribution were compared with the Mann-Whitney U test when comparing the two groups. P value <0.05 was accepted as significant.

Surgical Technique

We entered the abdomen with an approximately 1.5-cm transverse incision through the umbilicus in the supine position under general anesthesia for SILC. The flexible SILC port (Covidien, Massachusetts, USA) was pushed forward inside the abdomen from the incision with the help of a clamp. CO₂ was administered into the abdominal cavity through an insufflation cannula, and the abdomen was inflated to a pressure of 14 mm-Hg. A 5-mm cannula was inserted into the hole of the SILC port, and a 5-mm (30°) optical camera was pushed forward through the cannula into the abdominal cavity to explore the abdomen. Two 5-mm cannulae were inserted into the abdominal cavity through the other two holes. A 4/0 polypropylene fiber with a straight needle was used to enter the abdomen from the right upper quadrant under the costal curve and then passed through the fundus of the gallbladder and exited through the skin in an area adjacent to the entry site. Tension was applied to the suture, and the gallbladder was hung on the abdominal wall. Calot's triangle was dissected with standard laparoscopic instruments, and the cystic duct and cystic artery were revealed. The cystic duct and cystic artery were clipped with a 5-mm clip. Following the completion of the gallbladder dissection, the suspension suture was cut, and the gallbladder was taken out of the abdomen together with the port.

No suspension sutures were placed in the MCAP to hang the gallbladder, unlike in the SILC method. After the SILC port was inserted through the incision in the umbilicus, a 5-mm trocar was placed through the 0.5-cm incision made in the right of the upper one-third junction of the umbilicus-xiphoid distance under the xiphoid process (Figure 2a). Laparoscopic instruments, such as a grasper, clip shooter, dissector, and irrigation instrument, were placed from this incision as required during the surgery (Figure 2b). The gallbladder was suspended upwards and backwards with a grasper placed through the umbilical port. A second grasper was entered through this port, and the retraction procedure was performed with two graspers when needed during the process. Cholecystectomy was performed in the patient as in the SILC method. The pa-

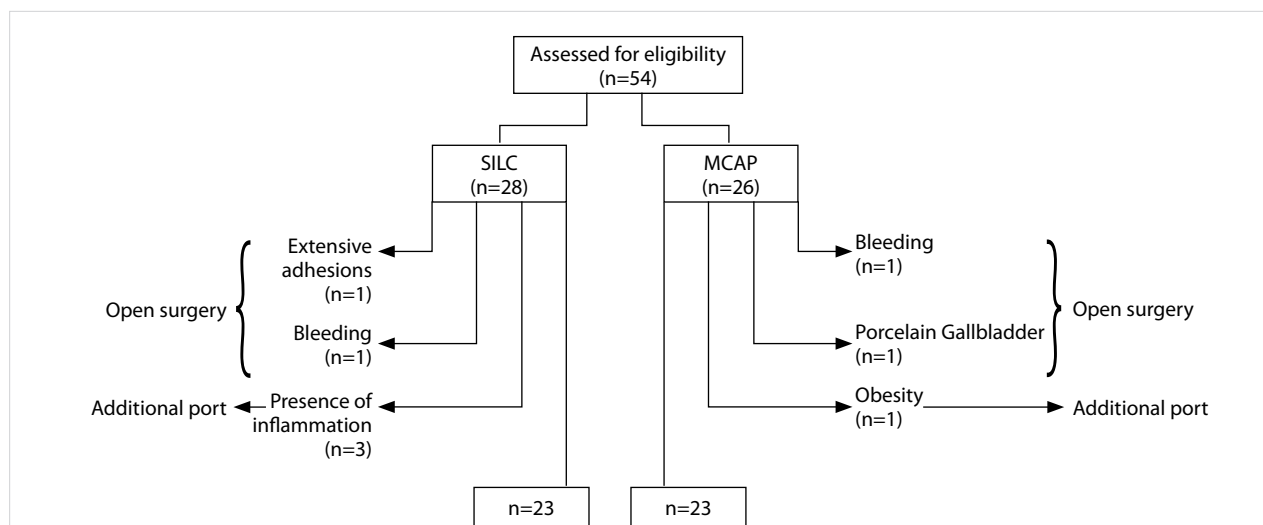


Figure 1. Flow-chart shows the study profile and the intraoperative findings of the excluded patients. In the SILC group, 2 operations were converted to open laparotomy and one operation could be continued after the addition of another port.

SILC: single-incision laparoscopic cholecystectomy

tients were followed monthly during the postoperative period (Figure 2c).

The umbilical fascial defect was closed with a Prolene™ (Ethicon, USA) loop, and the skin was closed with Vicryl™ (Ethicon, USA) in both methods. All patients were administered two doses of antibiotics (1 gram intravenous ampicillin-sulbactam) during and after surgery.

All patients were administered pethidine 50-100 mg IM (according to the patient's age and body mass) after surgery and 4 mL IV metamizole sodium during follow-up. Metamizole sodium was repeated at the same dose as required for analgesia. These repeated doses were accepted as the post-operative analgesia requirement data of the patients.

RESULTS

A total of 46 patients of both genders between the ages of 25 and 76 (mean 48.5±10.3) years were included in the study. There was no significant difference between the two groups in terms of age, BMI, ASA score, and pre-operative diagnosis (Tables 1 and 2).

Analysis of the intra-operative and post-operative data showed no difference for estimated blood loss, postoperative analgesia requirement, VAS scores on postoperative days 1 and 7, duration of hospitalization, and total complication rates. However, a significant difference was found between the two groups in terms of duration of surgery. The duration of surgery was significantly shorter in the MCAP method compared to the SILC method (35.0±12.3 and 79.1±27.7 min, respectively) (Table 3).

We used graspers that we inserted through the transumbilical port in order to achieve gallbladder retraction and reveal Calot's triangle anatomically in the MCAP method. Two graspers from the transumbilical port were used for 15 patients (65%), and one was used for 8 patients (35%) in this technique.

The postoperative complication rates were similar. Serous discharge occurred from the umbilicus in 4 patients in the SILC group and in 3 patients in the MCAP group. Routine wound care was used for treatment. No bile duct injury was found in any patient.

The rates of changing to another technique due to technical inadequacy were similar; 2 patients (7.1%) were changed to open

surgery, and 3 patients (10.7%) required an additional port in the SILC group. Two patients (7.7%) were changed to open surgery and another port was used in 1 patient (3.8%) in the MCAP group. These patients were excluded from the study.

DISCUSSION

The first results of the SILS method performed transabdominally through a port placed at a 1.5-2 cm umbilical incision were positive. This result was aided by the recently developed special ports, cameras providing better visibility, and devices with increased motility. The technique was used in surgical procedures involving many organs, such as the gallbladder, in the following years. However, some studies, published about 5 years af-

Table 1. The demographics of the patients

	SILC (n=23)	MCAP (n=23)	p value
Age (yr)	48.8±8.0	48.5±12.8	0.213
Female/Male	19/4	17/8	0.767
BMI (kg/m ²)	30.8±6.3	30.1±5.9	0.277
ASA (I/II/III)	10/8/5	9/10/4	0.510

SILC: single-incision laparoscopic cholecystectomy; MCAP: with an additional port using a multi-channel device through the umbilicus; Yr: year; BMI: body mass index; ASA: American Society of Anesthesiologists

Table 2. The preoperative findings of the patients

	SILC (n=23)	MCAP (n=23)
Previous abdominal surgery		
Upper	0	1
Lower	5	6
Both	1	0
Indications for cholecystectomy		
Chronic cholecystitis	19	20
Gallstone pancreatitis	0	0
Choledocholithiasis	1	1
Biliary dyskinesia	2	1
Polyp	1	1

SILC: single-incision laparoscopic cholecystectomy; MCAP: with an additional port using a multi-channel device through the umbilicus

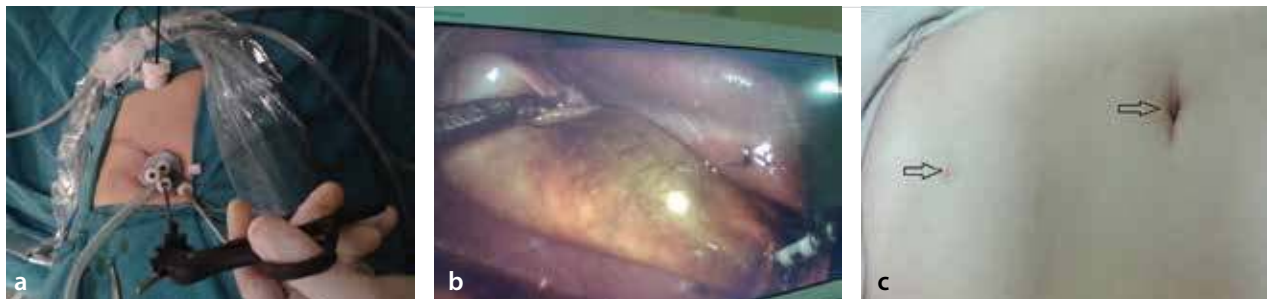


Figure 2. a-c. Trocar entry in the MCAP technique (a). One instrument elevates the gallbladder, and another dissects it in MCAP technique (b). View of the incisions in the first postoperative month of the MCAP technique (c).

MCAP: with an additional port using a multi-channel device through the umbilicus

ter the initial applications, mentioned some inadequacies and disadvantages of this method. Alptekin et al. (3) stated that SILC was not a superior method when compared with traditional laparoscopic cholecystectomy. Technical difficulties, such as the inability to work comfortably in a limited anatomical area, the proximity of the trocars, superposition of the instruments, and poor ergonomics, were the main reasons (3, 7). These factors prolong the operation time and may cause bile duct injury (8).

The results of some studies supported this notion. A meta-analysis of 9 randomized studies including 362 patients who underwent SILC was recently reported (9). Additional ports were required in 4 of these studies due to the difficulty of this method. The additional port usage rates were 3% to 67%. Surgeons have sought different techniques to overcome these technical challenges in recent years. This has led to modified methods, such as 2 ports and 3 ports, to provide various kinds of gallbladder retraction (10, 11). These techniques are claimed to be reliable, but suspension of the gallbladder is performed with sutures with at least 2 extra holes in the abdominal wall. Therefore, they could not shorten the surgery duration adequately. The modified dome down laparoscopic technique applied by Cui et al. (12) is performed with a 360° view of the cystic duct and gallbladder together and retrograde dissection to the porta hepatis. Although this technique reveals the ductal anatomy adequately and is therefore suggested to be reliable, it has no advantage in terms of operation time (average 80.3 minutes). The study of Tian et al. (11) is one of the recent studies. The mean operative time was 47.2 min in the method where a retraction suture was applied to the fundus with a needle-like retractor. However, no comparison was made with classical 3- or 4-port laparoscopic cholecystectomy or SILC, and data, such as postoperative analgesia, VAS score, and duration of hospitalization, were not evaluated in this study.

We observed that using an additional port instead of a suspension suture provided significant advantages, such as easier technique and shorter operative time, during our SILC experiences. The surgery duration was shortened by more than 50% in our patients, whereas we had aimed for 10%. There were many factors causing the surgery duration to be shortened in patients where we implemented an additional port. The first factor was a decrease in the number of instruments inserted into the abdomen through the umbilical port in this method. We inserted the

dissector through an additional trocar site and inserted the 1 or 2 graspers and the 5° camera through the umbilical port in the MCAP method. Superposition of the instruments was therefore prevented, and the instruments could move more freely in the abdomen. The second factor was the elimination of the hand superposition that the surgeon frequently encounters due to both hands being close to each other while holding the instruments. One hand of the surgeon is on the belly, and the other hand is on the epigastric region. We used a second grasper in patients whose gallbladders were not appropriate for retraction with a single grasper (increased gallbladder wall thickness, hydropic gallbladder, or large stone present on Hartmann's pouch). The help of an assistant holding the camera was needed in this case. The other factor was avoiding suspension sutures. This was the third factor providing a time advantage for the MCAP technique. One of the major causes for failure or gallbladder injury in the laparoscopic surgery technique is the inability to reveal the anatomy of Calot's triangle adequately. Therefore, suspension sutures were placed to expose Calot's triangle in the SILC technique. Some surgeons place a second suspension suture in Hartmann's pouch (13). The time spent for suspension of the gallbladder was 4 min on average in the method used by Tian et al. (11). We believe that the duration of this process is associated with the experience of the surgeon, and the time spent is at least 5-10 minutes. This process is repeated in some cases as a result of the needle being short or breaking due to a thick subcutaneous fat layer and prolongs the duration of suspending the gallbladder. We shortened the duration of surgery significantly by implementing the retraction procedure with 1 or 2 graspers we inserted through the umbilical port in the additional port method. Another advantage was minimizing the time loss occurring during frequent irrigation of the surgical field. The irrigation instrument is inserted through an additional port in this technique and provides simple and faster irrigation of the surgical site, as it is not superimposed with the other instruments, and enters the abdomen at a straighter angle. A significant advantage affecting the duration of surgery in the additional port application is the potentially shorter learning curve. The learning curve for the SILC technique has been reported to be 19 patients (14). Although the number of ports is lower in the MCAP technique that we used, it is a technique that may be implemented without difficulty, even in the first use of a surgeon who is experienced with laparoscopy, as it is similar to the classic laparoscopic techniques. The surgeons implementing this method in our clinic were surgeons who were experienced with the conventional laparoscopic technique. Despite this experience, while the first SILC surgery lasted 160 minutes, the first surgery of the additional ports technique performed on the same date lasted 35 minutes.

The postoperative pain and analgesia requirements, duration of hospitalization, and rates of changing to another procedure due to the inadequacy of the surgical procedure were similar between the methods, with no significant difference in our study. This may be due to the similar techniques, although the duration of surgery was different.

The prospective and randomized nature of our study is a significant advantage. There is no information in the literature about cases where an additional port was used during the surgery. Starting the surgery with an additional port is therefore important to obtain accurate data. This is a significant advantage of the current study.

Table 3. Intraoperative and postoperative findings of the patients

	SILC (n=23)	MCAP (n=23)	p value
Operating time	79.1±27.7	35.0±12.3	<0.05
Estimated blood loss (mL)	9.6±6.5	11.3±11.2	0.889
VAS.1 (1-10)	4.1±1.3	4.3±1.4	0.838
VAS.2 (1-10)	2.1±0.9	1.9±0.7	0.371
Analgesic	3.8±1.8	3.2±1.5	0.215
Hospital stay (day)	2.0±0.8	2.2±1.1	0.609
Postop complications (%)	17.3±4.2	13.0±3.7	0.386

SILC: single-incision laparoscopic cholecystectomy; MCAP: with an additional port using a multi-channel device through the umbilicus; VAS: visual analog scale

The lack of evaluation of the cosmetic expectations can be thought as a significant limitation. However, we asked all patients beforehand whether the 0.5-cm incision and scar tissue would create a cosmetic problem. Therefore, we made sure that the patients in whom we implemented the SILC and SILC with additional port techniques did not have a cosmetic expectation or did not consider it a problem. We therefore created a homogeneous group among the patients. Studies on larger series and studies evaluating the cosmetic expectation are also needed.

CONCLUSION

The SILC method has technical difficulties and disadvantages compared to long-term studies, unlike the results in its initial period of use. The difficulties encountered in this surgery can be overcome with the MCAP method. This method is more reliable and easier than the laparoscopic method. It prevents confusion during surgery and significantly reduces the duration required. However, an evaluation of both methods in terms of cosmetic expectations is required.

Ethics Committee Approval: Ethics committee approval was received for this study from the ethics committee of Kafkas University Faculty of Medicine (80576354-050-99/35).

Informed Consent: Informed patient consent form including their treatment protocol was taken from all patients included in this study.

Peer-review: Externally peer-reviewed.

Author Contributions: Concept - B.S.; Design - B.S., T.D., H.A., E.İ., M.S.E., Y.G., N.K.; Supervision - B.S., Y.G., N.K.; Funding - B.S., T.D., H.A., E.İ., M.S.E., Y.G., N.K.; Materials - B.S., T.D., H.A., E.İ., M.S.E., Y.G., N.K.; Data Collection and/or Processing - B.S., H.A., E.İ., M.S.E.; Analysis and/or Interpretation - B.S.; Literature Review - B.S.; Writer - B.S.; Critical Review - B.S., T.D., H.A., E.İ., M.S.E., Y.G., N.K.

Conflict of Interest: No conflict of interest was declared by the authors.

Financial Disclosure: The authors declared that this study has received no financial support.

REFERENCES

1. Yim GW, Jung YW, Paek J, Lee SH, Kwon HY, Nam EJ, et al. Transumbilical single-port access versus conventional total laparoscopic hysterectomy: surgical outcomes. *Am J Obstet Gynecol* 2010; 203: 26. [\[CrossRef\]](#)

2. Remzi FH, Kirat HT, Kaouk JH, Geisler DP. Single-port laparoscopy in colorectal surgery. *Colorectal Dis* 2008; 10: 823-826. [\[CrossRef\]](#)
3. Alptekin H, Yilmaz H, Acar F, Kafali ME, Sahin M. Incisional hernia rate may increase after single-port cholecystectomy. *J Laparoendosc Adv Surg Tech A* 2012; 22: 731-737. [\[CrossRef\]](#)
4. Baik SM, Hong KS, Kim YI. A comparison of transumbilical single-port laparoscopic appendectomy and conventional three-port laparoscopic appendectomy: from the diagnosis to the hospital cost. *J Korean Surg Soc* 2013; 85: 68-74. [\[CrossRef\]](#)
5. Ma J, Cassera MA, Spaun GO, Hammill CW, Hansen PD, Aliabadi-Wahle S. Randomized controlled trial comparing single-port laparoscopic cholecystectomy and four-port laparoscopic cholecystectomy. *Ann Surg* 2011; 254: 22-27. [\[CrossRef\]](#)
6. Hirano Y, Hattori M, Douden K, Shimizu S, Sato Y, Maeda K, et al. Single-incision plus one port laparoscopic anterior resection for rectal cancer as a reduced port surgery. *Scand J Surg* 2012; 101: 283-286. [\[CrossRef\]](#)
7. Brunt LM. Commentary on "Incisional hernia rate may increase after single-port cholecystectomy". *J Laparoendosc Adv Surg Tech A* 2012; 22: 738-739. [\[CrossRef\]](#)
8. Joseph M, Philips MR, Farrell TM, Rupp CC. Single incision laparoscopic cholecystectomy is associated with a higher bile duct injury rate: a review and a word of caution. *Ann Surg* 2012; 256: 1-6. [\[CrossRef\]](#)
9. Zehetner J, Pelipad D, Darehzereshki A, Mason RJ, Lipham JC, Katkhouda N. Single-access laparoscopic cholecystectomy versus classic laparoscopic cholecystectomy: a systematic review and meta-analysis of randomized controlled trials. *Surg Laparosc Endosc Percutan Tech* 2013; 23: 235-243. [\[CrossRef\]](#)
10. Sumiyoshi K, Sato N, Akagawa S, Hirano T, Koikawa K, Horioka K, et al. Single-incision laparoscopic cholecystectomy with needle graspers. *Hepatogastroenterology* 2012; 59: 325-328.
11. Tian MG, Zhang PJ, Yang Y, Shang FJ, Zhan J. Two-port laparoscopic cholecystectomy with modified suture retraction of the fundus: A practical approach. *J Minim Access Surg* 2013; 9: 122-125. [\[CrossRef\]](#)
12. Cui H, Kelly JJ, Litwin DE. Single-incision laparoscopic cholecystectomy using a modified dome-down approach with conventional laparoscopic instruments. *Surg Endosc* 2012; 26: 1153-1159. [\[CrossRef\]](#)
13. Cheng Y, Jiang ZS, Xu XP, Zhang Z, Xu TC, Zhou CJ, et al. Laparoscopic single-site cholecystectomy vs three-port laparoscopic cholecystectomy: a large-scale retrospective study. *World J Gastroenterol* 2013; 19: 4209-4213. [\[CrossRef\]](#)
14. Tay CW, Shen L, Hartman M, Iyer SG, Madhavan K, Chang SK. SILC for SILC: Single institution learning curve for single-incision laparoscopic cholecystectomy. *Minim Invasive Surg* 2013; 2013: 381628.