

Bile duct ischemia developing after reconstruction of the hepatic artery during the Whipple operation

Murat Çakır, Tefik Küçükkartallar, Ahmet Tekin, Fatma Betül Tuncer, Adil Kartal

ABSTRACT

A pancreaticoduodenectomy is a surgical procedure with a high morbidity and mortality rate. The injury of the hepatic artery may occasionally lead to intraoperative bleeding. Repair of the injured hepatic artery is of great importance in terms of maintaining the vascular supply of the liver. We report a case with an injury of the hepatic artery that was successfully reconstructed with the gastroduodenal artery and then developed a biliary leak due to bile duct ischemia at an early stage. A 33-year-old woman complaining of right upper quadrant pain was found to have a solid pseudopapillary tumor of the pancreas. She underwent an immediate pancreaticoduodenectomy, and her hepatic artery was injured during the operation. The arterial ends were sutured with primary anastomosis, because they could be aligned without any tension. The biliary leak occurred on postoperative day 2. We detected bile duct ischemia and reanastomosed the artery. The patient was discharged on postoperative day 8. Surgeons should be prepared for anomalies of the peripancreatic vascular structures during pancreaticoduodenectomy. Computed tomography angiography should be considered to reveal these anomalies before the surgery. Insufficiency of the biliary anastomosis due to bile duct ischemia in the postoperative period should be kept in mind, even in cases of successful repair.

Keywords: Bile duct, ischemia, reconstruction

INTRODUCTION

Despite the mortality of pancreaticoduodenectomy (PD) being decreased to lower than 5% in experienced centers, the morbidity of the procedure still remains 50%-60% (1, 2). The most common causes of mortality are sepsis, bleeding, and cardiovascular events (3).

Intraoperative bleeding typically occurs during the dissection of the portal vein. Vascular injury may also occasionally occur during other stages of the pancreaticoduodenectomy, especially in the presence of aberrant vascular structures. The injury of the hepatic artery is among the least common causes of intraoperative bleeding.

One of the rare but most important perioperative complications of PD is injury of the hepatic artery. We will discuss a case of successful reconstruction of an injured hepatic artery with the gastroduodenal artery and development of a massive biliary leak due to bile duct ischemia in the early postoperative period.

CASE PRESENTATION

Patient consent was obtained in the study. A 33-year-old woman was admitted to our hospital after she had been found to have a cystic mass in the head of the pancreas in another hospital while she was evaluated for right upper quadrant pain. A computed tomography scan of the upper abdomen revealed a mass (28 x 15 mm) that was reported as a pseudopapillary tumor of the pancreas. We proceeded with an endoscopic ultrasound, and a sample of the cystic fluid obtained during the procedure was evaluated both biochemically and histopathologically. The cystic fluid tested positive for mucin, CEA (6.17 ng/mL), and CA 19-9 (583 U/mL). ¹⁸F-FDG PET/CT imaging showed a mass lesion measuring 20 x 18 mm in the region of the head of the pancreas, with increased metabolic activity (SUV max: 7.99). The patient was discussed again in the tumor board meeting, and we proceeded with PD. A resectable mass measuring about 4 cm was seen at the head of the pancreas during the exploration. The common bile duct (6 mm in diameter) was hooked up. The gastroduodenal artery was ligated and cut. The hemigastrectomy was carried out by using a linear stapler. The distal pancreas was held by a Satinsky clamp. Then, the pancreas was cut with a cautery, and small bleeding that occurred while the head of the pancreas was removed was stopped with a bipolar cautery. At that time, heavy arterial bleeding was seen in the proximal region. It was considered that the splenic artery was injured, but no pulsations could be felt at the hilum of the liver. We decided that the hepatic artery was injured. It was seen that the hepatic artery was cut near its origin from the gastroduodenal artery

Department of General
Surgery, Necmettin Erbakan
University Faculty of Medicine,
Konya, Turkey

Address for Correspondence
Murat Çakır
e-mail: drmuratcakir@hotmail.com

Received: 30.06.2014
Accepted: 07.09.2014
Available Online Date: 26.11.2014

©Copyright 2015
by Turkish Surgical Association
Available online at
www.ulusalcerrahidergisi.org

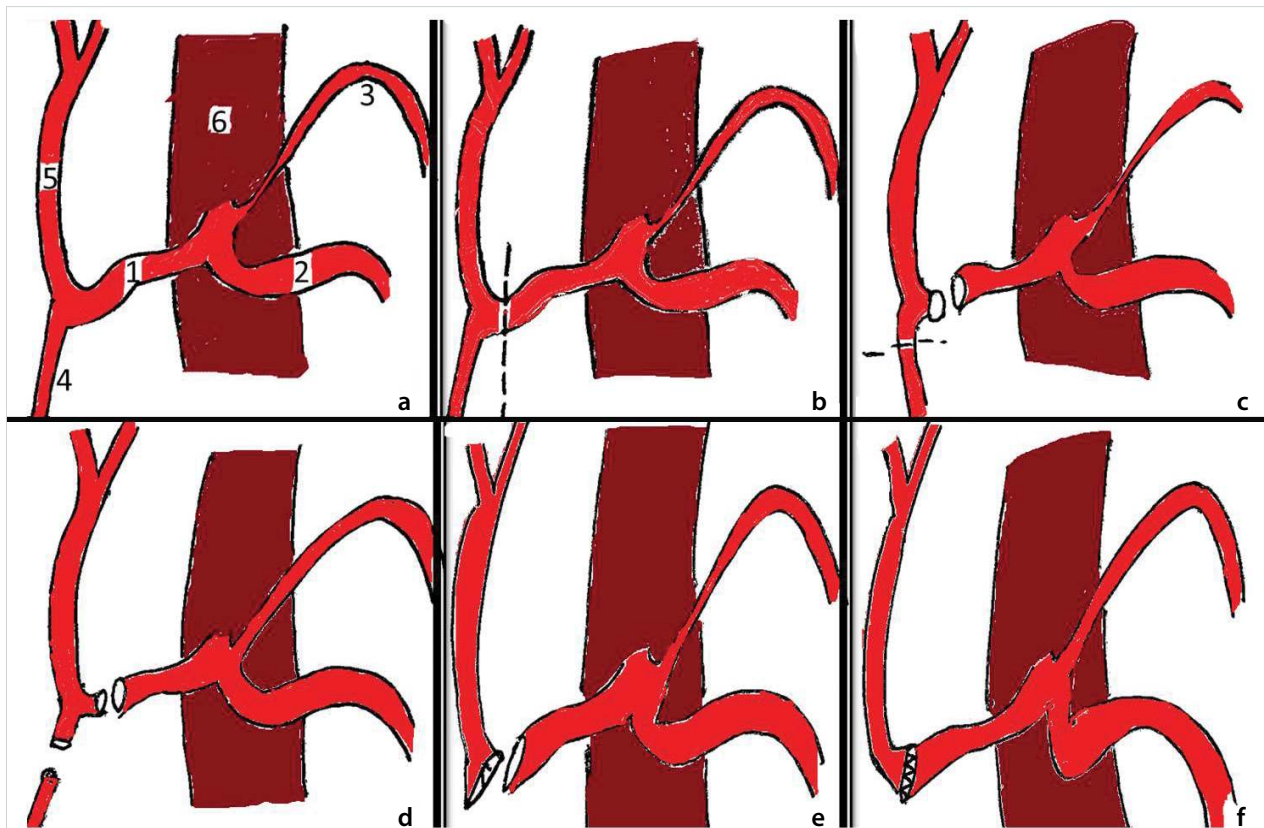


Figure 1. a-f. Hepatic artery injury and reconstruction 1: A. hepatica communis, 2: A. splenica, 3: A. gastrica sin., 4: A. gastroduodenalis, 5: A. hepatica propria, 6: aorta abdominalis (a) normal anatomical structure, (b) injury zone, (c, d): separation of A. gastroduodenalis for repair, (e) fixing diameter difference for anastomosis, (f) appearance after anastomosis

(Figure 1). The proximal part of the artery was clamped by a Satinsky clamp. The proximal and distal ends of the artery were dissected, and they were aligned without any tension. The distal end of the artery was joined to the orifice of the gastroduodenal artery, making a cuff. The cuff was spatulated. Thus, our aim was to have a proper-sized anastomosis between the relatively narrow-sized distal end and relatively large-sized proximal end (Figure 1). The repair was done by placing interrupted 6/0 Prolene sutures. A pulse could be felt at the hilum following the anastomosis. This procedure took approximately 30-35 minutes. The color in the left lobe of the liver due to ischemia returned back to normal. The intraoperative INR was reported to be within normal limits, and intraoperative transaminase levels were about 2 times above normal. Then, the rest of the PD was completed. Hepatic transaminase levels were not elevated above 3 times the upper limit of normal, and bilirubin levels were below 1.7 mg/dL. On postoperative day 1, a small amount of bile-stained fluid came out of the drains. On postoperative day 2, the biliary leakage suddenly increased (250-300 cc), and the patient underwent emergent surgery with a possible diagnosis of bile duct ischemia or biliary leak at the bile duct anastomosis. During the exploration, it was found that the anastomosis sutures were in place, but the bile duct was ischemic 1 cm above the line of anastomosis (Figure 2).

The ischemic bile duct was resected and anastomosed with 4/0 PDS. The patient was started on an oral regimen on postoperative day 5, the site of incision was closed on postoperative day 6, and the patient was discharged on postoperative

day 8. The pathology of the surgical specimen was reported as a solid pseudopapillary tumor of the pancreas. The CT angiography performed on postoperative day 15 visualized all of the arteries arising from celiac trunk, including the hepatic artery.

DISCUSSION

Although the mortality of PD is decreasing, the morbidity of the procedure remains as high as 50%-60%. The bleeding that occurs during or after the operation is an important cause of morbidity and mortality in pancreatic surgery. These and similar vascular anomalies make pancreatic surgery, especially PD, more difficult and complicated. These types of aberrant structures can be ligated, dissected, or cut and reconstructed in cases of tumor infiltration (4). Vascular injury, especially of the hepatic artery, may still occur during PD in the absence of any vascular anomalies. As seen in our case, the site of injury can affect the repair and the result. It has been shown that injury of the hepatic artery mostly occurs at the level of the proper hepatic artery (5).

Serious consequences may arise during or after the surgery when common vascular anomalies are not recognized. To avoid these problems, the hepatic pedicle should be well palpated after the duodenum is kocherized. If there is a pulsation on the lateral side of the hepatic hilum, a replaced right hepatic artery should be considered (4). In our case, bleeding was sudden and diffuse after the pancreatectomy was done, and it was from the proximal end of the cut artery. In situations like this, bleeding should be controlled by hand or a blood vessel device, and the vessels should not be handled by hemostatic

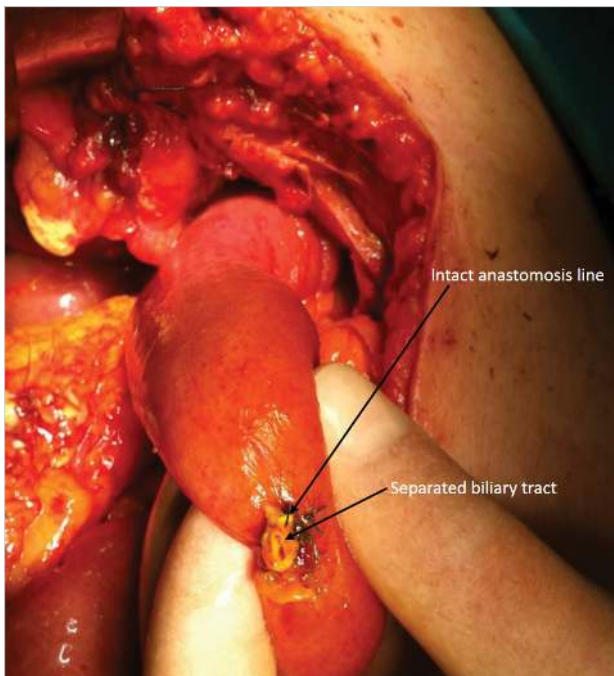


Figure 2. The bile duct was ischemic

clamps. Crushing forceps complicate the reconstruction and abolish the chance of primary surgical repair.

In cases of hepatic artery injury, the autogenic structures, like the gastroduodenal artery, splenic artery, or saphenous vein, should be preferred (5, 6). However, it is not necessary to put another piece of vessel when the cut ends of a vessel can be aligned without any tension, as in our case.

One should be aware of ischemia of the common bile duct or common hepatic duct that can develop following injury of the hepatic artery during PD, even it has been successfully repaired. Thus, the biliodigestive anastomosis should be close to the hepatic hilum. The anastomosis was done to the common bile duct in our case, since our patient was diagnosed with a solid pseudopapillary tumor of the pancreas. We had not thought of bile duct ischemia after successful repair of the injured hepatic artery. We also can not claim that we were experienced enough to predict that kind of ischemia following a very rare arterial complication. We think that although the repair of the hepatic artery was successful, the coagulation that occurred in the arterioles supplying the common bile duct or non-occlusive ischemia led to the bile duct ischemia. In a pancreaticoduodenectomy, ischemia that develops in the late stage of vascular injuries leads to benign strictures and its complications (7).

CONCLUSION

As a conclusion, surgeons should be prepared for injuries and anomalies of the peripancreatic vascular structures. Preoperative CT-angiography should be considered to reveal the anomalies before the surgery. It should be kept in mind that hepatic artery may be injured during PD. How the gastroduodenal artery is used in the repair of the injured hepatic artery should be decided first. Even the repair is successful, insufficiency of the biliodigestive anastomosis due to biliary duct ischemia in the postoperative period may still occur. Revision operations should be done immediately in case of a massive biliary leak.

Informed Consent: Written informed consent was obtained from patient who participated in this case.

Peer-review: Externally peer-reviewed.

Author Contributions: Concept - A.K.; Design - M.Ç.; Supervision - A.T.; Funding - M.Ç.; Materials - T.K.; Data Collection and/or Processing - M.Ç.; Analysis and/or Interpretation - M.Ç.; Literature Review - M.Ç.; Writer - M.Ç.; Critical Review - M.Ç., F.B.T.

Conflict of Interest: No conflict of interest was declared by the authors.

Financial Disclosure: The authors declared that this study has received no financial support.

REFERENCES

1. Birkmeyer JD, Finlayson SR, Tosteson AN, Sharp SM, Warshaw AL, Fisher ES. Effect of hospital volume on in hospital mortality with pancreaticoduodenectomy. *Surgery* 1999; 125: 250-255. [\[CrossRef\]](#)
2. Gordon TA, Bowman HM, Tielsch JM, Bass EB, Burleyson GP, Cameron JL. State wide regionalization of pancreaticoduodenectomy and its effect on in hospital mortality. *Ann Surg* 1998; 228: 71-78. [\[CrossRef\]](#)
3. Kazanjian KK, Hines OJ, Eibl G, Reber HA. Management of pancreatic fistulas after pancreaticoduodenectomy: Results in 437 consecutive patients. *Arch Surg* 2005; 140: 849-854. [\[CrossRef\]](#)
4. Shukla PJ, Barreto SG, Kulkarni A, Nagarajan G, Fingerhut A. Vascular anomalies encountered during pancreatoduodenectomy: do they influence outcomes? *Ann Surg Oncol* 2010; 17: 186-193. [\[CrossRef\]](#)
5. Sarmiento JM, Panneton JM, Nagorney DM. Reconstruction of the hepatic artery using the gastroduodenal artery. *Am J Surg* 2003; 185: 386-387. [\[CrossRef\]](#)
6. Gupta N, Solomon H, Fairchild R, Kaminski DL. Management and outcome of patients with combined bile duct and hepatic artery injuries. *Arch Surg* 1998; 133: 176-181. [\[CrossRef\]](#)
7. Kishi Y, Kajiwaru S, Seta S. Cholangio jejunal fistula caused by bile duct stricture after intraoperative injury to the common hepatic artery. *J Hepatobiliary Pancreat Surg* 2002; 9: 125-129. [\[CrossRef\]](#)