

Endoscopic stent placement in the management of malignant colonic obstruction: Experiences from two centers

Bünyamin Gürbulak¹, Esin Kabul Gürbulak², İsmail Ethem Akgün², Kenan Büyükaşık¹, Hasan Bektaş¹

ABSTRACT

Objective: Intestinal obstruction due to colorectal tumors requires immediate surgical decompression. Endoscopic stent placement for acute malignant colonic obstruction is gaining widespread acceptance as an alternative to emergency surgery. Our aim in this study was to evaluate the success and complication rates of endoscopic stenting for malignant colonic obstruction.

Material and Methods: Patients with acute malignant colonic obstruction who underwent endoscopic stenting between 2011-2014 were retrospectively reviewed. Data included demographic features, localization of obstruction, endoscopic stenting indications, rate of technical and clinical success, complications, morbidity and mortality.

Results: Endoscopic stent was successfully placed in 77 out of 82 procedures (93.9%). A colostomy was placed in five cases in which endoscopic stent could not be inserted. There were complications in seven patients with technically successful stents (9.0%). These included three stent migrations, one perforation, and rectal hemorrhage in three patients. There were no stent-related deaths.

Conclusion: The mortality rate of emergency surgery for malignant bowel obstruction is relatively high. The use of colonic stents can avoid surgery in patients who are not suitable for emergency surgery and may allow adequate time for preoperative preparation, counseling and staging for those who are suitable for further intervention. We believe that self-expandable metallic stent placement is a safe, effective, and minimal invasive alternative treatment method for malignant colonic obstruction.

Keywords: Colorectal carcinoma, self-expandable colonic stent, malignant intestinal obstruction

INTRODUCTION

Intestinal obstruction is one of the major complications of colorectal tumors that usually require emergent surgery for decompression. According to the 2007-2008 Ministry of Health cancer registry data from twelve cities, 150,000 cases have been annually diagnosed with cancer. Colorectal cancer ranks fourth in men with an incidence of 20.8 per 100 thousand, and third in women with 13.2 per 100 thousand (1). In our country, colorectal cancer is usually diagnosed at advanced stages, and it is reported that 25-30% of these cases present to the emergency clinics with obstruction. Due to the poor clinical overall condition of patients admitted to the emergency clinics with obstruction, mortality and morbidity rates are reported to be 10-30% and 40-50% for traditional emergency surgery, respectively (2). Moreover, many patients may have to live with temporary or permanent colostomy. At this stage, endoscopic stents can be used for palliation or as an alternative treatment method to delay surgery and avoid unnecessary mortality risk. The other advantages of endoscopic stenting, which is gaining increasing acceptance as an alternative method to emergency surgery for colonic obstruction, include performing full colonoscopy, staging of the disease, gaining time for evaluation of the patient's medical status and preparing for the operation more safely, and reducing the rate of stoma creation. It has also been suggested that endoscopic stenting followed by elective surgery is more cost-effective than primary emergency surgery (3).

Among the potential complications of the procedure are technical or clinical failure, perforation, hemorrhage, and stent migration (4, 5). In addition to these, there is concern on increased systemic spread of the disease due to shedding tumor cells in the systemic circulation (6). Nevertheless, it has been reported that there is no difference in long-term survival rates of patients undergoing elective surgery after stenting and those who underwent emergency surgery without stent insertion, from an oncologic point of view (7). Endoscopic stent insertion also requires relevant expertise and experience. The process requires that the stent, endoscopic equipment and supportive health personnel should be accessible at all times. The success rate of emergency endoscopic colonic stents in neoplastic obstruction is estimated as 76%, with an overall mortality rate of 0.58% (8).

¹Clinic of General Surgery, İstanbul Training and Research Hospital, İstanbul, Turkey

²Clinic of General Surgery, Şişli Hamidiye Etfal Training and Research Hospital, İstanbul, Turkey

Address for Correspondence

Bünyamin Gürbulak

İstanbul Eğitim ve Araştırma Hastanesi, Genel Cerrahi Kliniği, İstanbul, Türkiye

Phone: +90 212 414 20 00
e-mail: bgurbulak@gmail.com

Received: 20.07.2014

Accepted: 15.08.2014

Available Online Date: 24.06.2015

©Copyright 2015
by Turkish Surgical Association
Available online at
www.ulusalcerrahidergisi.org

The aim of this study was to evaluate the success and complication rates of endoscopic stent insertion in acute colonic obstruction due to colorectal tumors.

MATERIAL AND METHODS

Seventy-seven patients who had successful stent placement out of 82 consecutive patients with acute malignant colonic obstruction who underwent endoscopic stenting between 2011-2014 at Istanbul Training and Research Hospital and Şişli Hamidiye Etfal Training and Research Hospital, General Surgery, Endoscopy Unit were retrospectively reviewed. The procedure failed in five patients, all of whom underwent emergent colostomy creation.

The majority of patients had accompanying co-morbidities on admission. The most common co-morbidity was cardiovascular disease, 22 patients had ischemic heart disease and hypertension and were on anticoagulant and antihypertensive treatment, and 32 patients were receiving antihypertensive therapy for hypertension alone. Twelve patients with a history of diabetes were found to have disorders related to glycemic control, acid-base homeostasis and electrolyte balance. Chronic obstructive pulmonary disease (COPD) history was identified in 18 cases. Nine patients had up to 15% weight loss within the last 3 months, and their malnutrition indicators were serum albumin levels <3 g/dL and lymphocyte count <1000/mm³ (Table 1).

On admission, 45 patients had not been previously diagnosed with colon malignancy, and they did not have any previous histopathologic examination. The remaining 32 patients were previously diagnosed with colon malignancies, 21 of them had advanced stage disease and have been under oncological treatment due to distant metastases, and 11 patients had declined the previously proposed surgical treatment. The indications for stent placement are shown in Table 2.

Before the procedure, informed consent was obtained from all patients. Experienced endoscopists and assistant team performed the procedures under sedation administered by anesthesiologists. The length of the stents was selected by calculating the length of the tumor segment on abdominal tomography, which was obtained from all patients prior to the procedure. Uncovered self-expanding metallic stents that extend at least 2 cm from the proximal and distal edges of the tumor were preferred. All of the procedures were performed without the use of fluoroscopy. A plain abdominal radiograph was obtained in all patients after stent placement to check for the presence of sub-diaphragmatic free air and the location of the stent. All patients were kept under observation in the clinic. They were discharged approximately 2 days (1-4) after admission.

Data on demographic features as well as localization of obstruction, endoscopic stenting indications, and rates of technical and clinical success, complications, morbidity and mortality were analyzed.

Table 1. Co-morbidities in patients who underwent endoscopic stent placement due to acute tumoral colonic obstruction

Co-morbidity	Patient number (n)	Percentage within all cases (%)
Ischemic heart disease	22	28.5
Anticoagulant treatment	22	28.5
Hypertension	32	41.5
Ischemic heart disease and hypertension	54	70.1
Diabetes mellitus	12	15.5
COPD	18	23.3
Severe malnutrition	9	11.6

COPD: Chronic Obstructive Pulmonary Disease

Table 2. Previous diagnosis and endoscopic stenting intention in patients who underwent endoscopic stent placement due to acute tumoral colonic obstruction

Intention for treatment	Patient number (n)			%
	Previously diagnosed (n)	No previous diagnosis (n)	Total (n)	
Bridge to surgery	11	25	36	46.7
Palliation	21	20	41	53.2
Total	32	45	77	

Statistical Analysis

Descriptive statistics were used to assess the patients.

RESULTS

Colonic stents have been successfully implemented in 77 patients. This group included 36 female and 41 male patients with a mean age of 58.7 (19-86) years. The most common site was the sigmoid colon (n=26). The remaining sites in decreasing order were the rectosigmoid region (n=23), left colon (n=19), transverse colon (n=6), left flexure (n=2) and right colon (n=1) (Table 3). Intention for stent placement was bridge to elective surgery in 36 patients, while 41 patients underwent palliative stent placement. Three tumors of the five cases where stent insertion failed were located at the splenic flexure, and two had obstructive rectosigmoid tumors. These patients underwent emergent stoma creation since stenting was unsuccessful.

Endoscopic stent placement was done within the first 14 hours after receiving the diagnosis of acute colonic obstruction (2-24). Bowel continuity was obtained immediately after the procedure (Figure 1, 2). None of the patients developed complications during the procedure. All patients were under observation at the clinic after the procedure. The location of the stent was controlled with plain upright abdominal radiographs (Figure 3). After the gastrointestinal passage is achieved, there was a rapid improvement in patients' fluid and electrolyte balance. Anticoagulation treatment was con-

Table 3. Location of colon tumors causing acute obstruction

Tumor location	Patient number (n)	(%)
Sigmoid colon	26	33.7
Rectosigmoid region	23	29.8
Left colon	19	24.6
Transverse colon	6	7.7
Left flexura	2	2.5
Right colon	1	1.2

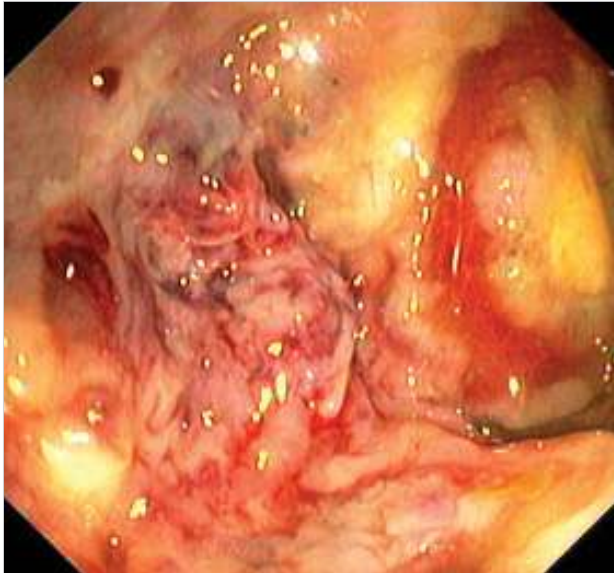


Figure 1. A large tumor completely obstructing the rectosigmoid region

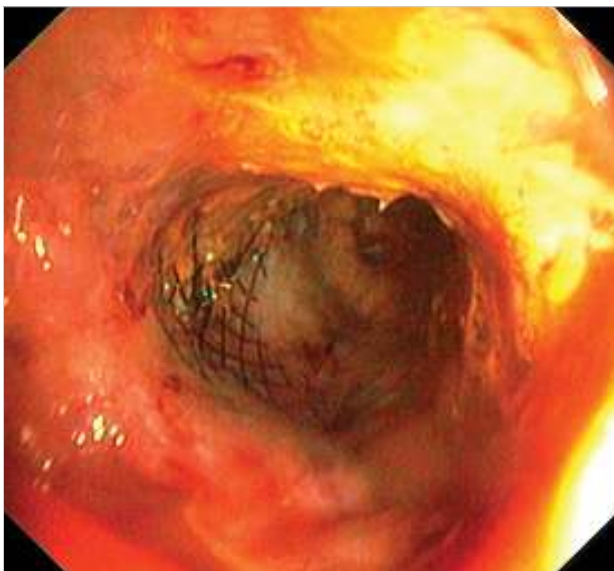


Figure 2. The self-expandable stent within an obstructing rectosigmoid tumor with patent gastrointestinal continuity

tinued with low molecular weight heparin in patients previously receiving such treatment. Oral liquid diet was started 24 hours after the procedure. Upon gas discharge, patients were discharged with oral laxatives, and low residue dietary agents. The mean length of hospital stay was 2 days (1-4).

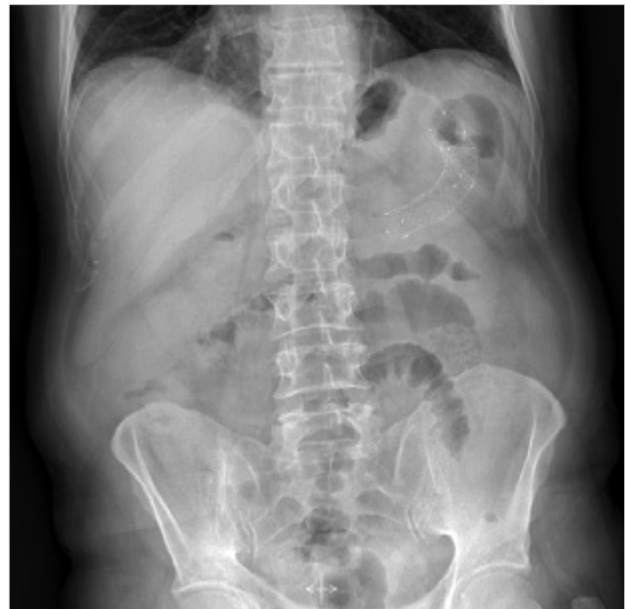

Figure 3. Location of the stent on the upright abdominal X-ray following endoscopic stent placement for a left flexure tumor

After elimination of the obstruction, a full colonoscopy following bowel cleansing was performed in patients scheduled for elective surgery. Four of the 36 patients who were candidates for elective surgery refused surgical treatment, the preoperative preparation of 32 patients were completed in optimal conditions. They were operated on electively 6 days (3-10) after endoscopic stenting. All of the patients who were operated on underwent laparoscopic surgery.

Forty-one patients with advanced stage colon tumors with liver metastases were directed to oncologic treatment after palliative stent placement. The early post-stenting complications included a patient with rectosigmoid tumor who had colon perforation 5 days after stent placement (Figure 4). This patient was operated under emergent conditions due to acute abdomen, and underwent colostomy creation. Three patients with rectosigmoid tumors and a history of anticoagulation treatment were re-admitted due to rectal bleeding 7-10 days after stent placement. The bleeding spontaneously stopped within 48 hours with conservative treatment, without the need for further endoscopic or surgical intervention. As for late complications, a stent migrated to the left flexure in a patient with sigmoid colon tumor one month after the stent procedure. The second endoscopic stent procedure failed, thus the patient received colostomy. The stent has fallen in a patient with sigmoid colon tumor and another patient with rectosigmoid tumor who underwent systemic chemotherapy 1 and 1.5 months after stent placement, respectively. A repeat stenting was not performed in those patients since they did not develop signs of obstruction. The overall complication rate including early and late complications comprised of seven patients out of 77 patients with colonic stent insertion, yielding a rate of 9%. The technical success rate of 77 out of 82 cases was determined as 93.9%, while the clinical success rate was found to be 90.9% due to complications in seven patients. Success and complication rates are summarized in Table 4.

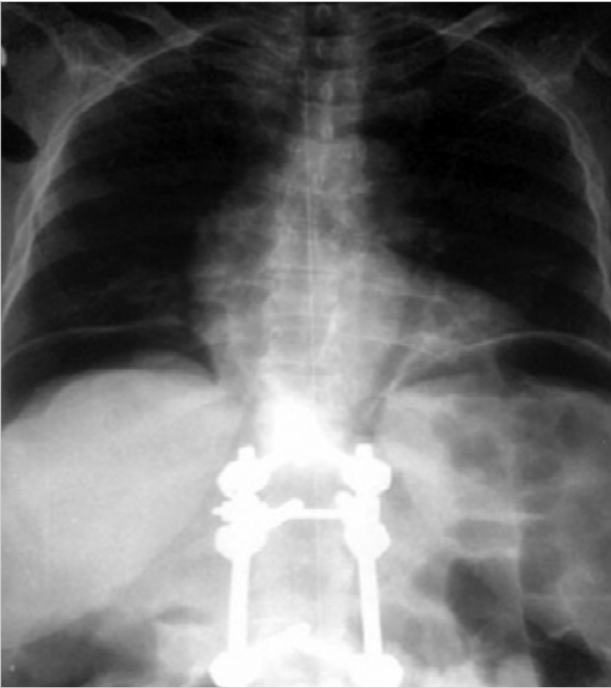


Figure 4. Subdiaphragmatic free intraabdominal air in a patient's upright abdominal X-ray 5 days after stenting of a tumoral obstruction in the rectosigmoidal region who underwent emergent surgery due to colon perforation

Table 4. Complications, technical and clinical success rates after endoscopic colonic stent placement

Total case (n) (%)	Technical success (n) (%)	Complication	Patient number (n)	%	Management	Clinical success (n) (%)
82 (100)	77 (93.9)	Migration	3	3.8	1 patient stoma creation	
					2 patients follow-up	70 (90.9)
		Perforation	1	1.2	Stoma creation	
		Bleeding	3	3.8	Follow-up	

Most patients were stented to achieve palliation. The mean follow-up of these patients was 10 months (1-18) and they succumbed due to systemic disease progression. None of the cases who underwent surgery experienced complications due to stenting in, intraoperative or postoperative period. There was no stent-related mortality.

DISCUSSION

The incidence of mechanical bowel obstruction as a complication of advanced colorectal tumor ranges from 7-47% (9). This condition requires surgical intervention to provide emergency gastrointestinal decompression. These patients are under the risk of dilated bowel loop necrosis and perforation. Severe fluid and electrolyte imbalance and bacterial translocation increase postoperative morbidity and mortality rates. Moreover, the increase in the incidence of cardiovascular disease with advanced age causes additional co-morbidity to patients with colorectal tumors. Emergency surgery has a high mortality rate in such patients. The mortality rate

of emergency surgery in those patients with malignant colon obstruction are reported to vary between 10-30%, and the rate of morbidity as 39%, while the mortality rate after elective colorectal surgery is reported to be less than 5% (2, 10). Self-expanding metallic stents, which are being applied for colonic decompression of acute colorectal tumor obstruction, are widely accepted as an alternative to emergency surgery (8).

The success rate of the procedure is reported to be high. Blake et al. (4) reported the technical and clinical success rates as 86% and 84%, respectively, and the complication rate as 22.5%. Athreya et al. (11) reported the success rate as 85%. Considering our results, our technical and clinical success rates of 93.9% and 90.9% seem to be higher, and the complication rate of 9.0% lower. The five cases in whom the procedure failed underwent stoma creation.

A successful colonic stent placement provides emergent colonic decompression and gastrointestinal passage as well as rapid recovery of fluid and electrolyte balance, while giving enough time for the performance of surgical preparation of those patients who are candidates for elective surgery. The incidence of synchronous tumors in the colon ranges from 1.5 to 9% (average 5%) (12, 13). Adenomatous polyp or polyps accompany primary colorectal tumors in 15-50% (14). Therefore, the entire colon should be endoscopically evaluated prior to surgery for colorectal tumors. Endoscopic stent placement allows for full colonoscopy before surgery and helps in ruling out the existence of possible accompanying synchronous tumors or polyps. The presence of a synchronous tumor is a factor that will change the type of operation. Excluding the presence of synchronous tumors in the colon has a great importance especially in patients scheduled for laparoscopic definitive surgery.

Endoscopic stent placement should be preferred instead of an emergency surgical approach that will fail (15). In that regard, NICE (The National Institute of Clinical Excellence) guidelines proposes the establishment of emergency surgical endoscopy units to allow placement of endoscopic colonic stents as an alternative to immediate surgical intervention in patients with acute colonic obstruction (16). The literature indicates that it is safe to do so. However, certain conditions need to be met for endoscopic stent placement. Generally, these conditions are related to the operation of the hospital, including availability of an experienced endoscopist and associated assistant team, the proper stent and appropriate equipment, when required. The operating room should be on stand-by in case of procedure failure or occurrence of complications.

Despite the risk of late complications, endoscopic stenting is being used in the effective palliation of malignant colonic obstruction. Stents inserted for palliation remain open until the death of the patient due to disease progression thus providing intestinal passage, and constitutes an acceptable level of quality of life. All stent related complications in our series were observed in patients undergoing palliative stent insertion. The lack of complications in patients who were stented for bridge-to-surgery and who underwent elective

surgery suggested that these patients were prepared rapidly and had the stents for a shorter time. The stent related perforation rate is reported to be 3.8% in the literature, and the stent migration rate as 11.8% (8). In our cases, perforation during the procedure did not occur in any patient, but one patient developed colon perforation five days after the procedure due to the stent. Our stent migration rate was 3.8%, with a case of stent migration and two cases of stent falling; our complication rate is consistent with rates reported in the literature. The rate of bleeding following endoscopic stent placement is stated to be less than 5% (17, 18). Although the mechanism of post-stent bleeding is not well defined in the literature, it is often reported to occur weeks after stent insertion. As a possible mechanism, it is stated that sharp edges of the metal stent cause mucosal erosion and ulcer formation, therefore leading to bleeding, and that most of these bleeding stopped spontaneously (19). In our series, three patients who were re-admitted due to rectal bleeding 7 to 10 days after stent placement had a history of ischemic heart disease and anticoagulant therapy use. Such cases may be related to stent related mucosal erosion or it can be considered that anticoagulant therapy facilitated the bleeding.

Given that colonic stents have been used for approximately 10 years, it is reasonable to think that as the learning curve improves the success and complication rates will improve (5).

An emergent surgical procedure for acute colonic tumor obstruction will add a high mortality risk to the patient, as well as leading to creation of a stoma. Colonic stent placement is a minimally invasive and safe method with decreased cost and mortality due to a decrease in stoma requirement by 83% (3). Moreover, endoscopic stenting enables clinical staging of the disease and allows performing the planned radical surgery in one session.

CONCLUSION

This study aimed to emphasize that colonoscopic stent placement is a safe and effective treatment method for malignant colorectal obstruction. It is obvious that the procedure-related serious complications rates reported in the literature are relatively low than the morbidity and the mortality rates of emergent surgical procedures. Our study provides additional information that supports current data related to endoscopic stenting in the treatment of acute colonic obstruction due to a tumor. However, the weakness of our study is its retrospective nature. Prospective, randomized studies including more cases will be of great benefit.

Ethics Committee Approval: Ethical approval has not been received in this study, which was designed retrospectively by scanning open access patient data in computer in general surgery clinics.

Informed Consent: Informed patient consent form including the disease and colonoscopic stent insertion procedure was obtained from all patients included in this study.

Author Contributions: Concept - B.G., E.K.G., İ.E.A.; Design - B.G., E.K.G., H.B.; Supervision - H.B.; Funding - B.G., E.K.G.; Materials - B.G., E.K.G.; Data Collection and/or Processing - B.G., E.K.G.; Analysis and/or Interpretation - B.G., E.K.G., İ.E.A., K.B., H.B.; Literature Review - B.G., E.K.G., H.B.; Writer - B.G., E.K.G.; Critical Review - B.G., E.K.G., İ.E.A., K.B., H.B.; Other - B.G., E.K.G.

Conflict of Interest: No conflict of interest was declared by the authors.

Financial Disclosure: The authors declared that this study has received no financial support.

REFERENCES

1. Sağlık Bakanlığı Kanserle Savaş Dairesi Başkanlığı 2006-2008 yılları Türkiye Kanser İnsidansı, Available from: URL: <http://kanser.gov.tr/daire-faaliyetleri/kanser-kayitciligi/108-turkiyede-kanser-kayitcigi.html>
2. Riedl S, Wiebelt H, Bergmann U, Hermanek P. Postoperative complications and fatalities in surgical therapy of colon carcinoma. Results of the German multicenter study by the Colorectal Carcinoma Study Group. *Chirurg* 1995; 66: 597-606.
3. Targownik LE, Spiegel BM, Sack J, Hines OJ, Dulai GS, Gralnek IM, et al. Colonic stent vs. emergency surgery for management of acute left-sided malignant colonic obstruction: a decision analysis. *Gastrointest Endosc* 2004; 60: 865-874. [CrossRef]
4. Blake P, Delicata R, Cross N, Sturgeon G, Hargest R. Large bowel obstruction due to colorectal carcinoma can be safely treated by colonic stent insertion-case series from a UK district general hospital. *Colorectal Dis* 2012; 14: 1489-1492. [CrossRef]
5. Mainar A, De Gregorio Ariza MA, Tejero E, Tobío R, Alfonso E, Pinto I, et al. Acute colorectal obstruction: treatment with self-expandable metallic stents before scheduled surgery-results of a multicenter study. *Radiology* 1999; 210: 65-69. [CrossRef]
6. Koch M, Kienle P, Sauer P, Willeke F, Buhl K, Benner A, et al. Hematogenous tumor cell dissemination during colonoscopy for colorectal cancer. *Surg Endosc* 2004; 18: 587-591. [CrossRef]
7. Bonin EA, Baron TH. Update on the indications and use of colonic stents. *Curr Gastroenterol Rep* 2010; 12: 374-382. [CrossRef]
8. Sebastian S, Johnston S, Geoghegan T, Torreggiani W, Buckley M. Pooled analysis of the efficacy and safety of self expanding metal stenting in malignant colorectal obstruction. *Am J Gastroenterol* 2004; 99: 2051-2057. [CrossRef]
9. Chen W, Tan XP, Ye JW, Liu Q, Zeng Q, Wang L, et al. Effect of bowel obstruction on stage IV colorectal cancer. *Mol Clin Oncol* 2014; 2: 308-312.
10. Kamocki ZK, Zaręba KP, Bandurski R, Baniukiewicz A, Wróblewski E, Gryko M, et al. Own experiences of endoscopic self-expandable stent placement for malignant colorectal ileus. *Wideochir Inne Tech Malo Inwazyjne* 2014; 9: 59-63. [CrossRef]
11. Athreya S, Moss J, Urquhart G, Erdwards R, Downie A, Poon FW. Colorectal stenting for colonic obstruction: the indications, complications, effectiveness and outcome-5 year review. *Eur J Radiol* 2006; 60: 91-94. [CrossRef]
12. Wexner SD. Neoplastic disorders of the colon. In: Wexner SD, Stollman N editors. *Disease of the colon*. 1st ed. New York: Informa Healthcare Inc; 2007. p. 489-506.
13. Otchy D, Hyman N, Simmang C, Anthony T, Buie W, Cataldo P, et al. Practice parameters for colon cancer. *Dis Colon Rectum* 2004; 47: 1269-1284. [CrossRef]
14. Kim MS, Park YJ. Detection and treatment of synchronous lesions in colorectal cancer: The clinical implication of perioperative colonoscopy. *World J Gastroenterol* 2007; 13: 4108-4111. [CrossRef]

15. Søreide K. Emergency management of acute obstructed left sided colon cancer: loops, stents or tubes? *Endoscopy* 2013; 45: 247-248. [CrossRef]
16. NICE (National Institute for Health and Care Excellence) guidelines. Colorectal cancer: The diagnosis and management of colorectal cancer. 2011 Nov. Available from: URL: <http://www.nice.org.uk/nicemedia/pdf/CSGCCfullguidance.pdf>
17. Khot UP, Lang AW, Murali K, Parker MC. Systematic review of the efficacy and safety of colorectal stents. *Br J Surg* 2002; 89: 1096-1102. [CrossRef]
18. Gukovsky-Reicher S, Lin RM, Sial S, Garrett B, Wu D, Lee T, et al. Self-expandable metal stents in palliation of malignant gastrointestinal obstruction: review of the current literature data and 5-year experience at Harbor-UCLA Medical Center. *Med Gen Med* 2003; 5: 16.
19. Wai CT, Khor C, Lim SE, Ho KY. Post-metallic stent placement bleeding caused by stent-induced ulcers. *World J Gastroenterol* 2005; 11: 5739-5741.