

Missed retrosternal ectopic thyroid tissue in a patient operated for multinodular goiter

Multinodüler guatr operasyonu yapılan hastada, unutulmuş retrosternal ektopik tiroid dokusu

Uğur Kesici¹, Özgür Koral², Savaş Karyağar³, Sevgi Kesici⁴, Aysun Yılbaş⁵, Sevda Karyağar³, Emine Mataracı⁶, İlker Mataracı²

ABSTRACT

Ectopic thyroid tissue has been found from the tongue to the diaphragm. The most common ectopic thyroid tissue has been found in the tongue, submandibular region, cervical lymph nodes, larynx, trachea, oesophagus, mediastinum, diaphragm and heart respectively. "Forgotten goiter" is an extremely rare disease which is defined as a mediastinal thyroid mass found after total thyroidectomy. In this case report, we discussed a 49 year-old female patient whose retrosternal ectopic thyroid tissue was detected by thyroid scintigraphy taken in postoperative period after total thyroidectomy performed with diagnosis of multinodular goiter. Papillary carcinoma was determined by the histopathological examination. Ectopic thyroid tissue was removed by performing sternotomy. We did not observe any postoperative surgical complications. 100 mCi dose of radioactive iodine was administered to the patient. Retrosternal ectopic thyroid tissue detected after total thyroidectomy is a rarely encountered condition. Therefore, retrosternal ectopic thyroid tissue existence should be definitely kept in mind in patients with no increase in thyroid stimulating hormone level after total thyroidectomy.

Keywords: Total thyroidectomy, retrosternal, ectopic, thyroid, goiter

ÖZET

Ektopik tiroid dokusu, dilden diyaframa kadar bulunabilir. En yaygın olarak sırasıyla dil, submandibular bölge, servikal lenf nodları, larinks, trakea, özofagus, mediasten, diyafram ve kalpte bulunur. "Unutulmuş guatr" total tiroidektomi sonrası bulunan mediastinal tiroid dokusu olarak tanımlanan oldukça nadir görülen bir durumdur. Bu olgu sunumunda multinodüler guatr tanısı ile total tiroidektomi uygulandıktan sonra postoperatif dönemde çekilen tiroid sintigrafisinde retrosternal ektopik tiroid dokusu tespit edilen 49 yaşında kadın hasta tartışıldı. Histopatolojik incelemesinde papiller karsinom tespit edildi. Ektopik tiroid dokusu sternotomi uygulanarak çıkarıldı. Postoperatif herhangi bir komplikasyon izlenmedi. Hastaya 100 mCi radyoaktif iyot tedavisi uygulandı. Total tiroidektomi sonrası retrosternal ektopik doku tespit edilmesi oldukça nadir görülen durumdur. Bu nedenle total tiroidektomi sonrası tiroid stimulan hormon düzeyi yükselmeyen hastalarda retrosternal ektopik tiroid dokusu varlığı mutlaka akılda bulundurulmalıdır.

Anahtar Kelimeler: Total tiroidektomi, retrosternal, ektopik, tiroid, guatr

INTRODUCTION

Ectopic thyroid tissue is a common abnormality due to the abnormal embryological development and migration of thyroid tissue. Ectopic thyroid tissue is commonly seen in the midline of the neck throughout the descending pathway of the thyroid gland (1). Ectopic thyroid tissue can be found from the tongue to the diaphragm. Ectopic thyroid tissue is usually seen in the tongue, submandibular region, cervical lymph nodes, larynx, trachea, oesophagus, mediastinum, diaphragm and heart respectively (2, 3). Although the most common type of ectopic thyroid tissue is lingual, the most common non-cervical location is the thoracic cavity (1). "Forgotten goiter" is an extremely rare situation which is described as a mediastinal thyroid mass found after total thyroidectomy (4).

In this article, a case report of a patient with retrosternal ectopic thyroid tissue detected after total thyroidectomy, is presented.

CASE PRESENTATION

We obtained consent from the patient for publication of this case report. In this case report, we discussed a 49 year-old female patient whose retrosternal ectopic thyroid tissue was detected by thyroid scintigraphy taken in postoperative period after total thyroidectomy performed with diagnosis of multinodular goiter. Approximately 3-4 years of swelling and pinching sensation was present on the neck in the anamnesis of the patient who was followed due to multinodular goiter. Palpable nodules were present in both thyroid lobes in physical examination of the patient. Palpable lymph nodes were not present in the neck in physical examination. The right lobe of the thyroid gland was 6 x 2 x 2 cm, the left lobe was 7 x 2.5 x 2 cm and the thickness of isthmus was 1 cm in the neck ultrasonography (USG) of the patient. There were no pathological lymph nodes. Multiple nodules, the largest being over 4 cm on the right (hypoechoic, irregular edged with peripheral halo), were detected in both thyroid lobes in the neck USG of the patient. It was decided to perform total thyroidectomy to the patient. Preoperative

¹Department of General Surgery, Giresun University Faculty of Medicine, Giresun, Turkey

²Clinic of Cardiovascular Surgery, Ahi Evren Thoracic and Cardiovascular Surgery Training and Research Hospital, Trabzon, Turkey

³Clinic of Nuclear Medicine, Kanuni Training and Research Hospital, Trabzon, Turkey

⁴Department of Anesthesiology and Reanimation, Giresun University Faculty of Medicine, Giresun, Turkey

⁵Department of Anesthesiology and Reanimation, Hacettepe University Faculty of Medicine, Ankara, Turkey

⁶Clinic of Pathology, Akçaabat Hacıhalı Baba State Hospital, Trabzon, Turkey

Address for Correspondence Yazışma Adresi

Uğur Kesici

e-mail: ugurkesici77@myynet.com

Received / Geliş Tarihi: 24.09.2014

Accepted / Kabul Tarihi: 13.10.2014

Available Online Date /

Çevrimiçi Yayın Tarihi: 19.06.2015

©Copyright 2016

by Turkish Surgical Association

Available online at

www.ulusalcerahidergisi.org

©Telif Hakkı 2016

Türk Cerrahi Derneği

Makale metnine

www.ulusalcerahidergisi.org

web sayfasından ulaşılabilir.

blood examinations, chest X-ray and thyroid function tests of the patient were normal. Total thyroidectomy was performed to the patient under general anesthesia. Nineteen millimeters diameter thyroid papillary carcinoma was detected in histopathological examination (capsule invasion and lenfovascular invasion were negative, without extrathyroidal spread).

Post-operative thyroid stimulating hormone (TSH) levels of the patient did not increase over 5.932 IU/mL. Retrosternal localized thyroid tissue was detected in postoperative thyroid scintigraphy. Cervical residual thyroid tissue was not observed in the control USG of the patient. A mass compatible with retrosternal, anterior mediastinal 3 x 3 cm sized ectopic thyroid tissue was detected in computed tomography (CT-scan) examination. Image of CT-scan is shown in Figure 1.

Median sternotomy (partial) was performed to the patient. Thyroid tissue on thymus with approximately 3 x 4 cm size was totally excised. Peroperative image of ectopic thyroid tissue is shown in Figure 2.

No complication related to sternotomy was observed in post-operative period. Nodular hyperplasia and chronic thyroiditis that showed oncocyctic change were detected in the histopathological examination of the excised ectopic thyroid tissue (size of ectopic thyroid tissue; 3.5 x 2.5 x 2.5 cm).

Residual thyroid tissue was not observed after surgical treatment in thyroid scintigraphy. 100 mCi dose of radioactive iodine (RAI) was administered in postoperative period. Thyroid scintigraphy of the patient taken following the surgical treatment is shown in Figure 3.

In the follow up of the patient, no problems were observed after RAI treatment.

DISCUSSION

Substernal goiter is the extension of thyroid gland in the mediastinum. If the thyroid tissue extends towards mediastinum it is defined as secondary and If there is ectopic thyroid gland in the mediastinum it is defined as primary. Primary substernal goiter constitutes 1% of all substernal goiters. Primary and secondary substernal goiters are fed respectively by mediastinal vessels and the vessels in the neck (5). Therefore, for the patients to be operated for substernal goiter, the differentiation of primary and secondary is clinically important. Ectopic thyroid tissue: anatomical, clinical, and surgical implications of a rare entity. In the literature there are very few cases related to mediastinal thyroid tissue detected after thyroidectomy, except the ones reported by Sahbaz et al. (6), Calò et al. (4) and Casadei et al. (7). Therefore, no incidence was reported in the literature regarding mediastinal thyroid tissue detected after thyroidectomy. However, retrosternal goiter incidence rates range between 0.2% and 45% of all goiters, depending on the definition used. About 20-40% of retrosternal goiters are symptomatic (6). Respiratory symptoms and rarely dysphagia or vena cava superior syndrome may be seen in some cases (2). No symptoms associated with retrosternal ectopic thyroid tissue were present in the patient in this case report. Retrosternal ectopic thyroid tissue was determined when there was no increase in TSH level after total thyroidectomy and retrosternal activity retention was monitored in thyroid scintigraphy.

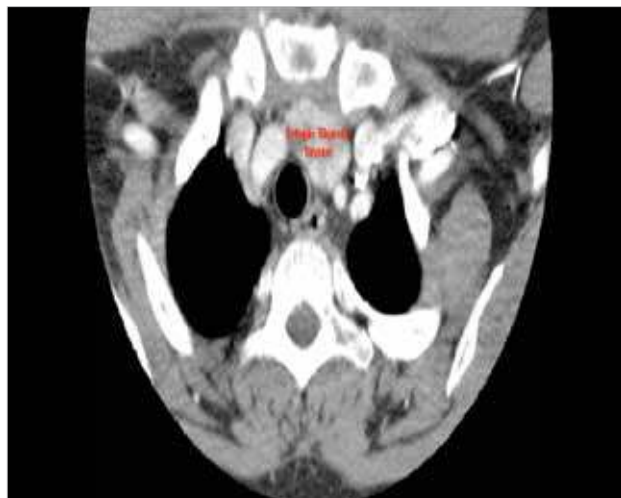

Figure 1. Image of CT-scan
CT: computed tomography

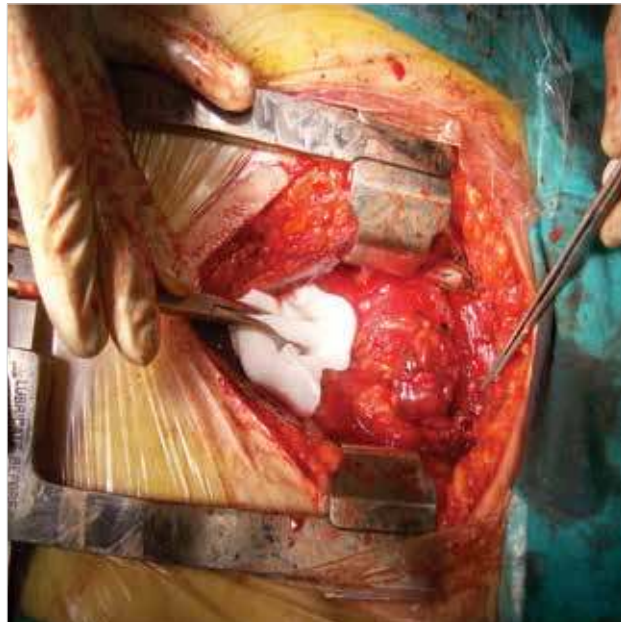


Figure 2. Thyroid tissue on thymus with approximately 3 x 4 cm size

Chest X-ray, CT-scan and magnetic resonance imaging (MRI) examination are beneficial in preoperative evaluation of patients thought to have retrosternal thyroid tissue (2). Tracheal compression and deviation findings were not detected in pre-operative chest X-ray of the patient in this case report. A mass compatible with 3 x 3 cm size thyroid tissue in anterior mediastinal region was detected in CT-scan of the patient.

According to American Thyroid Association (ATA) Guideline; 'For patients with thyroid cancer >1 cm, the initial surgical procedure should be a near-total or total thyroidectomy unless there are contraindications to this surgery. Thyroid lobectomy alone may be sufficient treatment for small (<1 cm), low-risk, unifocal, intrathyroidal papillary carcinomas in the absence of prior head and neck irradiation or radiologically or clinically involved cervical nodal metastases. Recommendation 26. Recommendation rating: A.' (8). In mediastinal thyroid tumors, surgery is usually performed in the presence of mass effect (2). We also preferred surgical treatment in our patient




Figure 3. Residual thyroid tissue was not observed after RAI treatment in thyroid scintigraphy
RAI: radioactive iodine

because we determined retrosternal ectopic thyroid tissue in the postoperative scintigraphy which is performed due to the histopathological diagnosis of papillary carcinoma after total thyroidectomy. Surgical management of retrosternal goiter is dependent on the experience of the surgeon (9). Batori et al. (9) reported that cervical approach is the only surgical method used in retrosternal goiter. However, thoracotomy or sternotomy is usually needed for surgical excision of mediastinal thyroid tissue (2). Surgical treatment for forgotten goiter, when performed in specialized centers, is associated with low morbidity (6). In this patient, ectopic thyroid tissue was excised through median sternotomy. Complication rates for median sternotomy range from 0.5% to 5%. This complications are presternal cellulitis and abscess, sternal osteomyelitis and dehiscence, or retrosternal mediastinitis, hematoma and abscess (10). No complication related to sternotomy was observed in postoperative period in this patient.

Primary thyroid carcinomas occurring from ectopic thyroid tissue are rare and have been reported to arise from thyroglossal cysts with thyroid tissue, lingual thyroid, lateral aberrant thyroid tissue, mediastinal and struma ovarii. Most tumors in the ectopic locations have been papillary carcinomas, mixed follicular and papillary carcinomas or Hurthle cell tumors (2). Papillary carcinoma was detected in cervical thyroid tissue in the patient presented in this case report. No malignancy was observed in histopathological examination of the ectopic thyroid tissue. Differential diagnosis of substernal goiter should be considered for thymomas, lymphomas, pleuropericardial cysts, neurogenic tumors, dermoid cysts, and metastatic lymph node deposits of well-differentiated thyroid carcinoma (1, 11).

CONCLUSION

Retrosternal ectopic thyroid tissue detected after total thyroidectomy is a rarely encountered condition. Therefore, retrosternal ectopic thyroid tissue existence should be definitely kept in mind in patients with no increase in TSH level after total thyroidectomy.

Informed Consent: Written informed consent was obtained from patient who participated in this case.

Peer-review: Externally peer-reviewed.

Author Contributions: Concept - U.K., S.Kesici; Design - U.K., S.Kesici; Supervision - S.Kesici., İ.M.; Funding - U.K., S.Kesici., Ö.K., A.Y., E.M.; Materials - U.K., Savaş.K., Ö.K.; Data Collection and/or Processing - U.K., S.Kesici., A.Y., Ö.K., İ.M., E.M.; Analysis and/or Interpretation - U.K., S.Kesici., Sevd.K., Savaş.K., S.Kesici., E.M.; Literature Review - U.K., Savaş.K., S.Kesici., Sevd.K.; Writer - U.K.; Critical Review - Savaş.K., Sevd.K., S.Kesici., İ.M., E.M., A.Y.

Acknowledgements: We thank Sezgin Zeren for English editing.

Conflict of Interest: No conflict of interest was declared by the authors.

Financial Disclosure: The authors declared that this study has received no financial support.

Hasta Onamı: Yazılı hasta onamı bu olguya katılan hastadan alınmıştır.

Hakem değerlendirmesi: Dış bağımsız.

Yazar Katkıları: Fikir - U.K., S.Kesici; Tasarım - U.K., S.Kesici; Denetleme - S.Kesici., İ.M.; Kaynaklar - U.K., S.Kesici., Ö.K., A.Y., E.M.; Malzemeler - U.K., Savaş.K., Ö.K.; Veri toplanması ve/veya işlemesi - U.K., S.Kesici., A.Y., Ö.K., İ.M., E.M.; Analiz ve/veya yorum - U.K., S.Kesici., Sevd.K., Savaş.K., S.Kesici., E.M.; Literatür taraması - U.K., Savaş.K., S.Kesici., Sevd.K.; Yazıyı yazan - U.K.; Eleştirel inceleme - Savaş.K., Sevd.K., S.Kesici., İ.M., E.M., A.Y.

Teşekkür: İngilizce düzeltme için Sezgin Zeren'e teşekkür ederiz.

Çıkar Çatışması: Yazarlar çıkar çatışması bildirmemişlerdir.

Finansal Destek: Yazarlar bu çalışma için finansal destek almadıklarını beyan etmişlerdir.

REFERENCES

1. Mace AD, Taghi A, Khalil S, Sandison A. Ectopic sequestered thyroid tissue: An unusual cause of a mediastinal mass. *ISRN Surgery* 2011; 2011: 313626. [\[CrossRef\]](#)
2. Shah BC, Ravichand CS, Juluri S, Agarwal A, Pramesh CS, Mistry RC. Ectopic thyroid cancer. *Ann Thorac Cardiovasc Surg* 2007; 13: 122-124.
3. Radkowski D, Arnold J, Healy GB, McGill T, Treves ST, Paltiel H, et al. Thyroglossal duct remnants. *Arch Otolaryngol Head Neck Surg* 1991; 117: 1378-1381. [\[CrossRef\]](#)
4. Calò PG, Tatti A, Medas F, Petruzzo P, Pisano G, Nicolosi A. Forgotten goiter. Our experience and a review of the literature. *Ann Ital Chir* 2012; 83: 487-490.
5. Yorgancılar E, Yildirim M, Gun R, Bakir S, Topcu I. Management to substernal goiter. *KBB-Forum* 2011; 10: 40-45.
6. Sahbaz A, Aksakal N, Ozcinar B, Onuray F, Caglayan K, Erbil Y. The "forgotten" goiter after total thyroidectomy. *Int J Surg Case Rep* 2013; 4: 269-271. [\[CrossRef\]](#)
7. Casadei R, Perenze B, Calculli L, Minni F, Conti A, Marrano D. "Forgotten" goiter: clinical case and review of the literature. *Chir Ital* 2002; 54: 855-860.
8. Cooper DS, Doherty GM, Haugen BR, Kloos RT, Lee SL, Mandel SJ. Revised American Thyroid Association management guidelines for patients with thyroid nodules and differentiated thyroid cancer. *Thyroid* 2009; 19: 1167-1214. [\[CrossRef\]](#)

9. Batori M, Chatelou E, Straniero A. Surgical treatment of retrosternal goiter. *Eur Rev Med Pharmacol Sci* 2007; 11: 265-268.
10. Li AE, Fishman EK. Evaluation of complications after sternotomy using single- and multidetector CT with three-dimensional volume rendering. *AJR Am J Roentgenol* 2003; 181: 1065-1070. [\[CrossRef\]](#)
11. Ioannidis O, Dalampini E, Chatzopoulos S, Kotronis A, Paraskevas G, Konstantara A, et al. Acute respiratory failure caused by neglected giant substernal nontoxic goiter. *Arq Bras Endocrinol Metabol* 2011; 55: 229-232. [\[CrossRef\]](#)