

Current options in umbilical hernia repair in adult patients

Erişkinlerdeki göbek fıtıklarında cerrahi tedavi seçenekleri

Hakan Kulaçoğlu

ABSTRACT

Umbilical hernia is a rather common surgical problem. Elective repair after diagnosis is advised. Suture repairs have high recurrence rates; therefore, mesh reinforcement is recommended. Mesh can be placed through either an open or laparoscopic approach with good clinical results. Standard polypropylene mesh is suitable for the open onlay technique; however, composite meshes are required for laparoscopic repairs. Large seromas and surgical site infection are rather common complications that may result in recurrence. Obesity, ascites, and excessive weight gain following repair are obviously potential risk factors. Moreover, smoking may create a risk for recurrence.

Keywords: umbilical hernia, hernia repair, mesh, laparoscopy

ÖZET

Göbek fıtığı nispeten sık rastlanan bir cerrahi sorundur. Tanı konduktan sonra elektif şartlarda ameliyat önerilmektedir. Dikişle onarım sonrası nüks oranı yüksek olduğu için yama onarımları önerilmektedir. Açık ya da laparoskopik teknikte yerleştirilen yamalar ile iyi sonuçlar alınmaktadır. Açık onarımda standart polipropilen yama yeterlikten laparoskopik onarımlarda kompozit yamalara gerek duyulmaktadır. Büyük seroma ve cerrahi alan enfeksiyonu nispeten sık rastlanabilen ve nüks neden olabilen komplikasyonlardır. Obezite, asit ve ameliyat sonrasında aşırı kilo artışı da nüks için risk faktörleridir. Sigara kullananlarda da nüks riski artmaktadır.

Anahtar Kelimeler: Göbek fıtığı, fıtık onarımı, yama, laparoskopi

INTRODUCTION

Umbilical hernia is a rather common surgical problem. Approximately 10% of all primary hernias comprise umbilical and epigastric hernias (1). Approximately 175,000 umbilical hernia repairs are annually performed in the US (2). It has been reported that the share of umbilical and paraumbilical hernia repairs among all repairs for abdominal wall hernias increased from 5% to 14% in UK in the last 25 years (3). A similar rise has been reported in a recent multicenter study from Turkey (4).

In general, umbilical hernias are more common in women than men; however, there are series in which male patients are more frequent (5). Typically, a lump is observed around the umbilicus. Pain is the most common indication to visit a physician and undergo a repair (6). Recurrence may develop even in cases where a prosthetic mesh is used. Recurrent umbilical hernias often tend to enlarge faster than primary ones and may behave as incisional hernias.

An umbilical hernia has a tendency to be associated with high morbidity and mortality in comparison with inguinal hernia because of the higher risk of incarceration and strangulation that require an emergency repair. Although the number of articles with the title word "umbilical hernia" increased 2.6-fold between the periods 1991–2000 and 2001–2010, there still appears to be a certain discrepancy between its importance and the attention it has received in the literature (7). In this paper, the nature of the umbilical hernias is reviewed, and the current options for their surgical repair are discussed.

Anatomic Description

Many hernias in the umbilical region occur above or below the umbilicus through a weak place at the linea alba, rather than directly through the umbilicus itself, and the natural history and treatment do not differ for these hernias. The European Hernia Society classification (8) for primary abdominal wall hernias defines the midline hernias from 3 cm above to 3 cm below the umbilicus as umbilical hernia (Figure 1).

The borders of the umbilical canal are the umbilical fascia posteriorly, the linea alba anteriorly and medial edges of the two rectus sheaths on two sides. Herniation happens due to increasing intra-abdominal pressure. Predisposing factors include obesity, multiple pregnancies, ascites, and abdominal tumors (9). The content of the hernia sac may be preperitoneal fat tissue, omentum, and small intestine in the majority; a combination of those can take part. Large intestines are very rarely involved (10). The neck of the umbilical hernia is usually narrow compared with the size of the herniated mass, hence, strangulation is common. Therefore, an elective repair after diagnosis is advised.

Anesthesia

All three types of anesthesia (local, general, and spinal) are suitable in most cases. The patient and surgeon should make a decision regarding the type of anesthesia to be used before surgery. Local an-

Clinic of General Surgery, Dışkapı Yıldırım Beyazıt Training and Research Hospital, Ankara, Turkey

Address for Correspondence

Yazışma Adresi

Hakan Kulaçoğlu

Dışkapı Yıldırım Beyazıt Eğitim ve Araştırma Hastanesi, Genel Cerrahi Kliniği, Ankara, Türkiye
Phone: +90 312 596 23 70
e-mail: hakankulaocoglu@hotmail.com

Received / Geliş Tarihi: 28.10.2014
Accepted / Kabul Tarihi: 07.12.2014

©Copyright 2015
by Turkish Surgical Association
Available online at
www.uluscerrahidergisi.org

©Telif Hakkı 2015
Türk Cerrahi Derneği
Makale metnine
www.uluscerrahidergisi.org
web sayfasından ulaşılabilir.

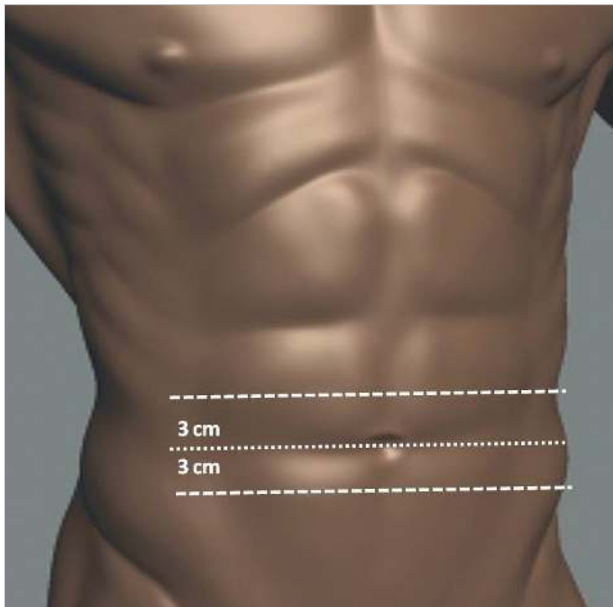


Figure 1. Abdominal wall hernias from 3 cm above to 3 cm below the umbilicus are defined as umbilical hernia according to the European Hernia Society Classification (8)

esthesia often provides maximum comfort for patients when it is accurately performed in open repairs. Some centers routinely use local anesthesia (5, 11, 12). However, inexperience with the local anesthetic technique may cause discomfort to patients with an increased recurrence rate. Local anesthesia may also be challenging if the patient is obese and hernia is large and/or recurrent (13). In patients with ASA I or II scores and who have one of the specific difficulties above, the surgeon should better choose general anesthesia to feel more secure because the quality of repair is the most important outcome measure.

Laparoscopic ventral hernia repair generally requires general anesthesia with endotracheal intubation. Furthermore, it can be feasible under spinal anesthesia with low-pressure CO₂ pneumoperitoneum (14).

Antibiotic Prophylaxis

Naturally, umbilicus is not a clean anatomical part of the body. The umbilical skin may not be cleaned of all bacteria even with the use of modern antiseptic solutions. Therefore, the surgical site infection can be more frequent following umbilical hernia repairs than that following inguinal hernia repairs. A 10% superficial wound infection rate is not surprising even after routine prophylactic antibiotic use. A recent study reported a 19% infection rate following open umbilical hernia repair (15). Kulacoglu et al. (5) reported 3% wound infection rate with antibiotic prophylaxis with cefazolin sodium that is administered 30 min before skin incision.

Deysine (14) recommended topical gentamicin in addition to preoperative intravenous prophylaxis to lower the infection rates after hernia repairs. He reported no surgical site infections in hernia surgery after setting this prophylaxis combination for 24 consecutive years. Although gentamicin is most effective against gram-negative bacteria, it is also effective against staphylococci. Furthermore, it has been stated that gentamicin can demonstrate antimicrobial synergy with cefazolin for a more successful antibacterial effect (16).

Which Repair Technique?

There are mainly two repair options for umbilical hernias: suture and mesh. Simple primary suture repair can be used for small defects (<2–3 cm). The technique of overlapping abdominal wall fascia in a “vest-over-pants” manner was described by William Mayo (17) and remained the most renowned surgical technique for a long time. There are few clinical studies with Mayo technique in the literature (6, 12). High recurrence rates up to 28% have been reported (10).

Prosthetic materials are widely used today in the repair of all kind of abdominal hernias. Arroyo et al's (18) randomized clinical trial revealed that the recurrence rate was lower after mesh repair than that after suture repair (1% vs. 11%) in a 64-month mean postoperative follow-up. In a retrospective clinical series of 100 patients, the recurrence rates for the suture and mesh repair groups were 11.5 and 0%, respectively ($p=0.007$), with a similar results in the infection rates in favor of mesh repair (19). A systematic review and meta-analysis by Aslani and Brown (20) revealed that the use of mesh in umbilical hernia repair results in decreased recurrence and similar wound complication rates compared with tissue repair for primary umbilical hernias. However, many surgeons still make his/her decision on the basis of the size of the umbilical/paraumbilical defect. Dalenbäck (21) suggested a tailored repair and stated that suture-based methods for defects <2 cm can provide acceptable recurrence rates (6%) in long-term follow-up. A postal questionnaire study from Scotland revealed that surgeons preferred mesh repair for defects >5 cm, whereas similar preference rates for suture and mesh repairs were obtained for defects <2 cm (22).

Mesheres can be placed via both the open and laparoscopic approaches. Surgeons in general prefer the most familiar technique or comply with the patients' preferences. Open onlay mesh placement is the easiest technique; however, it requires subcutaneous dissection that may cause seroma or hematoma and eventually result in surgical site infection in some cases. Mesh can also be placed in a preperitoneal or sublay position (5, 11). This may require more surgical experience and skill but avoids extensive subcutaneous dissection and reduces seroma formation and possibly result in less recurrence. Onlay and sublay mesh placement can be done at the same time in complicated or recurrent cases to provide more reinforced repair. Some authors prefer leaving fascial margins without approximation; however, suture closure before onlay mesh or after preperitoneal mesh is recommended.

Furthermore, mesh plug repair was described for umbilical hernias. It can be performed with local anesthesia (23, 24). However, there is no controlled study to compare plug repair with other techniques. Besides plug repairs have the risk of migration and enterocutaneous fistula formation (25).

Laparoscopic umbilical hernia repair has been practiced since late 1990s (26, 27). Single-port repairs have also recently been reported (28). Laparoscopic technique is basically a mesh repair; however, laparoscopic primary suture repair without prosthetic material has also been experienced (29). In contrast, Banerjee et al. (30) compared the laparoscopic mesh placement without defect closure with laparoscopic suture and mesh in a clinical study and reported a slightly lower recurrence rate in the latter group, particularly for recurrent hernias.

Today the utilization of laparoscopy for umbilical hernia repair remains relatively low in the world. Laparoscopy is preferred in just a quarter of the cases (31). There are a few studies comparing open and laparoscopic repairs for umbilical hernias. Short-term outcomes from the American College of Surgeons National Surgery Quality Improvement Program recently revealed a potential decrease in the total and wound morbidity associated with laparoscopic repair for elective primary umbilical hernia repairs at the expense of longer operative time and length of hospital stay and increased respiratory and cardiac complications (32). In their multivariate model, after controlling for body mass index, gender, the American Society of Anesthesiologists class, and chronic obstructive pulmonary disease, the odds ratio for overall complications favored laparoscopic repair (OR=0.60; $p=0.01$). This difference was primarily driven by the reduced wound complication rate in laparoscopy group.

The Danish Hernia Database did not reveal significant differences in surgical or medical complication rates and in risk factors for a 30-day readmission between open and laparoscopic repairs (33). After open repair, independent risk factors for readmission were hernia defects >2 cm and tacked mesh fixation. After laparoscopic repair, female gender was the only independent risk factor for readmission.

Obese patients with umbilical hernia comprise a special group. A recent comparative study by Colon et al. (34) stated that laparoscopic umbilical hernia repair should be the preferred approach in obese patients. They found a significant increase in wound infection rate in the open mesh repair group when compared with the laparoscopic procedure (26% vs. 4%; $p<0.05$). They observed no hernia recurrence in the laparoscopic group, whereas the open group had 4% recurrence rate. In contrast, Kulacoglu et al. (5) demonstrated that obese patients also require more local anesthetic dose in open mesh repair.

A summary of current repair options for umbilical hernias are presented in Table 1.

Which Mesh?

Standard polypropylene mesh is the most frequently used prosthetic material particularly in open onlay repairs. Lightweight macroporous meshes are also in use. Both types of meshes are suitable for onlay and sublay placement. Reducing the density of polypropylene and creating a "light weight" mesh theoretically induces less foreign body response, results in improved abdominal wall compliance, causes less contraction or shrinkage of the mesh, and enables better tissue incorporation; however, their clinical advantages have not been clearly documented (35).

Newer bilayer prosthetic devices are designed for open intra-peritoneal inlay placement. They have two sides, one is polypropylene and the other side is a non-adherent material to face viscera. Two tails that are connected to the bilayer patch were sutured to fascial edges to avoid migration. Promising early results have been reported; however, these prostheses are expensive, and prospective randomized comparative studies have not yet been conducted (36-38). It has been reported that recurrence after this kind of bilayer prosthesis is higher in comparison with that after classical sublay mesh placements possibly because of the less controllable mesh deployment (39).

Table 1. A classification of current repair techniques for umbilical hernias

A. Prosthetic repairs
1. Open approach
a. Onlay mesh
b. Sublay/Preperitoneal mesh
c. Mesh plug
d. Bilayer prosthetic devices
2. Laparoscopic approach
a. Inlay mesh
b. Defect closure and mesh placement
B. Tissue-Suture repairs
1. Primary suture
2. Mayo repair

Bilayer polypropylene or partially reabsorbable meshes have also been used for umbilical hernias. They comprised one sublay and one overlay patch with a connector to eliminate migration. However, clinical outcomes after repairs with these devices have not been widely documented (40).

Choice of mesh appears to be more important for laparoscopic repairs (41). Composite meshes are preferred materials in most institutions to avoid the risk of visceral adhesion into the mesh (42, 43). There are numerous composite or dual-side meshes in the market; the results of the clinical and experimental studies testing their strength, durability, and safety regarding both recurrence and adhesion formation widely differ.

Although standard polypropylene mesh is easy to find and a much more economic choice, its use in laparoscopic ventral hernia repairs, including umbilical hernias, has certain risks. Sarela (44) stated that the financial-cost to clinical-benefit ratio for the use of expensive composite meshes is unquantified and is likely to remain as such because given the widespread acceptance of composite products, a randomized clinical comparison with simple polypropylene mesh is unlikely to occur. In selected circumstances, it may be acceptable to use a simple mesh if this can be completely excluded from bowel by interposition of omentum; however, a composite mesh should be considered as the current standard of care.

Factors Influencing Recurrence

Several factors have been responsible for recurrence after umbilical hernia repairs. However, few studies presented an independent factor after multivariate analysis.

Large seroma and surgical site infection are classical complications that may result in recurrence. Obesity and excessive weight gain following repair are obviously potential risk factors. The patient's BMI >30 kg/m² and defects >2 cm have been reported as possible factors for surgical failure (45). Moreover, smoking may create a risk for recurrence (46).

Ascites is a well-known risk factor for recurrence. Traditionally, umbilical hernia in patients with cirrhosis and with un-

controlled ascites was associated with significant mortality and morbidity and a significantly greater incidence of recurrence (47). However, recent reports for elective repair are more promising, and there is tendency to perform elective repair to avoid emergency surgery for complications associated with very high mortality and morbidity rates (48, 49). Early elective repair of umbilical hernias in patients with cirrhosis is advocated considering the hepatic reserve and patient's condition (50). Ascites control is the mainstay of post-operative management.

CONCLUSION

Mesh repairs are superior to non-mesh/tissue-suture repairs in umbilical hernia repairs. Open and laparoscopic techniques have almost similar efficacy. Local anesthesia is suitable for small umbilical hernias and patients with reasonable BMI. Antibiotic prophylaxis appears to provide low wound infection rate.

Peer-review: This manuscript was prepared by the invitation of the Editorial Board and its scientific evaluation was carried out by the Editorial Board.

Conflict of Interest: No conflict of interest was declared by the authors.

Financial Disclosure: The authors declared that this study has received no financial support.

Hakem Değerlendirmesi: Bu makale Editörler Kurulu'nun davetiyle hazırlandığından bilimsel değerlendirme Editörler Kurulu tarafından yapılmıştır.

Çıkar Çatışması: Yazarlar çıkar çatışması bildirmemişlerdir.

Finansal Destek: Yazarlar bu çalışma için finansal destek almadıklarını beyan etmişlerdir.

REFERENCES

1. Klinge U, Prescher A, Klosterhalfen B, Schumpelick V. Entstehung und Pathophysiologie der Bauchwanddefekte. *Chirurg* 1997; 68: 293-303. [CrossRef]
2. Rutkow IM. Epidemiologic, economic, and sociologic aspects of hernia surgery in the United States in the 1990s. *Surg Clin North Am* 1998; 78: 941-951. [CrossRef]
3. Dabbas N, Adams K, Pearson K, Royle G. Frequency of abdominal wall hernias: is classical teaching out of date? *JRSM Short Rep* 2001; 2: 5. [CrossRef]
4. Seker G, Kulacoglu H, Oztuna D, Topgül K, Akyol C, Cakmak A, et al. Changes in the frequencies of abdominal wall hernias and the preferences for their repair: a multicenter national study from Turkey. *Int Surg* 2014; 99: 534-542. [CrossRef]
5. Kulacoglu H, Yazicioglu D, Ozyaylali I. Prosthetic repair of umbilical hernias in adults with local anesthesia in a day-case setting: a comprehensive report from a specialized hernia center. *Hernia* 2012; 16: 163-170. [CrossRef]
6. Courtney CA, Lee AC, Wilson C, O'Dwyer PJ. Ventral hernia repair: a study of current practice. *Hernia* 2003; 7: 44-46.
7. Kulacoglu H, Oztuna D. Growth and trends in publications about abdominal wall hernias and the impact of a specific journal on herniology: a bibliometric analysis. *Hernia* 2011; 15: 615-628. [CrossRef]
8. Muysoms FE, Miserez M, Berrevoet F, Campanelli G, Champault GG, Chelala E, et al. Classification of primary and incisional abdominal wall hernias. *Hernia* 2009; 13: 407-414. [CrossRef]
9. Salameh JR. Primary and unusual abdominal wall hernias. *Surg Clin North Am* 2008; 88: 45-60. [CrossRef]
10. Martis JJ, Rajeshwara KV, Shridhar MK, Janardhanan D, Sudarshan S. Strangulated Richter's umbilical hernia - a case report. *Indian J Surg* 2011; 73: 455-457. [CrossRef]
11. Kurzer M, Belsham PA, Kark AE. Tension-free mesh repair of umbilical hernia as a day case using local anaesthesia. *Hernia* 2004; 8: 104-107. [CrossRef]
12. Menon VS, Brown TH. Umbilical hernia in adults: day case local anaesthetic repair. *J Postgrad Med* 2003; 49: 132-133.
13. Velasco M, Garcia-Urena MA, Hidalgo M, Vega V, Carnero FJ. Current concepts on adult umbilical hernia. *Hernia* 1999; 3: 233-239. [CrossRef]
14. Tzovaras G, Zacharoulis D, Georgopoulou S, Pratsas K, Stamatidou G, Hatzitheofilou C. Laparoscopic ventral hernia repair under spinal anesthesia: a feasibility study. *Am J Surg* 2008; 196: 191-194. [CrossRef]
15. Farrow B, Awad S, Berger DH, Albo D, Lee L, Subramanian A, et al. More than 150 consecutive open umbilical hernia repairs in a major veterans administration medical center. *Am J Surg* 2008; 196: 647-651. [CrossRef]
16. Deysine M. Infection control in a hernia clinic: 24 year results of aseptic and antiseptic measure implementation in 4,620 "clean cases". *Hernia* 2006; 10: 25-29. [CrossRef]
17. Mayo WJ. An operation for the radical cure of umbilical hernia. *Ann Surg* 1901; 34: 276-280. [CrossRef]
18. Arroyo A, García P, Pérez F, Andreu J, Candela F, Calpena R. Randomized clinical trial comparing suture and mesh repair of umbilical hernia in adults. *Br J Surg* 2001; 88: 1321-1323. [CrossRef]
19. Sanjay P, Reid TD, Davies EL, Arumugam PJ, Woodward A. Retrospective comparison of mesh and sutured repair for adult umbilical hernias. *Hernia* 2005; 9: 248-251. [CrossRef]
20. Aslani N, Brown CJ. Does mesh offer an advantage over tissue in the open repair of umbilical hernias? A systematic review and meta-analysis. *Hernia* 2010; 14: 455-462. [CrossRef]
21. Dalenbäck J, Andersson C, Ribokas D, Rimbäck G. Long-term follow-up after elective adult umbilical hernia repair: low recurrence rates also after non-mesh repairs. *Hernia* 2013; 17: 493-497. [CrossRef]
22. Witherspoon P, O'Dwyer PJ. Surgeon perspectives on options for ventral abdominal wall hernia repair: results of a postal questionnaire. *Hernia* 2005; 9: 259-262. [CrossRef]
23. Sinha SN, Keith T. Mesh plug repair for paraumbilical hernia. *Surgeon* 2004; 2: 99-102. [CrossRef]
24. Brancato G, Privitera A, Gandolfo L, Donati M, Caglià P. Plug-technique for umbilical hernia repair in the adult. *Minerva Chir* 2002; 57: 13-16.
25. Costa D, Tomás A, Lacueva J, de Asís Pérez F, Oliver I, Arroyo A, et al. Late enterocutaneous fistula as a complication after umbilical hernioplasty. *Hernia* 2004; 8: 271-272. [CrossRef]
26. Franklin ME, Dorman JP, Glass JL, Balli JE, Gonzalez JJ. Laparoscopic ventral and incisional hernia repair. *Surg Laparosc Endosc* 1998; 8: 294-299. [CrossRef]
27. Nguyen NT, Lee SL, Mayer KL, Furdul GL, Ho HS. Laparoscopic umbilical herniorrhaphy. *J Laparoendosc Adv Surg Tech A* 2000; 10: 151-153. [CrossRef]
28. Roberts KE, Panait L, Duffy AJ, Bell RL. Single-port laparoscopic umbilical hernia repair. *Surg Innov* 2010; 17: 256-260. [CrossRef]
29. Anadol AZ, Tezel E, Yilmaz U, Kurukahvecioglu O, Ersoy E. Laparoscopic primary repair of ventral hernias: early results of a new technique. *Surg Today* 2010; 40: 88-91. [CrossRef]
30. Banerjee A, Beck C, Narula VK, Linn J, Noria S, Zagol B, et al. Laparoscopic ventral hernia repair: does primary repair in addition to placement of mesh decrease recurrence? *Surg Endosc* 2012; 26: 1264-1268. [CrossRef]
31. Funk LM, Perry KA, Narula VK, Mikami DJ, Melvin WS. Current national practice patterns for inpatient management of ventral abdominal wall hernia in the United States. *Surg Endosc* 2013; 27: 4104-412. [CrossRef]
32. Cassie S, Okrainec A, Saleh F, Quereshey FS, Jackson TD. Laparoscopic versus open elective repair of primary umbilical hernias: short-term outcomes from the American College of Surgeons National Surgery Quality Improvement Program. *Surg Endosc* 2014; 28: 741-746. [CrossRef]
33. Helgstrand F, Jørgensen LN, Rosenberg J, Kehlet H, Bisgaard T. Nationwide prospective study on readmission after umbilical or epigastric hernia repair. *Hernia* 2013; 17: 487-492. [CrossRef]

34. Colon MJ, Kitamura R, Telem DA, Nguyen S, Divino CM. Laparoscopic umbilical hernia repair is the preferred approach in obese patients. *Am J Surg* 2013; 205: 231-236. [\[CrossRef\]](#)
35. Cobb WS, Kercher KW, Heniford BT. The argument for lightweight polypropylene mesh in hernia repair. *Surg Innov* 2005; 12: 63-69. [\[CrossRef\]](#)
36. Martin DF, Williams RF, Mulrooney T, Voeller GR. Ventralex mesh in umbilical/epigastric hernia repairs: clinical outcomes and complications. *Hernia* 2008; 12: 379-383. [\[CrossRef\]](#)
37. Vychnevskaya K, Mucci-Hennekinne S, Casa C, Brachet D, Meunier K, Briennon X, et al. Intraperitoneal mesh repair of small ventral abdominal wall hernias with a Ventralex hernia patch. *Dig Surg* 2010; 27: 433-435. [\[CrossRef\]](#)
38. Hadi HI, Maw A, Sarmah S, Kumar P. Intraperitoneal tension-free repair of small midline ventral abdominal wall hernias with a Ventralex hernia patch: initial experience in 51 patients. *Hernia* 2006; 10: 409-413. [\[CrossRef\]](#)
39. Berrevoet F, D'Hont F, Rogiers X, Troisi R, de Hemptinne B. Open intraperitoneal versus retromuscular mesh repair for umbilical hernias less than 3 cm diameter. *Am J Surg* 2011; 201: 85-90. [\[CrossRef\]](#)
40. Polat C, Dervisoglu A, Senyurek G, Bilgin M, Erzurumlu K, Ozkan K. Umbilical hernia repair with the prolene hernia system. *Am J Surg* 2005; 190: 61-64. [\[CrossRef\]](#)
41. Eriksen JR, Gögenur I, Rosenberg J. Choice of mesh for laparoscopic ventral hernia repair. *Hernia* 2007; 11: 481-492. [\[CrossRef\]](#)
42. Nardi MJ, Millo P, Brachet Contul R, Fabozzi M, Persico F, Roveroni M, et al. Laparoscopic incisional and ventral hernia repair (LIVHR) with PARIETEX™ Composite mesh. *Minim Invasive Ther Allied Technol* 2012; 21: 173-180. [\[CrossRef\]](#)
43. Tollens T, Struyve D, Aelvoet C, Vanrijkel JP. Introducing the Proceed Ventral Patch as a new device in surgical management of umbilical and small ventral hernias: preliminary results. *Surg Technol Int* 2010; 19: 99-103.
44. Sarela AI. Controversies in laparoscopic repair of incisional hernia. *J Minim Access Surg* 2006; 2: 7-11. [\[CrossRef\]](#)
45. Venclouskas L, Silanskaitė J, Kiudelis M. Umbilical hernia: factors indicative of recurrence. *Medicina (Kaunas)* 2008; 44: 855-859.
46. Bencini L, Sanchez LJ, Bernini M, Miranda E, Farsi M, Boffi B, et al. Predictors of recurrence after laparoscopic ventral hernia repair. *Surg Laparosc Endosc Percutan Tech* 2009; 19: 128-132. [\[CrossRef\]](#)
47. Leonetti JP, Aranha GV, Wilkinson WA, Stanley M, Greenlee HB. Umbilical herniorrhaphy in cirrhotic patients. *Arch Surg* 1984; 119: 442-445. [\[CrossRef\]](#)
48. Eker HH, van Ramshorst GH, de Goede B, Tilanus HW, Metselaar HJ, de Man RA, et al. A prospective study on elective umbilical hernia repair in patients with liver cirrhosis and ascites. *Surgery* 2011; 150: 542-546. [\[CrossRef\]](#)
49. Dokmak S, Aussilhou B, Belghiti J. Umbilical hernias and cirrhosis. *J Visc Surg* 2012; 149(Suppl 5): e32-39. [\[CrossRef\]](#)
50. Choi SB, Hong KD, Lee JS, Han HJ, Kim WB, Song TJ, et al. Management of umbilical hernia complicated with liver cirrhosis: an advocate of early and elective herniorrhaphy. *Dig Liver Dis* 2011; 43: 991-995. [\[CrossRef\]](#)