

Adjuvant versus neoadjuvant chemoradiotherapy in distal rectal cancer: Comparison of two decades in a single center

Baha Zengel¹, Adam Uslu¹, Zehra Adıbelli², Halit Yetiş¹, Fevzi Cengiz¹, Ahmet Aykas¹, Cenk Şimşek¹, Göksever Akpınar¹, Nuket Eliyatkin³, Ali Duran¹

ABSTRACT

Objective: Standard surgery alone was not able to decrease local recurrence (LR) rate below 20% in rectal cancer treatment. Thus, many centers administered neoadjuvant radiotherapy (preopRTx) with or without concomitant chemotherapy for the prevention of LR. In this study, the results of 164 consecutive patients with mid- and distal rectal cancer who received surgery and adjuvant chemoradiotherapy (Group A) or neoadjuvant chemoradiotherapy (Group NA) followed by surgery are presented.

Material and Methods: The staging system used in this study is that of the American Joint Committee on Cancer (AJCC), also known as the TNM system. Eligible patients were required to have radiologically assessed stage 1 (only T2N0M0) to stage 3C (T4bN1-2M0) tumor with pathologically confirmed R0 resection. The surgical method was total mesorectal excision (TME). Radiotherapy was applied with daily 180 cGy fractions for 28 consecutive days. Chemotherapy comprised 5-fluorouracil (450 mg/m²/d) and leucovorin (20 mg/m²/d) bolus at days 1–5 and 29–33.

Results: Nine patients (13%) in Group NA achieved pathologic complete response (pCR). In Group NA and Group A, locoregional recurrence (LRR) rates were 6.7% and 30.8%, ($p < 0.001$), the mean LR-free survival was 190.0±7.3 months and 148.0±11.7 months ($p = 0.002$) and the mean overall survival (OS) was 119.2±15.3 months and 103.0±9.4 months ($p = 0.23$), respectively. A significant difference with regard to LR has been obtained with a statistical power of 0.92. Secondary outcome measures (DFS and OS) have not been met.

Conclusion: Neoadjuvant chemoradiotherapy with TME is an efficient treatment protocol, particularly for the treatment of magnetic resonance imaging-staged 2A to 3C patients with two or three distal rectal adenocarcinomas. Given that a considerable proportion of patients with cT2N0M0 would develop pCR, this method of treatment can be considered for further studies.

Keywords: Rectal cancer, recurrence, neoadjuvant chemoradiotherapy

INTRODUCTION

Local recurrence (LR) and regional recurrence (RR) after the treatment of rectal cancer is an extremely serious and devastating consequence and the success rates of corrective treatment are quite low (1). The incidence of LR ranges widely from 10% to 40% and is directly correlated with the extension of tumor through the rectal wall and involvement of adjacent lymph nodes (2, 3). Although a worldwide accepted method of surgery has been implemented in many centers over the last two decades, the LR rate remained >20% in all surgery-alone groups of previous prospective study reports (4-6). Similar result had been reproduced by our group in 82 consecutive patients with mid- and distal rectal adenocarcinomas having specific histology. The treatment modality was surgery and adjuvant radiotherapy when indicated; patients in Stage B1-B2 had a local failure rate of 15% compared with 31% of patients in stage C1-C2 (7).

The most important treatment for the prevention of LR and RR is so far the neoadjuvant radiotherapy (preop RTx) with or without concomitant chemotherapy. The rationale in this approach is based on more efficient destruction of the normally oxygenated tumor cells compared to those with impaired perfusion after pelvic surgery; thus, it is hypothesized that this method will eradicate micrometastasis, shrink tumor burden, and downstage the tumor (8).

MATERIAL AND METHODS

In this study, the results of 164 consecutive patients with mid- and distal rectal cancer who have been treated with different methodologies at two different periods are presented. In the first period, i.e., between 1993 and 2003, 90 patients received surgery and adjuvant chemoradiotherapy (Group A); in the second period, i.e., between 2004 and 2013, 74 patients received neoadjuvant chemoradiotherapy (Group NA) followed by surgery.

¹Clinic of General Surgery, İzmir Bozyaka Training and Research Hospital, İzmir, Turkey

²Clinic of Radiology, İzmir Bozyaka Training and Research Hospital, İzmir, Turkey

³Clinic of Pathology, İzmir Bozyaka Training and Research Hospital, İzmir, Turkey

⁴Department of Public Health, Ege University Faculty of Medicine, İzmir, Turkey

Address for Correspondence

Baha Zengel

e-mail: bahazengel@gmail.com

Received: 29.11.2014

Accepted: 06.02.2015

©Copyright 2015

by Turkish Surgical Association

Available online at
www.uluscerrahidergisi.org

Informed consent was obtained from all patients. The eligible patients were required to have the following conditions:

1. Radiologically assessed TNM stage 1 (T2N0M0) to stage 3C tumor,
2. Adenocarcinoma including all histologic subtypes,
3. Pathologically confirmed R0 resection,
4. No history of previous cancer, except skin malignancies (squamous or basal cell carcinoma).

All patients in the Group NA underwent preoperative chemoradiation and total mesorectal excision (TME). The primary and secondary outcome measures were locoregional recurrence (LRR) and overall survival (OS). Preoperative assessment included complete blood count, blood chemistry, tumor markers (CEA; CA 19-9), and comorbid disease evaluation. All patients underwent total colonoscopy to exclude synchronous tumor. Computed tomography (CT) scanning of the whole abdomen and thorax were performed to rule out pulmonary and liver metastases. Preoperative radiological staging was based on contrast-enhanced thin-slice (5 mm) CT (CE-CT) in the first period (Group A) and contrast-enhanced magnetic resonance imaging (CE-MRI) of the pelvis in the second period (Group NA). All of the patients underwent elective surgery with curative intent and had undergone one-stage resection. The patients who underwent palliative or emergency surgery were not included.

In the Group A, all patients with T4N0M0 and advanced tumors and those with peritumoral lymphovascular or perineural invasion received adjuvant radiotherapy. Radiotherapy was applied as four-field radiation with daily 180 cGy fractions for 28 consecutive days. A double boost with a cumulative dose of 1080 cGy was administered to the tumor bed and to adjacent lymphovascular structures. Concurrent chemotherapy with 5-FU (450 mg/m²/d) and leucovorin (20 mg/m²/d) boluses at days 1–5 and 29–33 was administered, unless otherwise indicated. The same regimen was performed for additional 4–6 courses following neoadjuvant chemoradiotherapy.

In the Group NA, all patients in the clinical stages 1b, 2 (cT2–4, N0, M0), and 3 (cT1–4, N+, M0) are concerned as candidates for preoperative radiotherapy±chemotherapy. In this group, radiotherapy consisted of 45 or 50 Gy delivered using a four-field technique in 1.8- or 2-Gy fractions up to five times per week. This dose was restricted to posterior pelvic organs including the complete rectum and mesorectum below the peritoneal deflection but the external and common iliac nodes were protected. The same chemotherapy regimen mentioned above was administered and two or three courses were administered before surgery. Irradiation treatment for both groups was administered by the same center.

All of the patients underwent surgery between 5 and 6 weeks after the completion of radiotherapy.

The method of resection in both periods was TME. Principally, tumors located at a distance of ≥6 cm from the anal verge were treated with low anterior resection (LAR) and those located at a distance of <6 cm mostly underwent the Miles procedure.

Quality Control in Surgery

The surgical technique in this study is described extensively in the earlier publication (7). The surgical team actively involved in the kidney and liver transplantation since 1990 have the expertise and knowledge in cadaver operations and pelvic anatomy. Besides, a majority of cases were recorded during the operation and the pathologic specimen was photographed to verify the integrity of mesorectal structures (Figure 1).

Pathology

All specimens were sent to the pathology laboratory in 10% buffered neutral formalin solution. Tumor blocks were cut transversely into 5-mm sections, including full-thickness tissue of the rectum and mesentery. Hematoxylin–eosin-stained paraffin slides of 4-μm thickness were prepared. The pathological examination of the resection specimen included the description of the nature, subtype, degree of differentiation of the primary tumor with the assessment of the invasion depth, proximal-distal resection margin (PRM-DRM) and circumferential resection margin (CRM), positive lymph nodes, angioinvasion, perineural invasion, and presence of satellite tumor. Our study protocol mandated R0 resection; therefore, the mesorectum was complete in all specimens and there were no mesorectal defects deeper than 5 mm in the periphery of the primary tumor.

Additionally, pathologically assessed R0 resection was defined as follows: no residual tumor cells in non-peritonealized soft tissue of the rectum, lymph node, or vein at a distance of ≤1 mm from CRM and longitudinal resection margin.

Statistical Analysis

The difference between the demographic features, surgical interventions, and morbidities of the two groups were analyzed by independent sample t-test. Pearson's chi-square analysis was used to detect the differences between survival outcomes. The survival analysis was performed on the basis of treatment; thus, it excluded nine patients in the Group A who were lost to follow-up. For all survival analyses, Kaplan–Meier survival functions were computed with the Cox proportional hazards model. A p value of <0.05 was considered to be statistically significant.

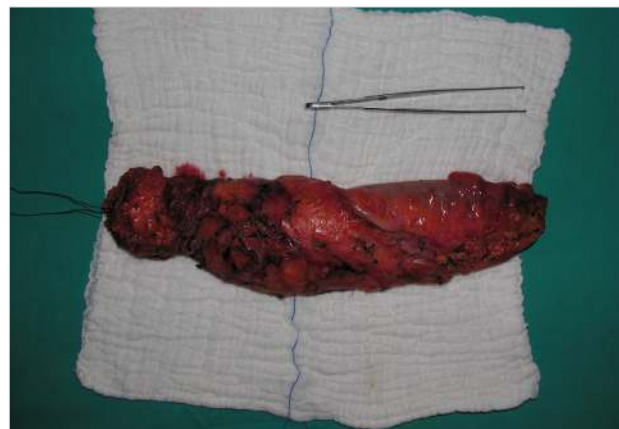


Figure 1. Total mesorectal excision specimen

RESULTS

The follow-up was complete in all patients in the Group NA. However, we could not follow up nine patients in the Group A over the last 3 years; hence, although they had an uneventful course during their last follow-up, we excluded them from the study. Thus, we performed on-treatment analysis. The mean follow-up period was 53.2±38 months and 69.8±7.8 months in the Groups NA and A, respectively ($p < 0.001$). Pathological stage of the tumors in the Group A was not different when compared with the pretreatment MRI stage of tumors in the Group NA ($p = 0.11$) (Table 1). There was no difference between the groups with regard to age, sex distribution, and tumor localization. However, moderately differentiated adenocarcinoma (MDA) subtype was more frequent in the Group NA ($p = 0.002$) and adenocarcinoma with mucinous differentiation was more common in the Group A ($p = 0.001$). As expected, the pTNM stage of the specimens of the Group NA was significantly lower than that of the Group A.

Among 74 patients in the Group NA, 54 received up to 4–6 cycles of adjuvant chemotherapy. Five patients did not receive chemotherapy either due to poor performance or gastrointestinal and hematological side-effects, which were unresponsive to a dose reduction of 25%. The oncology council recommended clinical follow-up for the remaining 15 patients, of whom 6 had pathologic complete response (pCR), six had tumor regression to stage 1, and 3 had tumor regression to stage 2A.

Approximately 13% of the patients (nine patients) in the Group NA achieved pCR. MRI-based clinical stage was cT2N0M0 in four, cT3N0M0 in two, and cT3-T4aN2bM0 in three patients. The histological subtype of these tumors was well or MDAs in common. None of the patients had LRR until the last follow-up. However, one patient with cT4aN2bM0 has been admitted with liver metastasis at 24 months after surgery and is already receiving second-line adjuvant chemotherapy (Table 2). No difference was observed in terms of the type of surgery and related complications between the groups (Table 3).

Locoregional Recurrence

In the Group NA, LRR occurred within 5–25 months after surgery in 5 of 74 patients (6.7%). In the Group A, 25 of 81 patients (30.8%) developed LRR within 6–108 months ($p < 0.001$). The statistical power is 0.92 (Table 3). The mean LRR-free survival was 190.0±7.3 months in the NA and 148.0±11.7 months in the Group A (Log Rank Mantel–Cox; $p = 0.002$) (Figure 2).

Disease-Free Survival Analysis

Nineteen patients in the Group NA (25.7%) and 41 of 81 patients (50.6%) in the Group A had either locoregional or distant organ metastasis during the last follow-up (Table 4). Time to first LRR and time to distant metastasis ranged between 6 and 67 months and between 6 and 195 months after the operation, respectively. Median DFS was 110±16.1 months in the Group NA and 113±25.4 months in the Group A (Figure 3). None of the patients developed distant metastasis while receiving neoadjuvant chemoradiotherapy or during the waiting phase of 6 weeks before curative surgery. One patient in

Table 1. Pretreatment MRI-staging in Group NA versus pathological stage of tumors in Group A

	Adjuvant group (pathological staging after surgery) (n, %)	Neoadjuvant group (pretreatment MRI staging) (n, %)	p
Stage 1	8 (9.9)	0 (0)	0.108
Stage 2A	28 (34.6)	24 (32.4)	
Stage 2B	6 (7.4)	3 (4)	
Stage 3A	2 (2.5)	1 (1.4)	
Stage 3B	24 (29.6)	33 (44.6)	
Stage 3C	13 (16)	13 (17.6)	
MRI: magnetic resonance imaging			

Table 2. Demographic patterns

Group	Adjuvant	Neoadjuvant	p
Age (Mean±SD)	56.2±11.9	62±10.6	0.083
Sex (n, %)			
Female	27 (33.3)	33 (44.6)	0.187
Male	54 (66.7)	41 (55.4)	
Tumor localization (cm) (Mean±SD)	6.21±2.43	6.45±2.74	0.448
Histologic subtype (n, %)			
Well differentiated	8 (9.8)	4 (5.4)	0.015
Moderately differentiated	56 (69.1)	66 (89.2)	
Poorly differentiated	3 (3.7)	3 (4.1)	
Mucinous	13 (16)	1 (1.3)	
Signet-cell carcinoma	1 (1.4)	0 (0)	
Histopathologic stage (n, %)			
Stage 0	0 (0)	9 (12.7)	<0.001
Stage 1	8 (9.9)	19 (26.8)	
Stage 2A	28 (34.6)	22 (31)	
Stage 2B	6 (7.4)	2 (2.8)	
Stage 3A	2 (2.5)	2 (2.8)	
Stage 3B	24 (29.6)	16 (22.5)	
Stage 3C	13 (16.0)	1 (1.4)	
SD: standard deviation			

the Group NA developed metachronous colon tumor during the follow-up.

Overall Survival Analysis

During the last follow-up, 56 patients in the Group NA (69%) and 25 patients in the Group A (31%) were alive. Fifty-four patients in the Group NA and all patients in the Group A had no evidence of pelvic or distant organ metastasis. The mean and median OS were 119.2±15.3 vs. 103.0±9.4 months and 119.0±24.7 vs. 69.0±24.0 months, respectively (Log Rank Mantel–Cox; $p = 0.23$) (Figure 4).

Table 3. Surgery and morbidity			
Group	Adjuvant	Neoadjuvant	p
Operation (n, %)			
Miles	51 (63)	39 (52.7)	0.281
LAR	30 (37)	35 (47.3)	
Technique of anastomosis (n, %)			
Colostomy	51 (63)	39 (52.7)	0.251
Manual	10 (12.3)	10 (13.5)	
Stapler	20 (24.7)	25 (33.8)	
Postoperative complication (n, %)			
Absent	68 (84)	59 (79.7)	0.406
Present	13 (16)	15 (20.3)	
Type of complication (n, %)			
Anastomotic leak	6 (7.3)	6 (8.1)	0.392
Colostomy necrosis	0 (0)	2 (2.7)	
Rectovaginal fistula	0 (0)	3 (4.0)	
Wound infection	2 (2.5)	1 (1.4)	
Eventration	2 (2.5)	1 (1.4)	
Mechanical bowel obstruction	2 (2.5)	2 (2.7)	
Ureteral damage	1 (1.2)	0 (0)	

LAR: low-anterior resection

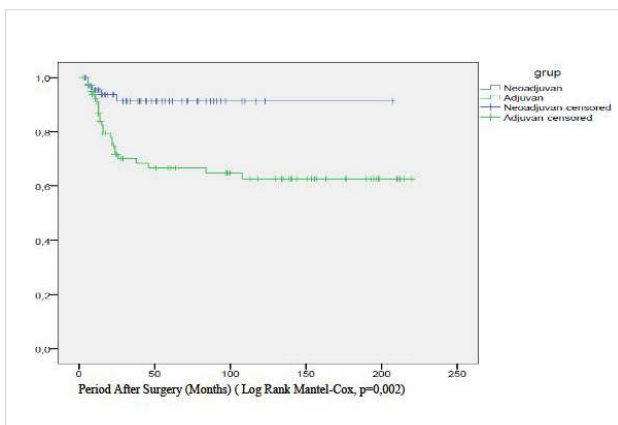


Figure 2. Locoregional recurrence-free survival; Kaplan-Meier survival plot

In this study, a significant difference between the two groups in terms of LR (the primary outcome measure) has been obtained with a statistical power of 0.91. The rate of adherence to preoperative chemotherapy was 86.5% (64 patients) and to postoperative chemotherapy was 96% (78 patients).

DISCUSSION

This is a single-center clinical trial in which all patients were carefully monitored and the treatment protocol in two consecutive periods was strictly followed with no violation. Moreover, although a standard surgery with the pathological assessment of quality have been implemented throughout the study, the prerequisite of R0

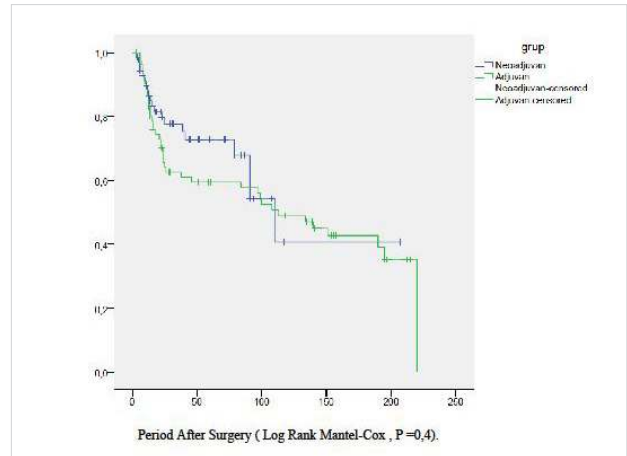


Figure 3. Disease-free survival; Kaplan-Meier survival plot

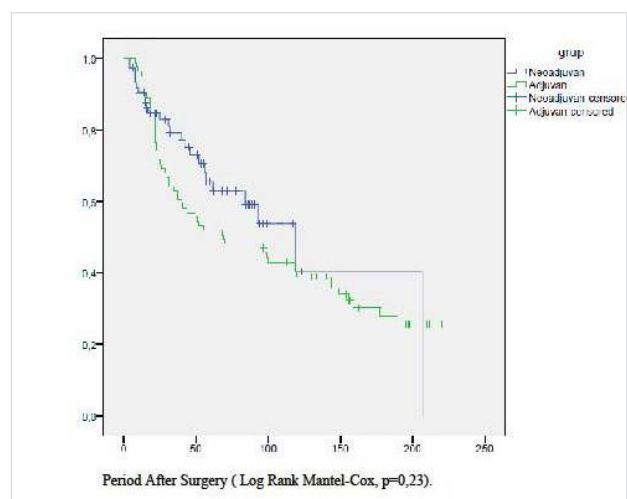


Figure 4. Overall survival; Kaplan-Meier survival plot

resection for final analysis eliminated inter-individual variability in surgery and eliminated the possibility of the surgeon being the predominant prognostic factor. Thus, this enabled us to clearly demonstrate the efficacy of neoadjuvant versus adjuvant chemoradiotherapy with no confounding factor and bias.

In this longitudinal prospective study, we compared the efficacy of adjuvant and neoadjuvant radiotherapy with fluoropyrimidine-based concomitant chemotherapy in patients with 2/3 distal rectal cancer. For a total of 155 patients for whom a standard surgery was implemented, LR rates of 30% in the first decade could be reduced to 7% in the second decade, thereby indicating the superiority of neoadjuvant chemoradiotherapy. Besides, in the Group NA, all LRR occurred within 25 months after the surgery, indicating a uniform biological behavior; however, LRR in the Group A followed an unpredictable course and were detected at 6–108 months after surgery (25% were observed after 24 months).

With respect to LRR and pCR, our results are similar to EORTC Radiotherapy Group Trial 22921 and FFCD 9203 Trial, in which a 5-year cumulative incidence of 7.6% and 8.1% LR with 13.4% and 11.4% pCR were reported, respectively, in the group of patients who received neoadjuvant chemoradiotherapy with postoperative chemotherapy. In these studies including 1100

Table 4. Loco-regional recurrence and distant metastasis

Group	Adjuvant	Neoadjuvant	p
Locoregional recurrence (n, %)			
Absent	56 (69.2)	69 (93.3)	<0.001
Present	25 (30.8)	5 (6.7)	
Distant metastasis (n, %)			
Absent	57 (70.4)	60 (81)	0.12
Present	24 (29.6)	14 (19)	
Locoregional recurrence with distant metastasis (n, %)	8 (9.8)	0 (0)	0.005
Metastatic site (n, %)			
Liver	13 (16.0)	2 (2.8)	
Lung	4 (4.9)	5 (7)	
Brain	0 (0)	1 (1.4)	
Peritonitis carcinomatosa	6 (7.5)	0 (0)	
Multiple metastases	1 (1.2)	4 (5.6)	
Other	0 (0)	2 (2.8)	

and 733 eligible patients, neoadjuvant chemoradiotherapy with adjuvant chemotherapy appeared to have a positive impact on LRR, despite the absence of any effect on OS; thus, this regime was recommended for T3-4, N0-2, and M0 adenocarcinoma of the mid- and distal rectum (9, 10).

pCR was obtained in nine patients of the Group NA (12.7%). All of these patients had well or moderately differentiated tumors, whereas MRI-based clinical stage varied between stage 2A and 3C. In another single-center trial with an identical treatment protocol, 24% of 140 patients had no viable tumor (T0) on the pathological analysis of the surgical specimens. Subgroup analysis of T0 tumors revealed that 26% of the preoperative stage 2 and 20% of the preoperative stage 3 patients achieved pCR after neoadjuvant chemoradiotherapy (11). Therefore, concerning the achievement of pCR, decision making via MRI staging and implementation of neoadjuvant radiotherapy in early stage tumors may produce excellent results. In a pooled analysis of 3105 patients in 17 prospective randomized clinical trials, 16% of the patients had pCR with a median follow-up of 48 months. pCR was the one and only predictor of disease-free survival with a hazard ratio of 0.54 (12).

Neoadjuvant (preoperative) concomitant chemoradiotherapy (CRT) has become a standard treatment of locally advanced rectal adenocarcinomas that represent clinical stages 2 (cT3-4, N0, M0) and 3 (cT1-4, N+, M0) according to International Union Against Cancer (IUCC) (13). During the initial phase of our study, we have included all pathological stage 2A (T3N0M0) patients in the Group A. To prevent any violation in the protocol, we have also included patients with MRI-stage 2A into the Group NA. In a systematic review of six randomized controlled trials regarding the efficacy of neoadjuvant chemoradiation for non-metastatic locally advanced rectal cancer, this treatment policy achieved a significant reduction in LR when compared with preoperative radiation-only arm (14). We have not

observed significant benefit of neoadjuvant chemoradiotherapy and adjuvant chemotherapy on OS or disease-free survival in our study. This finding may be regarded as inconsistent with some studies or meta-analyses; however, in majority of the studies, the OS benefit is low. For example, a meta-analysis of seven randomized control trials (RCTs) and 10 retrospective studies including >5000 patients who were treated with neoadjuvant chemoradiotherapy and surgery for rectal cancer, subsequent adjuvant chemotherapy improved the 5-year OS, particularly in downstaged patients and in retrospective series (15). In a single-center retrospective study of patients undergoing curative surgery for stage 2 and 3 rectal cancer, there was a significant difference in LR between the neoadjuvant chemoradiotherapy and surgery-alone groups but not in OS (64.2% versus 64.6%; $p=0.628$) (16).

Another reason underlying the lack of survival benefit in our series may be the standard neoadjuvant and adjuvant chemotherapy regimen composed of 5-FU in bolus (450 mg/m²) plus leucovorin (20 mg/m²). Furthermore, in a multi-center randomized trial of patients with pathological stage 2 or 3 rectal cancer after preoperative fluoropyrimidine-based chemoradiotherapy and TME, the addition of oxaliplatin to fluorouracil and leucovorin (FOLFOX) improved the 3-year disease-free survival (71.6%) when compared with that of the fluorouracil plus leucovorin group (62.9%) (hazard ratio, 0.657; $p=0.047$); thus, further investigation of different potential regimens as complementary to neoadjuvant chemoradiotherapy protocols is recommended (17). Finally, after a median follow-up of 11 years, the German Rectal Cancer Study Group reported a small but statistically significant benefit solely in local relapse (7% vs. 10%, respectively, in the Groups NA and A; $p=0.048$) and no differences in OS and disease-free survival (18).

Our study has some drawbacks. One of them is the absence of trans-rectal endoscopy for the preoperative staging of patients in both treatment periods. The second is that the chemotherapy protocol was invariably composed of 5-FU in bolus (450 mg/m²) plus leucovorin (20 mg/m²). It has already been demonstrated that infusional 5-FU rather than bolus 5-FU during RT increases the likelihood of pCR in patients with locally advanced rectal cancer (19). However, to prevent treatment bias in the period of neoadjuvant treatment, we did not use the infusion protocol.

CONCLUSION

Neoadjuvant chemoradiotherapy with TME is an efficient treatment protocol, particularly in terms of local relapse for the treatment of MRI-staged 2 and 3 patients with 2/3 distally located rectal adenocarcinomas. In addition, given that a considerable proportion of patients with cT2N0M0 would develop pCR, this treatment modality can be implemented more frequently in future studies.

Ethics Committee Approval: At the time the present study started there was no Local Review Board.

Informed Consent: Written informed consent was obtained from patients who participated in this study.

Peer-review: Externally peer-reviewed.

Author Contributions: Concept - A.U., B.Z.; Design - A.U., B.Z., H.Y.; Supervision - B.Z., A.U.; Funding - A.U., F.C., A.A.; Materials - B.Z., Z.A., A.U., A.A., N.E.; Data Collection and/or Processing - B.Z., C.S., G.A., I.Z., A.D.; Analysis and/or Interpretation - B.Z., A.U., Z.A., H.Y., A.A.; Literature Review - A.U., B.Z., B.C., A.A.; Writer - B.Z., A.U.; Critical Review - H.Y., A.A., B.C., F.C., C.S.; Other - Z.A., A.D., I.Z., N.E.

Conflict of Interest: No conflict of interest was declared by the authors.

Financial Disclosure: The authors declared that this study has received no financial support.

REFERENCES

- Wiggers T, de Vries MR, Veeze-Kuypers B. Surgery for local recurrence of rectal carcinoma. *Dis Colon Rectum* 1996; 39: 323-328. [\[CrossRef\]](#)
- Rich T, Gunderson LL, Lew R, Galdibini JJ, Cohen AM, Donaldson G. Patterns of recurrence of rectal cancer after potentially curative surgery. *Cancer* 1983; 52: 1317-1329. [\[CrossRef\]](#)
- Cummings BJ. Radiation therapy for colorectal cancer. *Surg Clin N Ame* 1993; 73: 167-181.
- James RD, Haboubi N, Schofield PF, Mellor M, Salhab N. Prognostic factors in colorectal carcinoma treated by preoperative radiotherapy and immediate surgery. *Dis Colon Rectum* 1991; 34: 546-551. [\[CrossRef\]](#)
- Stockholm Rectal Cancer Study Group: Preoperative short-term radiation therapy in operable rectal carcinoma. A prospective randomized trial. *Cancer* 1990; 66: 49-55. [\[CrossRef\]](#)
- Local recurrence rate in a randomised multicentre trial of preoperative radiotherapy compared with operation alone in resectable rectal carcinoma. Swedish Rectal Cancer Trial. *Eur J Surg* 1996; 162: 397-402.
- Uslu A, Postaci H, Yetis H, Selek E, Nart A, Corumlu B, et al. Longitudinal surveillance of mid- and distal rectum cancer in a subset of patients with specific histology. *Hepatogastroenterology* 2011; 58: 388-394.
- Pahlman L. Preoperative treatment of rectal cancer. In Bleiberg H, Rougier P, Joachim Wilke H (eds). *Management of colorectal cancer*. Martin Dunitz Ltd. 1998: 153-166.
- Gérard JP, Conroy T, Bonnetain F, Bouché O, Chapet O, Closos-Dejardin MT, et al. Preoperative radiotherapy with or without concurrent fluorouracil and leucovorin in T3-4 rectal cancers: results of FFCD 9203. *J Clin Oncol* 2006; 24: 4620-4625. [\[CrossRef\]](#)
- Bosset JF, Collette L, Calais G, Mineur L, Maingon P, Radosevic-Jelic L, et al. Chemotherapy with preoperative radiotherapy in rectal cancer. *N Engl J Med* 2006; 355: 1114-1123. [\[CrossRef\]](#)
- Onaitis MW, Robert B, Noone RB, Hartwig M, Hurwitz H, Morse M, et al. Neoadjuvant chemoradiation for rectal cancer: analysis of clinical outcomes from a 13-year institutional experience. *Ann Surg* 2001; 233: 778-785. [\[CrossRef\]](#)
- Maas M, Nelemans PJ, Valentini V, Das P, Rödel C, Kuo LJ, et al. Long-term outcome in patients with a pathological complete response after chemoradiation for rectal cancer: a pooled analysis of individual patient data. *Lancet Oncol* 2010; 11: 835-844. [\[CrossRef\]](#)
- Garajová I, Di Girolamo S, de Rosa F, Corbelli J, Agostini V, Bisasco G, et al. Neoadjuvant treatment in rectal cancer: actual status. *Chemother Res Pract* 2011; 2011: 839742. [\[CrossRef\]](#)
- McCarthy K, Pearson K, Fulton R, Hewitt J. Pre-operative chemoradiation for non-metastatic locally advanced rectal cancer. *Cochrane Database Syst Rev* 2012; 12: CD008368. [\[CrossRef\]](#)
- Petrelli F, Coinu A, Lonati V, Barni S. A systematic review and meta-analysis of adjuvant chemotherapy after neoadjuvant treatment and surgery for rectal cancer. *Int J Colorectal Dis* 2015; 30: 447-457. [\[CrossRef\]](#)
- Williamson JS, Jones HG, Davies M, Evans MD, Hatcher O, Beynon J, et al. Outcomes in locally advanced rectal cancer with highly selective preoperative chemoradiotherapy. *Br J Surg* 2014; 101: 1290-1298. [\[CrossRef\]](#)
- Hong YS, Nam BH, Kim KP, Kim JE, Park SJ, Park YS, et al. Oxaliplatin, fluorouracil, and leucovorin versus fluorouracil and leucovorin as adjuvant chemotherapy for locally advanced rectal cancer after preoperative chemoradiotherapy (ADORE): an open-label, multicentre, phase 2, randomised controlled trial. *Lancet Oncol* 2014; 15: 1245-1253. [\[CrossRef\]](#)
- Sauer R, Liersch T, Merkel S, Fietkau R, Hohenberger W, Hess C, et al. Preoperative versus postoperative chemoradiotherapy for locally advanced rectal cancer: results of the German CAO/ARO/AIO-94 randomized phase III trial after a median follow-up of 11 years. *J Clin Oncol* 2012; 30: 1926-1933. [\[CrossRef\]](#)
- Sanghera P, Wong DW, McConkey CC, Geh JI, Hartley A. Chemoradiotherapy for rectal cancer: an updated analysis of factors affecting pathological response. *Clin Oncol (R Coll Radiol)* 2008; 20: 176-183. [\[CrossRef\]](#)