

Effects of everolimus on a rat model of cerulein-induced experimental acute pancreatitis

Ratlarda deneysel olarak cerulein ile oluşturulmuş akut pankreatitte everolimusun etkileri

Alper Bilal Özkardeş¹, Birkan Bozkurt¹, Ersin Gürkan Dumlu¹, Mehmet Tokaç¹, Aylin Kılıç Yazgan², Merve Ergin³, Özcan Erel³, Mehmet Kılıç⁴

ABSTRACT

Objective: To analyze the biochemical and histopathological effects of everolimus in an experimental rat model of cerulein-induced acute pancreatitis. The aim of the present study was to determine the effects of everolimus on blood biochemical parameters and tissue histopathology in an experimental rat model of cerulein-induced acute pancreatitis.

Material and Methods: In 30 Wistar albino rats (male; 240–260 g), acute pancreatitis was induced by an intraperitoneal injection of cerulein (50 µg/kg) administered twice in 2 h. They were equally divided into the following three groups: 0.9% isotonic solution (Group 1; control), everolimus once (Group 2), and everolimus twice (Group 3) by oral gavage after cerulein injection. Thirty hours after the induction of pancreatitis, blood samples were collected by direct intracardiac puncture, rats were sacrificed, and pancreatic tissue samples were obtained.

Results: Biochemical analyses of the blood samples showed statistically significant difference in red blood cell count as well as hemoglobin, hematocrit, urea, and alanine transaminase levels among the study groups ($p < 0.05$ in all). Everolimus proved to significantly increase red blood cell count in a dose-independent manner. Hemoglobin and hematocrit levels significantly increased only after treatment with one dose of everolimus. Urea level was significantly different between the Groups 2 and 3; however, no change was observed in both groups when compared with the control. Alanine transaminase level significantly decreased only after treatment with two doses of everolimus. Histopathological analyses revealed that everolimus significantly decreased inflammation and perivascular infiltrate in a dose-dependent manner (35% in Group 2, 75% in Group 3; $p = 0.048$).

Conclusion: Treatment with two doses of everolimus improved some biochemical and histopathological parameters of experimental rat models of cerulein-induced acute pancreatitis and implied the specific inhibition of inflammatory response pathways.

Keywords: Pancreatitis, cerulein, everolimus, inflammation

ÖZ

Amaç: Deneysel rat modelinde cerulein ile indüklenmiş akut pankreatitte everolimusun biyokimyasal ve histopatolojik etkilerini incelemek. Mevcut çalışmanın amacı cerulein ile indüklenmiş akut pankreatitli deneysel rat modelinde everolimusun kan biyokimyasal parametrelerinde ve doku histopatolojisindeki etkilerini belirlemektir.

Gereç ve Yöntemler: Çalışmada, 30 adet Wistar-Albino rat (erkek, 240-260 gr) kullanıldı. Ceruleinin (50 µg/kg) 2 saat aralıkla intraperitoneal enjeksiyonu ile akut pankreatit oluşturuldu. Ratlar 3 gruba ayrılarak, cerulein enjeksiyonu sonrası gavaaj ile serum fizyolojik verilenler Grup 1, bir kez everolimus verilenler Grup 2 ve iki kez everolimus verilenler Grup 3 olarak isimlendirildi. Pankreatit indüksiyonundan otuz saat sonra kan örnekleri direkt intrakardiyak ponskiyon ile alındı, ratlar sakrifiye edildi ve pankreatik doku örnekleri alındı.

Bulgular: Kan örneklerinin biyokimyasal analizleri sonrasında gruplar arasında, kırmızı kan hücreleri, hemoglobin, hematokrit, üre ve alanin transaminaz seviyesinde anlamlı farklılık görüldü ($p < 0,05$). Everolimus doz bağımsız olarak kırmızı kan hücrelerinin seviyesinde anlamlı yükselişe neden oldu. Hemoglobin ve hematokrit seviyeleri ise tek doz everolimus sonrası artış gösterdi. Üre seviyesindeki değişim Grup 2 ve 3 arasında anlamlıyken, kontrol grubuna göre değişim gözlemlenmedi. Alanin transaminaz seviyesi sadece iki doz everolimus sonrası anlamlı bir azalma gösterdi. Histopatolojik analizler sonrasında everolimusla doz bağımlı olarak enflamasyon ve perivasküler infiltrasyonda anlamlı azalma olduğu görüldü (Grup 2 %35, Grup 3 %75; $p = 0,048$).

Sonuç: Çift doz everolimus tedavisi, cerulein ile indüklenmiş akut pankreatitin oluşturulduğu deneysel rat modelinde histopatolojik ve biyokimyasal parametrelerde değişimler sağlamakta ve bu da inflamatuvar cevap yollarının inhibisyonunu işaret etmektedir.

Anahtar kelimeler: Pankreatit, cerulein, everolimus, inflamasyon

INTRODUCTION

Acute pancreatitis is a localized inflammatory condition with a high mortality rate (2.1%–9.2%) worldwide. Because of its potential to trigger systemic inflammatory response, it can cause multiple organ failure (1, 2). The common causes of acute pancreatitis are alcohol abuse or gallstone disease (60%–75% of the cases) followed by hypertriglyceridemia, hyperparathyroidism, pancreatic malignancy, endoscopic retrograde cholangiopancreatography, trauma, infectious agents (increasingly associated with HIV infection), drugs (such as tetracycline, azathioprine, ethinyl estradiol, mercaptopurine, and sulfamethoxazole), autoimmunity, abdominal trauma, ischemia, diabetes mellitus, porphyria, and heredity (3–5).

Although the disease is common, the treatment of acute pancreatitis is still very limited. There are only a number of pharmacological approaches, which are mostly supportive involving adequate fluid resuscitation and oxygen supplementation, to maintain normal arterial oxygen saturation (6, 7). However, when the local inflammation of pancreas provokes the systemic inflammatory response syndrome (SIRS), the treatment requires intensive medical management and even surgery (3–5, 8, 9).

Everolimus [40-O-(2-hydroxyethyl)-rapamycin] is an orally administered analogue of rapamycin. Similar to rapamycin, everolimus and cyclophilin FKBP-12 complex binds to the serine/threonine kinase mTOR

¹Clinic of General Surgery, Atatürk Training and Research Hospital, Ankara, Turkey

²Clinic of Pathology, Atatürk Training and Research Hospital, Ankara, Turkey

³Department of Biochemistry, Yıldırım Beyazıt University Faculty of Medicine, Ankara, Turkey

⁴Department of General Surgery, Yıldırım Beyazıt University Faculty of Medicine, Ankara, Turkey

Yazışma Adresi

Address for Correspondence

Ersin Gürkan Dumlu

e-mail: gurkanumlu@gmail.com

Received / Geliş Tarihi: 20.04.2015

Accepted / Kabul Tarihi: 19.05.2015

©Copyright 2015

by Turkish Surgical Association

Available online at

www.uluscerrahidergisi.org

©Telif Hakkı 2015

Türk Cerrahi Derneği

Makale metnine

www.uluscerrahidergisi.org

web sayfasından ulaşılabilir.

and inhibits downstream signalling pathways for cell growth and proliferation (10-12). Although initially developed for the acute and chronic rejection of cardiac, liver, lung, and renal transplant recipients, everolimus is currently being used for the treatment of many cancer types, including renal cell carcinoma, pancreatic neuroendocrine tumors, and breast cancer (13, 14). As a novel proliferation inhibitor, the use of everolimus in various diseases is still ongoing. However, there are no data available in the literature regarding the potential use of everolimus for the treatment of acute pancreatitis, although its antitumor activity in patients with advanced pancreatic neuroendocrine tumors has been proved in a phase 3 study (15).

The aim of the present study is to determine the effects of everolimus on blood biochemical parameters and tissue histopathology in an experimental rat model of cerulein-induced acute pancreatitis.

MATERIAL AND METHODS

Study Design

This was an experimental animal study, which was approved by the Ankara Training and Research Hospital Ethics Committee for Animal Experiments, and all animal experiments were performed in accordance with international guidelines and local requirements.

Experimental Procedures and Biochemical Sampling

Thirty Wistar albino rats (male; 240–260 g) were used for experiments. Rats were kept in the standard room temperature and humidity for 2 days before the experiments with access to water and standard feed *ad libitum*. Experiments were performed under general anesthesia induced by intraperitoneal injections of ketaminehydrochloride (40 mg/kg) [Ketalar; Parke-Davis, Istanbul, Turkey] and xylazine (5 mg/kg) [Rompun; Bayer Turk Kimya San. Ltd., Istanbul, Turkey].

In all rats, acute pancreatitis was induced by an intraperitoneal injection of cerulein (50 µg/kg) [Sigma-Aldrich Chemie GmbH, Steinheim, Germany] administered twice in 2 h. Thirty rats were randomly and equally divided into the following three groups after anesthesia: 0.9% isotonic solution (Group 1; control), everolimus once (Group 2), and everolimus twice (Group 3). Group 1 was selected as control and was supported by 0.9% isotonic solution orally administered after cerulein injection. One dose of everolimus [Certican™; Novartis Pharma AG, Basel, Switzerland] diluted with physiologic serum to 1.5 mg/kg was administered to the rats in Group 2 by oral gavage at 4 h after cerulein injection. Two doses of everolimus were administered to Group 3 at 4 and 12 h after cerulein injection.

No animals were lost during the experiment. Blood samples were collected by direct intracardiac puncture at 30 h after the induction of pancreatitis for biochemical analysis. Rats were sacrificed by cervical dislocation. Pancreatic tissue samples were removed under sterile conditions and fixed in 10% formaldehyde solution for histopathological examination.

Biochemical and Histopathological Evaluation

Blood samples were analyzed for the following biochemical parameters: white blood cell count (/mm³), red blood cell count (/mm³), hemoglobin (g/dL), hematocrit (%), platelet (/

µL), total antioxidant status (mmol Trolox Eq/L), total oxidant status (µmol H₂O₂ Eq/L), paraoxonase-1 (U/L), arylesterase (U/L), ceruloplasmin (U/L), catalase (U/L), myeloperoxidase (U/L), urea (mg/dL), creatinine (mg/dL), aspartate aminotransferase (U/L), alanine transaminase (U/L), amylase (U/L), lipase (U/L), direct bilirubin (mg/dL), total bilirubin (mg/dL), and lactate dehydrogenase (U/L).

Total antioxidant and total oxidant statuses were spectrophotometrically determined using fully automated colorimetric measurement methods (16, 17). The assay results for total antioxidant status were calibrated against a Trolox standard curve and given in mm Trolox Eq/L. Results for the total oxidant status were calibrated against hydrogen peroxide (H₂O₂) standard curve and given in µmol H₂O₂ Eq/L.

Paraoxonase-1 and arylesterase activities were determined using commercially available Rel assay kits (18). Paraoxonase-1 assay was performed in the presence and absence of NaCl, and a molar absorptivity coefficient of 18290 M⁻¹cm⁻¹ was used for the calculation of enzymatic activity. For the determination of arylesterase activity, phenylacetate was used as the substrate, and a molar absorptivity coefficient of 1310 M⁻¹cm⁻¹ was used for the calculation of enzymatic activity.

Pancreatic tissue samples were fixed in 10% buffered formalin over 48 h as well as were dehydrated and embedded in paraffin wax for light microscopic analysis. Sections with a thickness of 4–6 µm were stained with hematoxylin and eosin (H&E) for the determination of general morphology. The stained sections were evaluated using a photomicroscope [Nikon photomicroscope; Japan] by an experienced histologist who was blinded to the experimental groups.

The histopathological findings such as pancreatic edema, acinar necrosis, hemorrhage, fat necrosis, inflammation, and perivascular infiltrate were evaluated. Each histopathological finding was scored from 1 to 4 according to criteria defined by Schmidt et al. (19), as shown in Table 1.

Statistical Analysis

Statistical analysis was conducted using the Statistical Package for Social Sciences software package (SPSS; version 13.0; SPSS Inc., Chicago, Illinois, USA). Results are expressed as the mean±standard deviation (SD) for quantitative data. Groups of data were compared using the one-way ANOVA test followed by Tukey test for post hoc analysis. A p value of <0.05 was accepted to be statistically significant.

RESULTS

Biochemical Parameters

The biochemical changes in the blood samples of three groups of rats (Group 1, control; Group 2, cerulein-induced acute pancreatitis treated with one dose of everolimus; and Group 3, cerulein-induced acute pancreatitis treated with two doses of everolimus) are summarized in Tables 2 and 3. Most of the biochemical parameters analyzed (16 of 21) did not show statistically significant differences among the groups (Table 2).

On the other hand, analyses of red blood cell count as well as hematocrit, hemoglobin, urea, and alanine transaminase

Table 1. Histopathological scoring criteria according to Schmidt et al. (19)

Score	Criteria
Edema	
0	Absent
0.5	Focal expansion of interlobar septae
1	Diffuse expansion of interlobar septae
1.5	Same as 1+focal expansion of interlobular septae
2	Same as 1+diffuse expansion of interlobular septae
2.5	Same as 2+focal expansion of interacinar septae
3	Same as 2+diffuse expansion of interacinar septae
3.5	Same as 3+focal expansion of intercellular spaces
4	Same as 3+diffuse expansion of intercellular spaces
Acinar necrosis	
0	Absent
0.5	Focal occurrence of 1–4 necrotic cells/HPF
1	Diffuse occurrence of 1–4 necrotic cells/HPF
1.5	Same as 1+focal occurrence of 5–10 necrotic cells/HPF
2	Diffuse occurrence of 5–10 necrotic cells/HPF
2.5	Same as 2+focal occurrence of 11–16 necrotic cells/HPF
3	Diffuse occurrence of 1 1–16 necrotic cells/HPF (foci of confluent necrosis)
3.5	Same as 3+focal occurrence of >16 necrotic cells/HPF
4	>16 necrotic cells/HPF (Extensive confluent necrosis)
Hemorrhage and fat necrosis	
0	Absent
0.5	1 focus
1	2 foci
1.5	3 foci
2	4 foci
2.5	5 foci
3	6 foci
3.5	7 foci
4	>7 foci
Inflammation and perivascular infiltrate	
0	0-1 intralobular or perivascular leukocytes/HPF
0.5	2–5 intralobular or perivascular leukocytes/HPF
1	6–10 intralobular or perivascular leukocytes/HPF
1.5	11–15 intralobular or perivascular leukocytes/HPF
2	16–20 intralobular or perivascular leukocytes/HPF
2.5	21–25 intralobular or perivascular leukocytes/HPF
3	26–30 intralobular or perivascular leukocytes/HPF
3.5	>30 leukocytes/HPF or focal microabscesses
4	>35 leukocytes/HPF or confluent microabscesses
HPF: high-power field	

levels proved to be significantly different when group data were compared (Table 3). Accordingly, on comparing with the control, red blood cell count significantly increased when treated with one dose of everolimus (Group 2; $p=0.011$) as well as when treated with two doses of everolimus (Group 3;

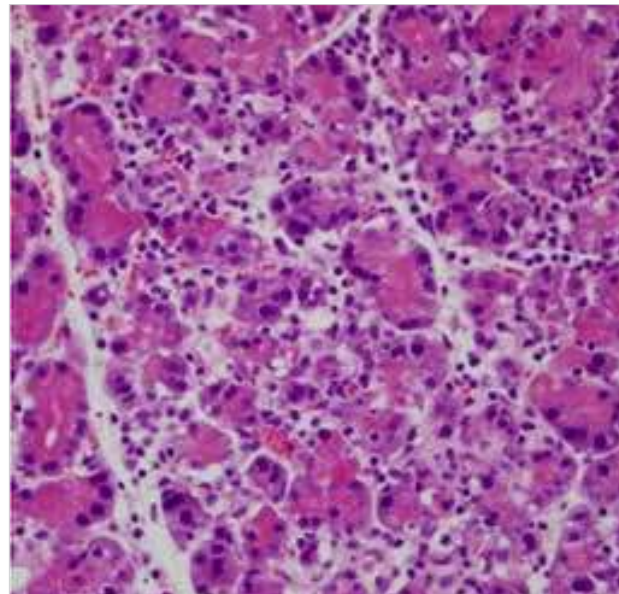


Figure 1. Histopathological assessment (H&E; $\times 400$) showing acinar necrosis in the pancreatic tissue of Group 3 (cerulein-induced pancreatitis treated with two doses of everolimus)

$p=0.019$); however, no significant difference was detected between the Groups 2 and 3. Hemoglobin and hematocrit values significantly increased only in Group 2 when compared with the control ($p=0.022$ and $p=0.043$, respectively) but showed no statistically significant difference in Group 3, although an increase in the values when compared with the control data was obvious. Urea level did not change when compared between the control and everolimus-treated rat groups; however, there was a statistically significant increase in urea level in Group 3 (two doses) compared with Group 2 (one dose) ($p=0.01$; Table 3). Alanine transaminase is the only biochemical parameter that showed a decrease after everolimus treatment when compared with the control. Accordingly, in Group 3 (cerulein-induced acute pancreatitis treated with two doses of everolimus), alanine transaminase level significantly decreased (approximately up to 20%) when compared with the control ($p=0.038$; Table 3).

Histopathological Scoring

Histopathological analyses included the determination of pancreatic edema, acinar necrosis, hemorrhage, fat necrosis, inflammation, and perivascular infiltrate. Varying degrees of pathological changes were observed in all the groups (Figures 1 and 2) and scored according to Schmidt et al. (19) (Table 4). Statistical comparison of results showed no significant differences in pancreatic edema, acinar and fat necroses, and hemorrhage after everolimus treatment. On the other hand, the treatment of everolimus during acute pancreatitis in rats resulted in significantly lower inflammation and lower level of perivascular infiltrate ($p=0.048$; Table 4); in Group 2, inflammation and level of perivascular infiltrate decreased by 35% and in Group 3 (Figure 2), they decreased by 75%.

DISCUSSION

The incidence of acute pancreatitis has increased up to 10-fold over the past 20 years; however, the sudden onset and poorly understood pathophysiology of acute pancreatitis still limit

Table 2. Biochemical parameters of the groups with no statistically significant differences

	Group 1 (Control) n=10	Group 2 (One dose of everolimus) n=10	Group 3 (Two doses of everolimus) n=10	p ^a
White blood cell count (/mm ³)	8.42±2.17	7.83±1.03	8.75±2.5	0.585
Platelet (/μL)	473.8±87.05	435.7±137.05	500.7±165.91	0.559
Total antioxidant status (mmol Trolox Eq/L)	2.04±0.23	1.85±0.14	1.93±0.15	0.070
Total oxidant status (μmol H ₂ O ₂ Eq/L)	12.12±7.49	8.55±6.06	12.29±6.4	0.381
Paraoxonase-1 (U/L)	90.92±100.97	44.82±61.55	62.35±73	0.442
Arylesterase (U/L)	43.47±46.04	30.13±27.64	24.05±24.68	0.439
Ceruloplasmin (U/L)	22.92±4.55	22.91±2.33	24.48±2.16	0.461
Catalase (U/L)	240.27±167.19	118.1±105.97	208.67±131.9	0.138
Myeloperoxidase (U/L)	272.03±129.78	273.54±111.82	321.7±130.22	0.602
Creatinine (mg/dL)	0.23±0.05	0.3±0.07	0.3±0.12	0.106
Aspartate aminotransferase (U/L)	98.5±20.47	96±14.78	86.2±10.99	0.207
Amylase (U/L)	2222.4±708.18	2411.1±364.45	2642.1±640.95	0.298
Lipase (U/L)	6.6±2.64	5.1±0.32	5.1±0.32	0.059
Direct bilirubin (mg/dL)	0.02±0.02	0.03±0.02	0.02±0.02	0.703
Total bilirubin (mg/dL)	0.03±0.05	0.05±0.08	0.06±0.07	0.571
Lactate dehydrogenase (U/L)	325.1±178.86	202.4±60.44	234.9±75.64	0.070

Results are given as the mean±standard deviation (SD).
^aComparative analysis was performed with one-way ANOVA test followed by Tukey test.

Table 3. Biochemical parameters with statistically significant differences between groups

	Group 1 (G1, Control) n=10	Group 2 (G2, One dose of everolimus) n=10	Group 3 (G3, Two doses of everolimus) n=10	p ^a
Red blood cell count (/mm ³)	7.35±0.38	7.91±0.45	7.87±0.38	G1-G2=0.011 G1-G3=0.019 G2-G3=0.969
Hemoglobin (g/dL)	12.9±0.7	13.87±0.5	13.44±1.02	G1-G2=0.022 G1-G3=0.270 G2-G3=0.429
Hematocrit (%)	38.99±2.46	41.43±1.28	41.23±2.47	G1-G2=0.043 G1-G3=0.067 G2-G3=0.976
Urea (mg/dL)	7.35±0.38	7.91±0.45	7.87±0.38	G1-G2=0.011 G1-G3=0.019 G2-G3=0.969
Alanine transaminase (U/L)	63.7±9.45	57.1±13.08	51.2±9.31	G1-G2=0.369 G1-G3=0.038 G2-G3=0.448

Results are given as the mean±standard deviation (SD).
^aComparative analysis was performed with Tukey test.

the pharmacological approaches (1, 3-6, 20, 21). The disease is characterized by the activation of leukocytes and release of proinflammatory cytokines resulting in local pancreatic inflammation and acinar cell damage (1, 3, 20). The inflammation results in edema, vascular damage, hemorrhage, and

necrosis in pancreatic tissues; acinar cell damage leads to the local activation of the immune system, thereby triggering SIRS followed by multiple organ failure, which is the main reason for high mortality rates (20%–60%) because of acute pancreatitis (1, 3, 22).

Table 4. Histopathological parameters of the study groups

	Group 1 (Control) n=10	Group 2 (One dose of everolimus) n=10	Group 3 (Two doses of everolimus) n=10	p ^a
Edema	2±0.52	2.5±0.73	1.2±0.41	0.069
Acinar necrosis	0.5±0.58	1.0±0.97	0.5±0.96	0.305
Hemorrhage and fat necrosis	1.5±1.14	2.0±0.78	2.0±1.22	0.861
Inflammation and perivascular infiltrate	0.75±1.3	0.75±0.74	0.0±0.50	0.048

Each histopathological finding was scored from 1 to 4 according to criteria defined by Schmidt et al. (19), as shown in Table 1. Results are given as the median±standard deviation.

^aComparative analysis was performed with one-way ANOVA test followed by Tukey test.

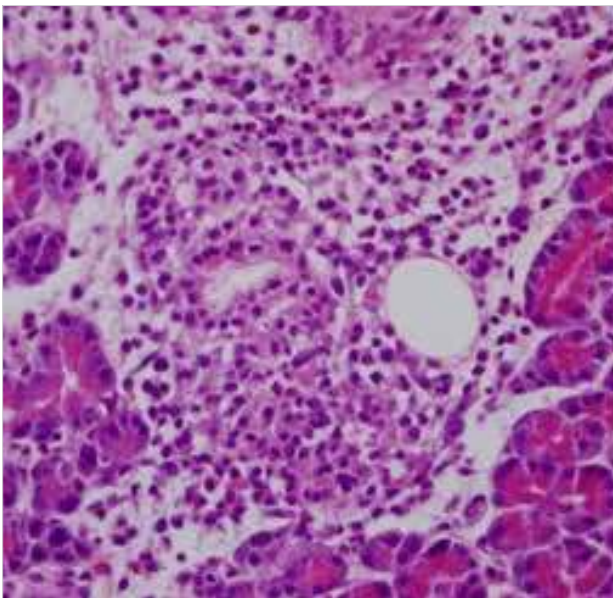


Figure 2. Histopathological assessment (H&E; ×400) showing focal abscess in the pancreatic tissue of Group 3 (cerulein-induced pancreatitis treated with two doses of everolimus)

The early diagnosis for the prediction of severity of acute pancreatitis is a critical factor as the disease is only curable before SIRS is initiated. However, the choice of the right marker for diagnosis is rather difficult as the change in biochemical parameters depend on etiology, age, gender, race, genetic constitution, severity on admission, and the extent and infection of pancreatic necrosis (22). The most reliable prognostic markers include blood cell count, blood urea nitrogen, creatinine, hematocrit, proteinuria, C-reactive protein, matrix metalloproteinase-9, serum amyloid A protein, interleukin-6, interleukin-8, interleukin-18, trypsinogen-2, and trypsin-2-alpha 1 antitrypsin complex (22).

In this study, we investigated the biochemical and histopathological effects of the use of the novel proliferation inhibitor everolimus, which is mostly used as an anticancer drug, on the treatment of acute pancreatitis. The best approach to study the effects of a particular treatment on the course of acute pancreatitis is the use of experimental animal models. Cerulein-induced acute pancreatitis in rat is the most widely used model with biochemical, morphological, and pathophysiological similarities to the various aspects of human pancreatitis

(20, 23). In this experimental study, we used Wistar albino rat models with cerulein-induced acute pancreatitis. Rat models were divided into three groups, one of which was the control group treated with cerulein alone to induce acute pancreatitis; the other two groups received everolimus by oral gavage, i.e., one dose at the 4th h and two doses at the 4th and 12th h after cerulein injection, respectively. Biochemical and histopathological analyses of the effects of everolimus were performed at 30 h after the induction of acute pancreatitis with cerulein injection using intercardiac blood and pancreatic tissue samples of experimental rat models.

White blood cell count, red blood cell count, hemoglobin, hematocrit, platelet, total antioxidant status, total oxidant status, paraoxonase-1, arylesterase, ceruloplasmin, catalase, myeloperoxidase, urea, creatinine, aspartate aminotransferase, alanine transaminase, amylase, lipase, direct bilirubin, total bilirubin, and lactate dehydrogenase were determined as biochemical parameters. It was found that the use of everolimus as a treatment for acute pancreatitis resulted in no significant changes in most of these parameters when compared with controls or when compared between one dose or two doses of everolimus-treated groups.

Red blood cell count as well as hemoglobin and hematocrit levels of the experimental rat models of cerulein-induced acute pancreatitis increased after everolimus treatment when compared with the control group that received no treatment (Table 3). A statistically significant increase in red blood cell count was found to be independent of the number of times everolimus was administered by oral gavage. On the other hand, a statistically significant increase in hemoglobin and hematocrit was found only in the one dose of everolimus-treated group when compared with the control. Although statistically insignificant, an obvious increase when compared with the control was observed in both parameters in the group of experimental rats treated with two doses of everolimus. The control group in this study received no treatment and was expected to develop acute pancreatitis. Red blood cell count and hematocrit are among the prognostic markers of acute pancreatitis (22, 24); therefore, a decrease in the abovementioned biochemical parameters in the control group was expected. The increase in red blood cell count as well as in hematocrit and hemoglobin levels after everolimus treatment suggests an improvement of tissue oxygenation (25) and of microcirculatory function (26). A decrease in blood urea nitrogen level is a rapid and reliable prognostic marker for acute pancreatitis (22).

On comparing the blood urea levels of experimental rat models with cerulein-induced acute pancreatitis, the values of the blood urea levels showed almost no change after one dose of everolimus treatment; however, two doses of everolimus treatment resulted in an increase in the value when compared with that of the control (Table 3). On the other hand, a statistically significant increase ($p<0.05$) was only observed when two groups that received everolimus after cerulein injection were compared (Table 3). All of these observations may imply recovery from pancreatic tissue damage induced by cerulein injection.

The liver enzyme alanine transaminase is also found in kidneys, heart, muscles, and pancreas in small amounts. The biochemical determination of this parameter in the blood samples of patients with acute pancreatitis has been used to determine whether the liver is damaged or diseased (27). In this study, the alanine transaminase level of the control group of rats with cerulein-induced acute pancreatitis showed a decrease after everolimus treatment by oral gavage (Table 3). The inflammatory response is known to develop very rapidly in the experimental rat models of cerulein-induced acute pancreatitis (28); therefore, the increase in the amount of alanine transaminase detected in blood samples may imply that SIRS has already been initiated, and that the liver has been damaged because of acute pancreatitis. The comparison of two different doses of everolimus treatment indicated that two doses of everolimus resulted in approximately 20% decrease in blood alanine transaminase levels, suggesting that the effect is dependent on the amount of everolimus used in the treatment (Table 3).

In this study, the histopathological analyses of pancreatic tissue samples of experimental rat models was scored with respect to pancreatic edema, acinar and fat necroses, hemorrhage, inflammation, and perivascular infiltrate. Although the other three scores did not show any significant difference, a decrease in inflammation and perivascular infiltrate score by 35% in experimental rat models with cerulein-induced acute pancreatitis administered with one dose of everolimus by oral gavage and a decrease by 75% in those administered with two doses of everolimus were the most significant and promising findings of this study (Table 4). Because the mortality rate significantly increases with multiple organ failure because of SIRS, the specific inhibition of inflammatory signalling pathways presents a great potential as pharmacological treatment (2, 6, 21). The significant decrease in inflammation and perivascular infiltrate score may imply that everolimus treatment directly or indirectly interferes with the inflammatory signalling pathway, thereby inhibiting SIRS.

CONCLUSION

Everolimus treatment improved red blood cell count and inflammation as well as hemoglobin, hematocrit, urea, alanine transaminase, and perivascular infiltrate levels in the experimental rat models of cerulein-induced acute pancreatitis. Significant decrease in blood alanine transaminase levels combined with approximately 75% decrease in histopathological inflammation and perivascular infiltrate score after two treatments indicates the potential of everolimus in the specific inhibition of SIRS, which is the main reason for the death of patient due to acute pancreatitis. These findings imply the importance of new experimental and clinical studies for investigating the

therapeutic role and optimum dosage of everolimus in the treatment of acute pancreatitis.

Ethics Committee Approval: Ethics committee approval was received for this study from the ethics committee of Ankara Training and Research Hospital Ethics Committee for Animal Experiments.

Peer-review: Externally peer-reviewed.

Author Contributions: Concept - A.B.Ö., E.G.D., B.B.; Design - A.B.Ö., B.B.; Supervision - M.K., Ö.E.; Funding - B.B., E.G.D.; Materials - A.K.Y., M.E.; Data Collection and/or Processing - M.T., E.G.D.; Analysis and/or Interpretation - A.B.Ö., B.B.; Literature Review - A.B.Ö., E.G.D., M.T.; Writer - A.B.Ö.; Critical Review - Ö.E., M.K.

Conflict of Interest: No conflict of interest was declared by the authors.

Financial Disclosure: The authors declared that this study has received no financial support.

Etik Komite Onayı: Bu çalışma için etik komite onayı Ankara Eğitim ve Araştırma Hastanesi Deney Hayvanları Etik Kurulu'ndan alınmıştır.

Hakem Değerlendirmesi: Dış bağımsız.

Yazar Katkıları: Fikir - A.B.Ö., E.G.D., B.B.; Tasarım - A.B.Ö., B.B.; Denetleme - M.K., Ö.E.; Kaynaklar - B.B., E.G.D.; Malzemeler - A.K.Y., M.E.; Veri Toplanması ve/veya İşlemesi - M.T., E.G.D.; Analiz ve/veya Yorum - A.B.Ö., B.B.; Literatür Taraması - A.B.Ö., E.G.D., M.T.; Yazıyı Yazan - A.B.Ö.; Eleştirel İnceleme - Ö.E., M.K.

Çıkar Çatışması: Yazarlar çıkar çatışması bildirmemişlerdir.

Finansal Destek: Yazarlar bu çalışma için finansal destek almadıklarını beyan etmişlerdir.

REFERENCES

1. Bulut NE, Özkan E, Ekinci O, Dulundu E, Topaloğlu Ü, Şehirli AÖ, et al. Beneficial effects of alpha lipoic acid on cerulein-induced experimental acute pancreatitis in rats. *Ulus Travma Acil Cerrahi Derg* 2011; 17: 383-389. [\[CrossRef\]](#)
2. Hoque R, Malik AF, Gorelick F, Mehal WZ. Sterile inflammatory response in acute pancreatitis. *Pancreas* 2012; 41: 353-357. [\[CrossRef\]](#)
3. Kilic E, Amanvermez R, Kefeli M, Polat C, Gunay M. Protective effects of etanercept and methylprednisolone on pancreatic damage in cerulein-induced acute pancreatitis. *Saudi Med J* 2010; 31: 394-399.
4. Kingsnorth A, O'Reilly D. Acute pancreatitis. *BMJ* 2006; 332: 1072-1076. [\[CrossRef\]](#)
5. Kota SK, Krishna SVS, Lakhtakia S, Modi KD. Metabolic pancreatitis: Ethnopathogenesis and management. *Indian J Endocrinol Metab* 2013; 17: 799-805. [\[CrossRef\]](#)
6. Bang UC, Semb S, Nojgaard C, Bendtsen F. Pharmacological approach to acute pancreatitis. *World J Gastroenterol* 2008; 14: 2968-2976. [\[CrossRef\]](#)
7. Easler JJ, Mounzer R, Papachristou GI. Pharmacological therapy for acute pancreatitis: where are we now? where are we going? *Minerva Gastroenterol Dietol* 2012; 58: 365-376.
8. Raraty MG, Connor S, Criddle DN, Sutton R, Neoptolemos JP. Acute pancreatitis and organ failure: pathophysiology, natural history, and management strategies. *Curr Gastroenterol Rep* 2004; 6: 99-103. [\[CrossRef\]](#)
9. Schepers NJ, Besselink MG, van Santvoort HC, Bakker OJ, Bruno MJ; Dutch Pancreatitis Study Group. Early management of acute pancreatitis. *Best Pract Res Clin Gastroenterol* 2013; 27: 727-743. [\[CrossRef\]](#)
10. Gabardi S, Baroletti SA. Everolimus: a proliferation signal inhibitor with clinical applications in organ transplantation, oncology, and cardiology. *Pharmacotherapy* 2010; 30: 1044-1056. [\[CrossRef\]](#)

11. Garnock-Jones KP, Keating GM. Everolimus. *Drugs* 2009; 69: 2115-2124. [\[CrossRef\]](#)
12. Houghton PJ. Everolimus. *Clin Cancer Res* 2010; 16: 1368-1372. [\[CrossRef\]](#)
13. Nashan B. Review of the proliferation inhibitor everolimus. *Drug Evaluation* 2002; 11: 1845-1857. [\[CrossRef\]](#)
14. Lebwohl D, Anak O, Sahmoud T, Klimovsky J, Elmroth I, Haas T, et al. Development of everolimus, a novel oral mTOR inhibitor, across a spectrum of diseases. *Ann N Y Acad Sci* 2013; 1291: 14-32. [\[CrossRef\]](#)
15. Yao JC, Shah MH, Ito T, Bohas CL, Wolin EM, Van Cutsem E. Everolimus for advanced pancreatic neuroendocrine tumors. *N Engl J Med* 2011; 364: 514-523. [\[CrossRef\]](#)
16. Erel O. A novel automated method to measure total antioxidant response against potent free radical reactions. *Clin Biochem* 2004; 37: 112-119. [\[CrossRef\]](#)
17. Erel O. A new automated colorimetric method for measuring total oxidant status. *Clin Biochem* 2005; 38: 1103-1111. [\[CrossRef\]](#)
18. Toy H, Camuzcuoglu H, Celik H, Erel O, Aksoy N. Assessment of serum paraoxonase and arylesterase activities in early pregnancy failure. *Swiss Med Wkly* 2009; 139: 76-81.
19. Schmidt J, Rattner DW, Lewandrowski K, Compton CC, Mandavilli U, Knoefel WT, et al. A better model of acute pancreatitis for evaluating therapy. *Ann Surg* 1992; 215: 44-56. [\[CrossRef\]](#)
20. Kim H. Cerulein pancreatitis: Oxidative stress, inflammation, and apoptosis. *Gut Liver* 2008; 2: 74-80. [\[CrossRef\]](#)
21. Lankish PG, Lerch MM. Pharmacological prevention and treatment of acute pancreatitis: where are we now? *Dig Dis* 2006; 24: 148-159. [\[CrossRef\]](#)
22. Al Mofleh IA. Severe acute pancreatitis: pathogenetic aspects and prognostic factors. *World J Gastroenterol* 2008; 14: 675-684. [\[CrossRef\]](#)
23. Kahl S, Mayer JM. Update on experimental acute pancreatitis. *Minerva Gastroenterol Dietol* 2012; 58: 355-363.
24. Chmiel B, Pajak J, Grabowska-Bochenek R, Cierpka L. Decreased red blood cells deformability in acute pancreatitis in the rat. Effect of tirilazad mesylate. *Folia Med Cracov* 2003; 44: 109-115.
25. Mao EQ, Fei J, Peng YB, Huang J, Tang YQ, Zhang SD. Rapid hemodilution is associated with increased sepsis and mortality among patients with severe acute pancreatitis. *Chin Med J (Engl)* 2010; 123: 1639-1644.
26. Strate T, Mann O, Kleinhans H, Rusani S, Schneider C, Yekebas E, et al. Microcirculatory function and tissue damage is improved after therapeutic injection of bovine hemoglobin in severe acute rodent pancreatitis. *Pancreas* 2005; 30: 254-259. [\[CrossRef\]](#)
27. Moolla Z, Anderson F, Thomson SR. Use of amylase and alanine transaminase to predict acute gallstone pancreatitis in a population with high HIV prevalence. *World J Surg* 2013; 37: 156-161. [\[CrossRef\]](#)
28. Buyukberber M, Savas MC, Bagci C, Koruk M, Gulsen TM, Tutar E, et al. The beneficial effect of propolis on cerulein-induced experimental acute pancreatitis in rats. *Turkish J Gastroenterol* 2009; 20: 122-128.