



# Adrenal angiosarcoma

Gülden Cancan, Serkan Teksöz, Süleyman Demiryas, Murat Özcan, Yusuf Bükey

## ABSTRACT

Adrenal angiosarcoma is an uncommon neoplasm that derives from the vascular endothelium; due to its biological behavior, it should be distinguished from other adrenal tumors. We herein report a case of a 57-year-old woman with diagnosis of an adrenal tumor that was suspected to be malignant. The specimen was histopathologically proved to be an angiosarcoma. The patient was suffering from right upper quadrant pain; after laboratory and radiological workup, a non-functioning right adrenal mass, 14 cm in size, was recognized. A right subcostal incision was made, and adrenalectomy was performed successfully with tumor-free surgical margins. Two months after the operation, a positron emission tomography-computed tomography scan was ordered for follow-up. No tumor tissue or any other metastatic foci remained. The patient had been referred to our medical oncology department and underwent retroperitoneal radiotherapy. However, unfortunately, the patient died due to cardiac insufficiency during the follow-up period.

**Keywords:** Adrenal angiosarcoma, adrenal gland, malignant vascular tumors, adrenal incidentaloma

## INTRODUCTION

Adrenal angiosarcomas are infrequently encountered neoplasms in daily practice; therefore, they are not well documented in the literature. The etiological factors of this neoplasm are still not clearly understood; however, in a case report, exposure to some carcinogens was believed to be the cause of an adrenal angiosarcoma. There is no evidence supporting the relationship between primary adrenal angiosarcoma and multiple neuroendocrine tumors. Also, administration of radiation therapy in the past or previous abdominal traumas has no correlation with adrenal angiosarcoma (1). In most cases, adrenal angiosarcomas are diagnosed coincidentally following routine workup for patient complaints, which are generally non-specific abdominal discomfort or pain (2, 3). In this report, we present a new case of adrenal gland angiosarcoma of unusual size, which will enrich the collected scientific data on this very rare clinical entity.

## CASE PRESENTATION

A 57-year-old female patient with right upper abdominal pain was admitted to our hospital. Her past medical history included hypertension and hypercholesterolemia, which were under control. On physical examination, slight tenderness was found in the right upper quadrant, without any rebound or Murphy's sign. Cholecystitis was one of our differential diagnoses; therefore, the patient underwent abdominal ultrasound (US). Multiple gallstones were detected; however, significantly, a 14-cm abdominal lesion was also recognized beneath the liver. Therefore, computed tomography (CT) scans of the abdomen (Figure 1) and chest were ordered. A heterogeneous mass 14×12 cm in diameter, originating from the right adrenal gland, was revealed without contrast dye. There were no additional metastatic disseminations. Blood and urinary analyses documented no hormonal activity of the tumor. Preoperative LDH measurement was 422 U/L, VMA was 1.93 mg/day, normetanephrine was 255.5 µg/24 h, metanephrine was 60.9 µg/24 h, and cortisone was 2.03 µg/dL. There were no other significant results in the patient's biochemical or complete blood count workup. Because of the size of the tumor and its malignant potential, an open surgical procedure with right sub-costal incision was decided upon. Through a retroperitoneal approach, the solid mass, which was 15×10 cm in diameter, was dissected, and its bandings to the liver and right kidney were also freed using LigaSure. The mass had a highly vascular, solid appearance and was infiltrating the liver and its surrounding fatty tissues. Cholecystectomy and right adrenalectomy were performed together. The histopathological report that was acquired for the cholecystectomy material indicated chronic cholecystitis with multiple cholelithiasis. The adrenal tumor specimen was measured to be 16×10 cm with a weight of 886 grams (Figure 2). Histopathological examination showed that the tumor was an angiosarcoma containing hemorrhagic and necrotic areas that were infiltrating the adrenal cortex (Figure 3). The surgical boundaries were also reported as 2 mm distant to the tumoral lesion. Immunohistochemical study revealed that the tumor was expressing cluster of differentiation 31 (CD 31) (Figure 4).

## Cite this paper as:

Cancan G, Teksöz S, Demiryas S, Özcan M, Bükey Y. Adrenal angiosarcoma. Turk J Surg 2018; 34: 146-148.

Department of General Surgery,  
İstanbul University Cerrahpaşa  
School of Medicine, İstanbul,  
Turkey

## Corresponding Author Serkan Teksöz

e-mail: serkanteksoz@gmail.com

Received: 16.03.2015

Accepted: 04.08.2015

Available Online Date: 03.01.2018

©Copyright 2018  
by Turkish Surgical Association  
Available online at  
www.turkjsurg.com

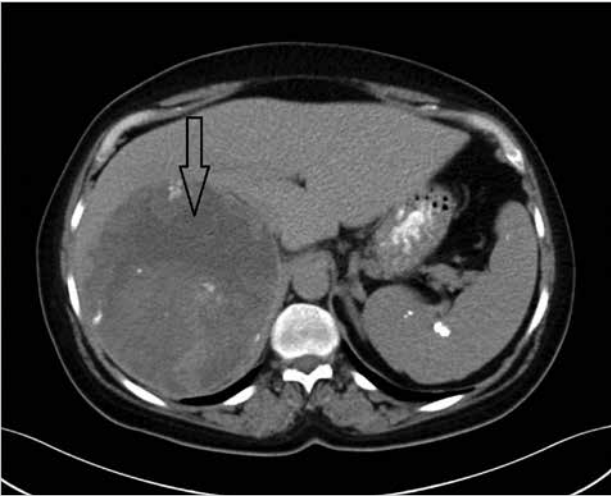


Figure 1. Computed tomographic images of the tumor

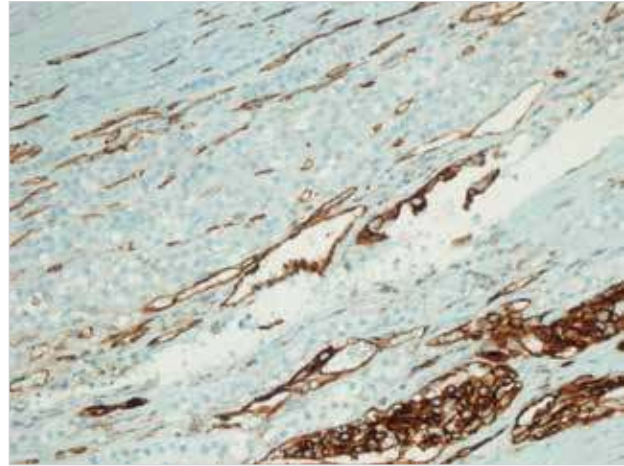


Figure 4. Tumoral cells expressing the typical vascular marker CD31 (CD31 ×200)

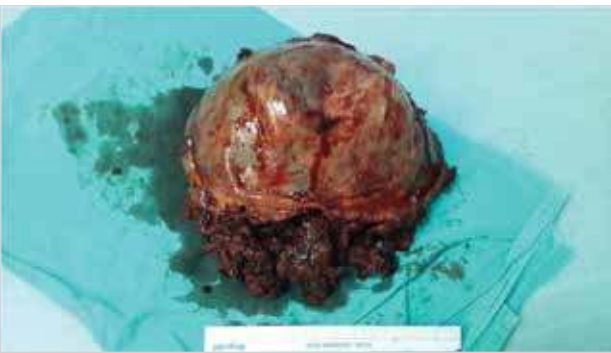

Figure 2. Macroscopic appearance of the tumor

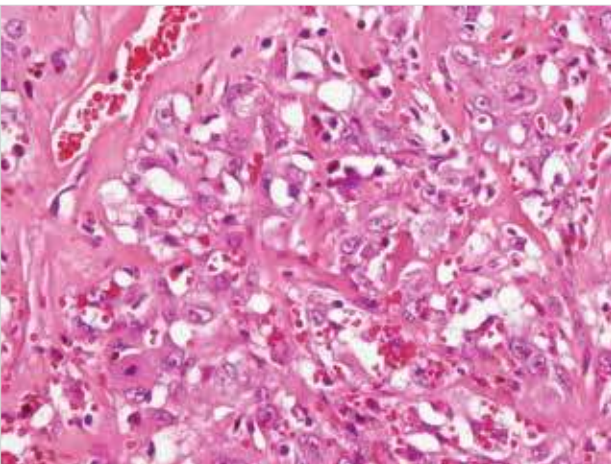


Figure 3. Vasoformative areas consisting of high grade epithelioid atypical endothelial cells (H&E ×400)

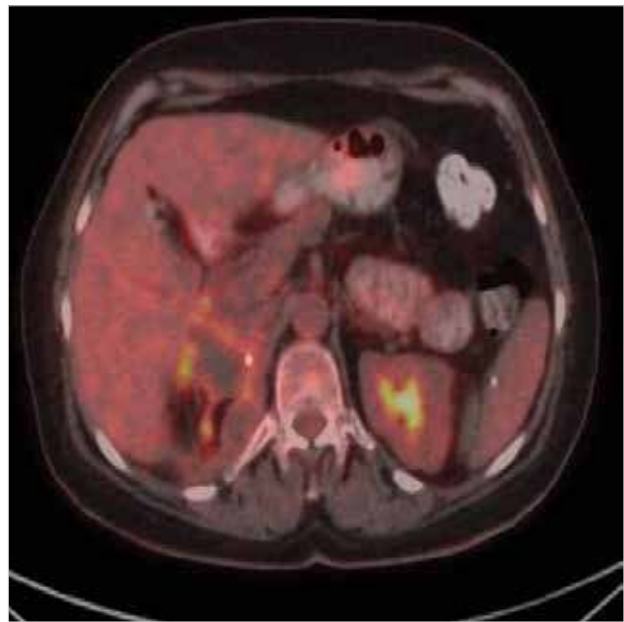


Figure 5. PET-CT scans of the patient after surgery

Postoperatively, the patient underwent medical oncology follow-up. Two months after the surgery, a whole body positron emission tomography-computed tomography (PET-CT) scan was performed; it showed no remaining tumoral tissue or any other metastatic foci (Figure 5). The tumor was large in size; retroperitoneally, it filled the upper right quadrant of the abdomen. Therefore, adjuvant radiotherapy was planned for the patient. She underwent a single dose of radiation therapy. In the 10th month of the postoperative period, the patient died due to cardiac insufficiency without any detected tumoral relapse. A written informed consent obtained from the patient.

#### DISCUSSION

Angiosarcomas are very rare, malignant vascular tumors with high mortality rates (3, 4). Primary adrenal angiosarcoma is an especially rare entity that was first described by Karetí et al. (5) in 1988. Generally, the disease is predominant in males, is seen between the fourth and ninth decades, and presents with abdominal pain (2, 6). Radiologically, it is a heterogeneous mass whose size is greater than 5 cm. Also, the tumor usually expresses epithelioid histopathological findings (2, 7).

In this case, a right adrenal mass was recognized during an examination for biliary colic. The patient had neither a history of malignancy nor laboratory findings indicating any hormonal hyperfunctionality. Her hypertension was under medical control and was noted to be unrelated to her adrenal mass.

Regarding the optimal imaging method for adrenal masses, CT scan is the method of choice. In our case, a heterogeneous mass 14×12 cm in diameter adjacent to the inferior vena cava and the right renal vein was visualized in the CT scan; it was not dyed with contrast material (8, 9). The metastatic foci

were ruled out before the operation decision. Although the treatment modality for patients with adrenal angiosarcomas remains controversial, surgical eradication appears to have better outcomes (1). We also prefer open surgery with a right subcostal incision when malignancy is suspected. On the basis of the limited reports of adrenal angiosarcomas in the literature, surgery was combined with chemotherapy and radiotherapy. We did not choose a laparoscopic technique because it would not be adequate to resect a tumor of this size.

In the literature, the treatment modality of this rare case is described as controversial (1, 10). Due to limited experience with adrenal angiosarcomas, surgeons pursue different surgical extension procedures. According to the review by Stavridis et al. (11) some surgeons choose only adrenalectomy, while some add splenectomy or nephrectomy to adrenalectomy. The different surgical procedures are generally determined on the basis of the size and extension of the tumor. Also, post-operative chemotherapy and radiotherapy are chosen on the basis of the exhibited size and metastatic status of the tumor (11). In most cases, the neoplasms were reported to be well circumscribed and invasive, with a solid or cystic appearance (10). In this case, we encountered a highly vascular solid mass infiltrating the surrounding fatty tissue without any metastatic foci. Adrenal cortical carcinoma, pheochromocytoma, metastatic adenocarcinoma, or malignant melanoma should be distinguished from primary adrenal angiosarcoma (10). Benign neoplasms may simulate epithelioid angiosarcomas (10). Coincidence of functioning adrenal adenoma and primary adrenal angiosarcoma should also be considered (7). Endothelium-related markers (CD31, CD34, and Factor VIII antigen) usually aid differential diagnoses of malignant vascular tumors (8). The malignant cells were positively stained for CD31, CD34, and Ki67 (30%) in this case. Therefore, our case was reported as an epithelioid variant of angiosarcoma.

In the literature, only one adrenal angiosarcoma has been reported with a similar size to our case (3). Although angiosarcomas are known to have a very aggressive nature in tumor biology, primary adrenal involvement has a long survival time with complete resection margins (12).

The patient was discharged two days after the operation. Because we had resected the tumor with tumor-free surgical margins and no metastatic foci were found by PET-CT scan, adjuvant chemotherapy was not needed. However, because the tumor mass was resected and had occupied a significant volume in the retroperitoneal cavity, adjuvant radiotherapy was determined to be necessary for the patient.

As this is a very rare entity and knowledge of its biological behavior is limited, patient follow-up was planned to include routine laboratory tests and CT scans to keep us informed regarding the patient's future medical status and possible relapses. During the follow-up period, the patient died due to cardiac insufficiency.

## CONCLUSION

Adrenal tumors may present with right upper abdominal pain. Appropriate radiological imaging techniques and laboratory findings can reveal this high-risk vascular adrenal pathology. Conventional open surgical techniques should not be overlooked when deciding how to treat unexpectedly large adrenal vascular tumors.

**Informed Consent:** Written informed consent was obtained from patient who participated in this study.

**Peer-review:** Externally peer-reviewed.

**Author Contributions:** Concept - G.C.; Design - S.T.; Supervision - Y.B.; Resource - S.D.; Materials -M.Ö.; Data Collection and/or Processing - G.C.; Analysis and/or Interpretation - S.T.; Literature Search - S.D.; Writing Manuscript - S.T.; Critical Reviews - Y.B., M.Ö.

**Conflict of Interest:** The authors have no conflicts of interest to declare.

**Financial Disclosure:** The authors declared that this study has received no financial support.

## REFERENCES

1. Criscuolo M, Valerio J, Gianicolo ME, Gianicolo EA, Portaluri M. A vinyl chloride-exposed worker with an adrenal gland angiosarcoma: a case report. *Ind Health* 2014; 52: 66-70. [\[CrossRef\]](#)
2. Sung JY, Ahn S, Kim SJ, Park YS, Choi YL. Angiosarcoma arising within a long-standing cystic lesion of the adrenal gland: a case report. *J Clin Oncol* 2013; 31: 132-136. [\[CrossRef\]](#)
3. Kedzierski L, Hawrot-Kawecka A, Holecki M, J. Angiosarcoma of the adrenal gland. *Pol Arch Med Wewn* 2013; 123: 502-503.
4. Al-Meshan MK, Katchy KC. An unusual angiosarcoma. A case report. *Med Princ Pract* 2004; 13: 295-297. [\[CrossRef\]](#)
5. Kareti LR, Katilein S, Siew S, Blauvelt A. Angiosarcoma of the adrenal gland. *Arch Pathol Lab Med* 1988; 112: 1163-1165.
6. Hendry S, Forrest C. Epithelioid Angiosarcoma Arising in an Adrenal Cortical Adenoma: A Case Report and Review of the Literature. *Int J Surg Pathol* 2014; 22: 744-748. [\[CrossRef\]](#)
7. Lepoutre-Lussey C, Rousseau A, Al Ghuzlan A, Amar L, Hignette C, Cioffi A, et al. Primary adrenal angiosarcoma and functioning adrenocortical adenoma: an exceptional combined tumor. *Eur J Endocrinol* 2012; 166: 131-135. [\[CrossRef\]](#)
8. Ilias I, Sahdev A, Reznick RH, Grossman AB, Pacak K. The optimal imaging of adrenal tumours: a comparison of different methods. *Endocr Relat Cancer* 2007; 14: 587-599. [\[CrossRef\]](#)
9. Yip L, Tublin ME, Falcone JA, Nordman CR, Stang MT, Ogilvie JB, et al. The adrenal mass: correlation of histopathology with imaging. *Ann Surg Oncol* 2010; 17: 846-852. [\[CrossRef\]](#)
10. María Rodríguez-Pinilla S, Benito-Berlinches A, Ballestin C. Angiosarcoma of Adrenal Gland Report of a Case and Review of the Literature. *Rev Esp Patol* 2002; 35: 227-232.
11. Stavridis S, Mickovski A, Filipovski V, Banev S, Dohcevic S, Levkovski Lj. Epithelioid Angiosarcoma of the Adrenal gland. Report of a Case and Review of the Literature. *Maced J Med Sci*. 2010; 0119.
12. Pasqual E, Bertolissi F, Grimaldi F, Beltrami CA, Scott CA, Bacchetti S, et al. Adrenal angiosarcoma: report of a case. *Surg Today* 2002; 32: 563-565. [\[CrossRef\]](#)