








Spontaneous perforation of pyometra: A rare cause of acute abdomen and sepsis

Şener Balas¹, Kerim Bora Yılmaz¹ , Seray Akçalar Yıldırım², Bilgihan Açıköz³ , İdil Güneş Tatar² , Bahattin Bayar¹, Melih Akıncı¹ , Oskay Kaya¹ 

ABSTRACT

Pyometra, the accumulation of purulent material in the uterine cavity, is a rare gynecological condition whose etiology is impaired drainage of the uterine cavity. It is uncommon in premenopausal age and occurs mainly in older and postmenopausal women. Clinical signs of pyometra are vaginal discharge, postmenopausal bleeding, and lower abdominal pain. An 87-year-old woman was admitted to our emergency department with abdominal pain, fever, and vomiting. The results of physical examination revealed rebound tenderness and muscular rigidity in the lower abdomen. Ultrasonography demonstrated free fluid in the abdomen, and percutaneous aspiration revealed that this fluid was purulent. A computed tomography scan showed a large amount of free fluid in the abdominal cavity and a uterine myoma. The patient underwent emergency laparotomy due to acute abdomen. During the laparotomy, a 2x1 cm perforation was seen at the fundus of the uterus. The patient underwent total abdominal hysterectomy with bilateral salpingo-oophorectomy. A culture of the pus grew *Escherichia coli*. Histopathological examination revealed degenerative uterine myoma with no evidence of malignancy. Pathological results indicated myometrial suppurative inflammation along with neutrophilia and necrosis. Pyometra is a rare event; however, it must be considered when investigating acute abdomen etiology. Because pyometra involves abscess formation, drainage and evacuation of the uterine cavity while leaving a drain in the cavity and dilating the cervical canal is the main treatment protocol. In cases of perforation, hysterectomy is the treatment choice; however, with concomitant diseases in older patients, immediate surgery is related to important morbidity and mortality risks.

Keywords: Acute abdomen, pyometra, sepsis, uterine perforation

ORCID IDs of the authors:

K.B.Y. 0000-0002-5514-4103;
M.A. 0000-0001-8719-6584;
O.K. 0000-0002-1864-896X;
B.A. 0000-0003-4837-8187;
İ.G.T. 0000-0003-2499-4532.

Cite this paper as:

Balas Ş, Yılmaz KB, Akçalar Yıldırım S, Açıköz B, Güneş Tatar İ, Bayar B, et al. Spontaneous perforation of pyometra: A rare cause of acute abdomen and sepsis. Turk J Surg 2018; 34(4): 342-345.

INTRODUCTION

Pyometra, the accumulation of purulent material in the uterine cavity, represents 0.038% of gynecologic admissions; its etiology is impaired drainage of the uterine cavity (1). It is uncommon in premenopausal age and occurs mainly in older and postmenopausal women. The classical clinical signs of pyometra are vaginal discharge, postmenopausal bleeding, and lower abdominal pain (2). The etiology of the uterus perforation is blockage of natural drainage due to stenotic cervix, which results in a degenerative or necrotic change in the pyometra (3, 4). This perforation is related to diffuse peritonitis and causes acute surgical abdomen with free intra-abdominal air.

Herein, we report on a patient presenting with abdominal pain and generalized peritonitis caused by perforation of pyometra without malignancy.

CASE PRESENTATION

An 87-year-old woman was admitted to our emergency department with abdominal pain, fever, and vomiting lasting approximately two days. The patient had a history of diabetes and hypertension, and the patient was immobilized and permanently bedridden for two years due to pelvic trauma and poor general condition. Her gynecological history was unremarkable, and she had no vaginal bleeding or increased discharge. The results of a physical examination revealed rebound tenderness, muscular rigidity in the lower abdomen, and distention. Her body temperature was 38.4 °C, her pulse rate was 112 beats/min, and her blood pressure was 140/70. Laboratory studies on admission demonstrated a white cell count of 5000/mm³ with 83.6% neutrophilia and hemoglobin 11.3. A plain chest x-ray showed no free air under the diaphragm and no intestinal obstruction sign. Ultrasonography demonstrated free fluid at the iliac fossa/pelvis; percutaneous aspiration revealed that this fluid was purulent, with no relationship to gastrointestinal tract perforation or bile fistula.

A computed tomography (CT) scan of the abdomen with intravenous contrast showed a large amount of free fluid in the abdominal cavity and a uterine myoma with a diameter of 77x58 mm (Figure 1a). Computed tomography (CT) with an intravenous injection of contrast material showed an enlarged and distended uterus with a breach at the uterine fundus. A dilated endometrial cavity with hypodense fluid collection was suggestive of pyometra. Due to perforated pyometra, multiple pelvic and intra-abdominal fluid collec-

¹Clinic of General Surgery, Health Science University Dışkapı Yıldırım Beyazıt Research and Training Hospital, Ankara, Turkey

²Clinic of Radiology, Health Science University Dışkapı Yıldırım Beyazıt Research and Training Hospital, Ankara, Turkey

³Clinic of Pathology, Health Science University Dışkapı Yıldırım Beyazıt Research and Training Hospital, Ankara, Turkey

This study presented at the 20th National Surgical Congress, 13-17 April 2016, Antalya, Turkey.

Corresponding Author

Kerim Bora Yılmaz

e-mail: borakerim@yahoo.com

Received: 13.02.2016

Accepted: 06.05.2016

©Copyright 2018

by Turkish Surgical Association

Available online at
turkjsurg.com

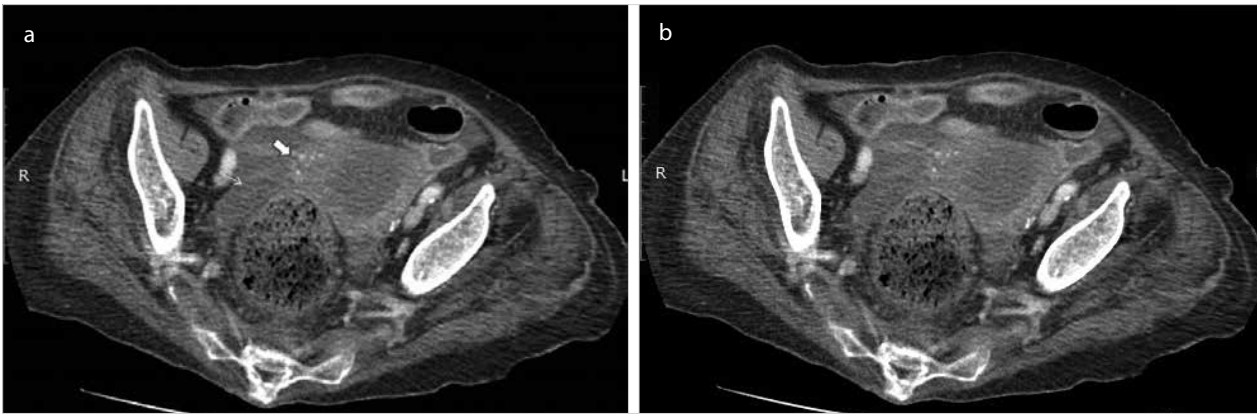


Figure 1. a, b. Axial (solid arrow) (a) and arrow (b) show contrast-enhanced CT images obtained through the midportion of the uterus showing a distended endometrial cavity with perforation at the fundus in the right side (solid arrow), presence of collected fluid within the pelvic cavity (arrow)

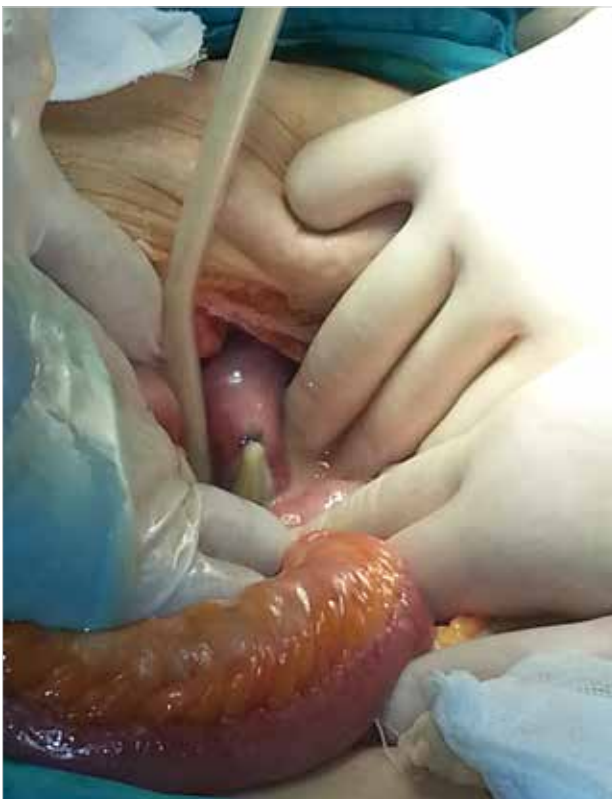

Figure 2. Uterus with perforation on the anterior wall

tions were observed in the CT scan (Figure 1b). The patient underwent emergency laparotomy due to acute abdomen. During the laparotomy, a 2x1 cm perforation was seen at the fundus of the uterus (Figure 2). There was one liter of purulent material in the abdomen. The patient underwent total abdominal hysterectomy with bilateral salpingo-oophorectomy. A culture of the pus grew *Escherichia coli*. Histopathological examination revealed degenerative uterine myoma with no evidence of malignancy. Pathological results indicated myometrial suppurative inflammation with neutrophilia and necrosis (Figure 3). Postoperatively, the patient was monitored in the surgical intensive care unit, as septic shock required inotropic support for five days. The patient had wound problems that required vacuum-assisted closure; after that, she recovered and was discharged at the 28th postoperative day after providing informed consent.

DISCUSSION

Pyometra is a rare event; however, it must be considered when investigating acute abdomen etiology, and emergency physicians must be aware of ruptured pyometra. Although it is a rare condition, it carries morbidity and mortality risks. In the English literature between 1985 and 2015, only 68 cases of pyometra perforation were reported; 38 of these cases did not originate from a malignancy, similar to our report (5). Because of canal stenosis, the uterus enlarges progressively with degenerative changes until the uterine contents finally spill into the abdominal cavity with perforation (6). Pyometra is related to a general etiology of benign or malignant gynecologic tumors, radiation cervicitis, atrophic cervicitis, congenital anomalies, intrauterine devices, and traumatic damage to the cervix (7). If the pyometra is related to malignancy and perforation of the uterus, the prognosis is very poor and bears significant morbidity and mortality risks (8).

In the literature, the median age of ruptured pyometra was 73.8; in geriatric women with concomitant diseases, the mortality rate is 25% to 40% (5, 6, 9). For these septic geriatric patients, emergency conditions and surgery require resuscitation and management of respiration as well as circulation in the intensive care unit and long hospital stays, as in the case of the patient reported in this study. Immunocompromised state has been documented as a high risk for perforation; these patients also have a higher mortality risk (6).

The clinical signs and emergency department admission of pyometra patients are due to acute abdomen. However, a significant percentage of patients with unruptured pyometra are asymptomatic (10). Additionally, due to the nonspecific symptoms associated with rupture, early and accurate diagnosis of perforation is limited. Accurate preoperative diagnoses were obtained for only 21% of ruptured pyometra patients (5). Acute abdomen symptoms such as abdominal pain, vomiting, and fever predominate at admission, while gynecological symptoms such as vaginal bleeding or discharge occur in fewer than 10% of cases (11, 12). The initial diagnosis of the disease can be mistaken as gastrointestinal perforation because of the pneumoperitoneum; however, definitive diagnosis of the disease is sometimes obtained intra-operatively (13). Radiological findings of contrast-enhanced CT are important in diagnosis, along with findings of the presence of fluids in

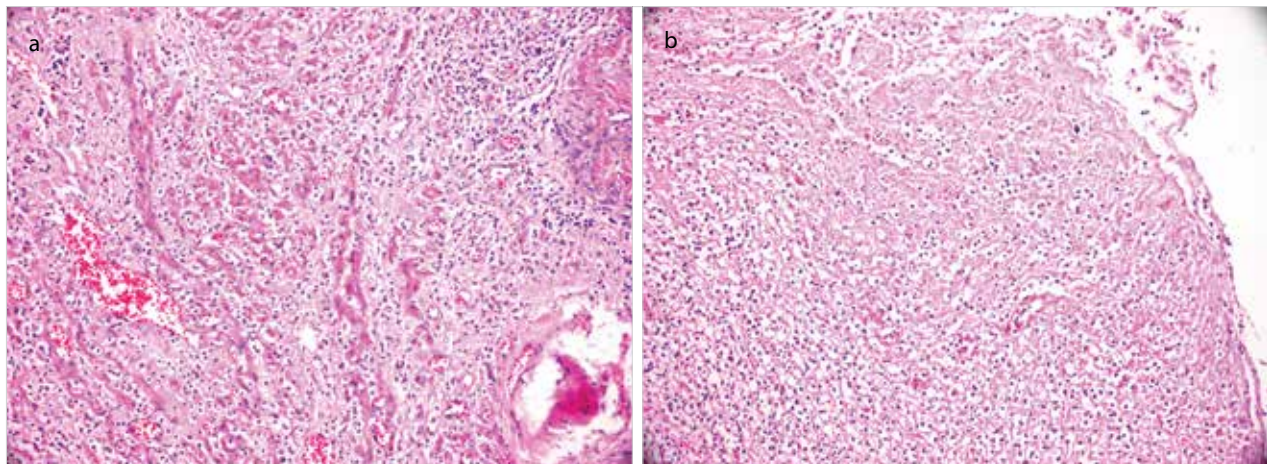


Figure 3. a, b. Pathological results showing myometrial suppurative inflammation with neutrophilia and necrosis

the uterus, defects of the uterine wall, and intraperitoneal fluid collection (14). Free air in the peritoneal cavity and the uterine cavity due to gas-forming organisms are reasons to suspect ruptured pyometra (5). Some reporters illustrate the importance of transvaginal ultrasound to accurate preoperative diagnosis (5, 11). In the absence of gynecological symptoms in most cases, sonography may be adequate to illustrate fluid accumulation in the cavity (11).

Pyometra involves abscess formation; drainage and evacuation of the uterine cavity is the main treatment protocol, along with placing a drain in the cavity and dilating the cervical canal (8, 15). Persistent pyometra requires repeated drainage and dilatation. In cases of perforation, hysterectomy is the treatment choice, with peritoneal lavage and abscess drainage (2). In some reports, the authors suggest management by total abdominal hysterectomy with bilateral salpingo-oophorectomy; however, subtotal or supravaginal hysterectomy, drainage alone, and surgical closure of the perforated uterine wall have been reported in different cases (6, 11).

The pathological results of pyometra are related to the etiology of the disease. Benign tumors, spread of malignance from the endocervix, and endometrial cancer are usually associated with pyometra, and xanthogranulomatous inflammation is also reported in surgical specimens (16, 17). The necrotic nature of the uterine tissue with pyometra sometimes requires frozen section examination.

Treatment of pyometra includes broad spectrum antibiotics against aerobic and anaerobic bacteria. Occasionally, upon microbiological examination, *Escherichia coli*, *Bacteroides fragilis*, *Streptococcus* spp. and *Pseudomonas aeruginosa* are isolated (18, 19). Similar to published reports, in our case, culture of the pus grew *Escherichia coli*; this is the most common infectious agent. Source control with surgery is important in the resuscitation of septic conditions due to peritonitis.

CONCLUSION

Pyometra perforation is a rare cause of acute abdomen. In older patients with concomitant diseases, immediate laparotomy, peritoneal lavage, and hysterectomy are associated with important morbidity and mortality risks. Sepsis, septic shock,

and multiple organ failure may be encountered in clinical presentation due to bacteremia. These acute conditions require intensive care. Accurate and early diagnosis with proper treatment can reduce the mortality and morbidity of pyometra.

Informed Consent: Written informed consent was obtained from patient who participated in this study.

Peer-review: Externally peer-reviewed.

Author Contributions: Concept - Ş.B., K.B.Y., M.A.; Design - O.K., İ.G.T., Ş.B.; Supervision - B.B., O.K., B.A.; Resource - B.B., İ.G.T., B.A.; Materials - K.B.Y., Ş.B., M.A.; Data Collection and/or Processing - B.B., S.A.Y., İ.G.T., B.A.; Analysis and/or Interpretation - Ş.B., O.K., M.A.; Literature Search - K.B.Y., B.B., Ş.B., S.A.Y.; Writing Manuscript - Ş.B., K.B.Y., M.A.; Critical Reviews - O.K., İ.G.T., S.A.Y.

Conflict of Interest: The authors have no conflicts of interest to declare.

Financial Disclosure: The authors declared that this study has received no financial support.

REFERENCES

1. Chan LY, Lau TK, Wong SF, Yuen PM. Pyometra. What is its clinical significance? J Reprod Med 2001; 46: 952-956.
2. Yildizhan B, Uyar E, Şişmanoğlu A, Güllüoğlu G, Kavak ZN. Spontaneous perforation of pyometra. Infect Dis Obstet Gynecol 2006; 2006: 1-3. [\[CrossRef\]](#)
3. Sujatha VV, Babu GS. Spontaneous perforation of uterine pyometra - A case report and review of literature. Apollo Medicine 2013; 10: 248-250. [\[CrossRef\]](#)
4. Chan LY, Yu VS, Ho LC, Lok YH, Hui SK. Spontaneous uterine perforation of pyometra. A report of three cases. J Reprod Med 2000; 45: 857-860.
5. Uno K, Tano S, Yoshihara M, Mayama M, Ukai M, Kishigami Y, et al. A Case Report and Literature Review of Spontaneous Perforation of Pyometra. J Emerg Med 2016; 16: S0736-4679(16)00036-6.
6. Kitai T, Okuno K, Ugaki H, Komoto Y, Fujimi S, Takemura M. Spontaneous uterine perforation of pyometra presenting as acute abdomen. Case Rep Obstet Gynecol 2014; 2014: 738568. [\[CrossRef\]](#)
7. Lien WC, Ong AW, Sun JT, Tsai MT, Lai TI, Liu YP, et al. Pyometra: a potentially lethal differential diagnosis in older women. Am J Emerg Med 2010; 28: 103-105. [\[CrossRef\]](#)
8. Lim SF, Lee SL, Chiow AK, Foo CS, Wong AS, Tan SM. Rare cause of acute surgical abdomen with free intraperitoneal air: Spontaneous perforated pyometra. A report of 2 cases. Am J Case Rep 2012; 13: 55-57. [\[CrossRef\]](#)

9. Ikeda M, Takahashi T, Kurachi H. Spontaneous perforation of pyometra: a report of seven cases and review of the literature. *Gynecol Obstet Invest* 2013; 75: 243-249. [\[CrossRef\]](#)
10. Nuamah NM, Hamaloglu E, Konan A. Spontaneous uterine perforation due to pyometra presenting as acute abdomen. *Int J Gynaecol Obstet* 2006; 92: 145- 146. [\[CrossRef\]](#)
11. Yamada T, Ando N, Shibata N, Suitou M, Takagi H, Matsunami K, et al. Spontaneous perforation of pyometra presenting as acute abdomen and pneumoperitoneum mimicking those of gastrointestinal origin. *Case Rep Surg* 2015; 2015: 548481. [\[CrossRef\]](#)
12. Shapey IM, Nasser T, Dickens P, Haldar M, Solkar MH. Spontaneously perforated pyometra: an unusual cause of acute abdomen and pneumoperitoneum. *Ann R Coll Surg Engl* 2012; 94: 246-248. [\[CrossRef\]](#)
13. Ou YC, Lan KC, Lin H, Tsai CC, Chang Chien CC. Clinical characteristics of perforated pyometra and impending perforation: specific issues in gynecological emergency. *J Obstet Gynaecol Res.* 2010; 36: 661-666. [\[CrossRef\]](#)
14. Izumi J, Hirano H, Yoshioka H, Takisawa J. Computed tomography findings of spontaneous perforation of pyometra. *Jpn J Radiol* 2010; 28: 247-249. [\[CrossRef\]](#)
15. Chuang CJ, Hung YC, Hsieh MC, Hsu CS. Huge asymptomatic pyometra with an intrauterine device. *Taiwan J Obstet Gynecol* 2013; 52: 426- 427. [\[CrossRef\]](#)
16. Liao CY, Chiu CH, Luo FJ. Xanthogranulomatous inflammation of myometrium with uterine perforation. *Taiwan J Obstet Gynecol* 2013; 52: 428- 430. [\[CrossRef\]](#)
17. Babarinsa IA, Campbell OB, Adewole IF. Pyometra complicating cancer of the cervix. *Int J Gynaecol Obstet* 1999; 64: 75-76. [\[CrossRef\]](#)
18. Chao A, Wang AM, Wang TH, Wu TI, Chao AS. An atypical and fatal case of pyometra accompanied by the superficial spread of squamous cell carcinoma of the endometrium and the fallopian tubes. *Taiwan J Obstet Gynecol.* 2013; 52: 440-442. [\[CrossRef\]](#)
19. Tai CC, Lien WC, Wang HP, Liu KL. Early diagnosis of gas-forming pyometra in an aged patient can prevent mortality. *Am J Emerg Med.* 2007; 25: 126-127. [\[CrossRef\]](#)