



# Everolimus induced pneumonitis in a liver transplant patient: Dilemma in the discrimination of pneumonia

Kutay Sağlam<sup>1</sup>, Adem Köse<sup>2</sup>, Murat Yalçınsoy<sup>3</sup>, Yaşar Bayındır<sup>2</sup>, Sezai Yılmaz<sup>1</sup>

<sup>1</sup>Department of General Surgery, İnönü University Faculty of Medicine, Malatya, Türkiye

<sup>2</sup>Department of Infectious Diseases and Clinical Microbiology, İnönü University Faculty of Medicine, Malatya, Türkiye

<sup>3</sup>Department of Pulmonary Diseases, İnönü University Faculty of Medicine, Malatya, Türkiye

## ABSTRACT

Everolimus is one of the immunosuppressive drugs used in solid organ transplantation. Many side effects have been described for these immunosuppressive drugs, similar to other drugs in this category. The purpose of this case presentation is to draw attention to drug-induced pneumonitis, which is a rare and life-threatening side effect of everolimus. A nineteen-year-old female patient who received liver transplantation for toxic hepatitis was admitted to our institute with cough and dyspnea. Everolimus had been started in conjunction with tacrolimus therapy 6 months prior to admission. Her chest imaging were consistent with pneumonitis. Markers of infection and cultures were all negative. After discontinuation of everolimus, symptoms and radiological findings resolved. The adverse effects of the drug should be kept in mind while investigating possible infectious agents in liver transplant recipients who are prone to opportunistic infections.

**Keywords:** Pulmonary, mTOR inhibitors, everolimus

## INTRODUCTION

Everolimus is a mammalian target of rapamycin (mTOR) inhibitor that is an antineoplastic agent which is used as an immunosuppressive agent in solid organ transplantations. It has been commonly used in immunosuppressive therapy for solid organ transplantation. Everolimus is recommended alongside calcineurin inhibitor-based therapies to reduce renal side effects (1). Common side effects are hyperlipidemia, mucosal ulcerations, cytopenia, and impairment of wound healing (2,3). Non-infectious pneumonitis is an uncommon side effect of everolimus in liver transplant recipients. Here, we present a case of a liver transplant recipient with everolimus-induced pneumonitis, which is the fourth case in the literature.

## CASE REPORT

A 19-year-old female liver transplant recipient was admitted to our institute with a cough and shortness of breath that had lasted for three days. Medical history revealed that she had undergone deceased donor liver transplantation for acute liver failure resulting from toxic hepatitis 18 months prior to admission. Everolimus was added as an adjunct to tacrolimus therapy due to an episode of acute cellular rejection six months prior to admission. She was hospitalized because of her respiratory symptoms and immunosuppressive state. Her temperature was 36.6 °C, blood pressure was 110/75 mmHg, heart rate was 105 beats/min, respiratory rate was 26 breaths/min, and oxygen saturation was 89% without oxygen supplementation. She was oriented and in moderate to good clinical condition. She had mild-to-moderate respiratory distress. There were crackles in the basal lobes of both lungs. Other findings of physical examination were unremarkable. Her liver enzymes and bilirubin levels were normal. White blood cell count was  $1.8 \times 10^9/L$ , hemoglobin level was 9.5 g/dL, and platelet count was  $266 \times 10^9/L$ . C-reactive protein and procalcitonin levels were 0.5 mg/dL and 0.05 ng/mL, respectively. While she was taking everolimus and tacrolimus at dosages of 2 mg/day and 4 mg/day, the trough levels were 6.8 ng/mL and 5.8 ng/mL, respectively. Computed tomography of the thorax showed bilateral basal patchy and nodular consolidations with

**Cite this article as:** Sağlam K, Köse A, Yalçınsoy M, Bayındır Y, Yılmaz S. Everolimus induced pneumonitis in a liver transplant patient: Dilemma in the discrimination of pneumonia. *Turk J Surg.* 2025;41(1):105-107

### Corresponding Author

**Kutay Sağlam**

**E-mail:** saglamk@gmail.com

**ORCID ID:** orcid.org/0000-0002-0919-8370

**Received:** 08.11.2021

**Accepted:** 17.01.2022

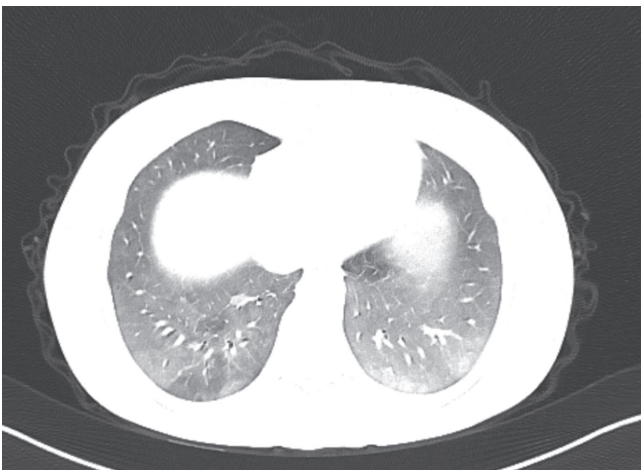
**Publication Date:** 27.02.2025

**DOI:** 10.47717/turkjsurg.2022.5489

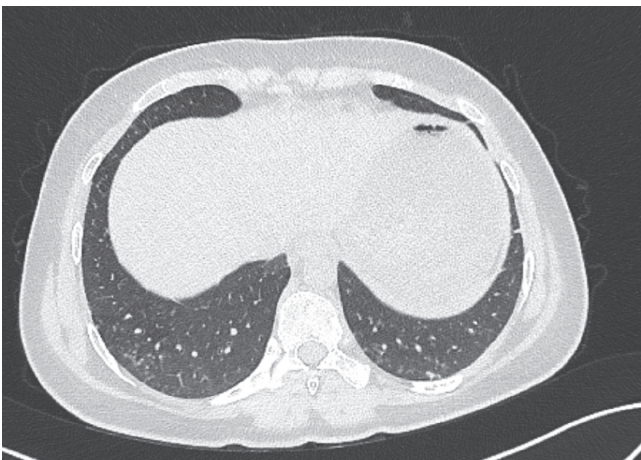
Available at [www.turkjsurg.com](http://www.turkjsurg.com)



diffuse ground-glass opacities (Figure 1a). History, physical examination, and laboratory findings were not compatible with bacterial or fungal infection. A bronchoscopy was performed and bronchoalveolar lavage (BAL) was performed. In the BAL fluid, respiratory panel (syndromic test), polymerase chain reaction for *Aspergillus* spp., and *Mycobacterium tuberculosis*, acid-fast staining and culture for *Mycobacterium tuberculosis* were negative; BAL fluid and blood cultures did not reveal bacterial and fungal infection. Since there was no positive finding for any infectious agents, everolimus treatment was stopped as the first step of our management protocol. Fifteen days after everolimus discontinuation, her symptoms were resolved. Control computed tomography of the thorax showed marked improvement of previous consolidation areas (Figure 1b). No antibiotics or anti-viral treatments were used during this process. The patient recovered spontaneously after discontinuing everolimus treatment. The patient was



**Figure 1a.** Computed tomography showed bilateral basal patchy and nodular consolidations with diffuse ground-glass opacities.



**Figure 1b.** Follow-up thorax computed tomography showed marked improvement of the previous signs of consolidation.

discharged on day 17 with tacrolimus 4 mg/day, following an uneventful recovery.

## DISCUSSION

We report drug induced pneumonitis, which is a rare side effect of everolimus in liver transplantation patients.

Everolimus is an mTOR inhibitor and has antineoplastic properties. In addition to its antineoplastic properties, it is a preferred immunosuppressive agent in solid organ transplantation. Combining with calcineurin inhibitors (CNI) can decrease the side effects of CNI therapy by reducing the dose (1). Incidence of drug-induced pneumonitis in solid organ transplantation caused by sirolimus (another mTOR inhibitor) and everolimus was reported as 16.7% and 0.4%, respectively (4). Drug-induced pneumonitis was commonly reported in heart, kidney, and lung transplants but very rarely in liver transplant recipients. The mechanisms of pulmonary toxicity are unclear. Pulmonary toxicity (pneumonitis or non-infectious pneumonia) was reported in high-dose, antineoplastic therapy (2). However, some studies showed that pulmonary toxicity can occur at low drug levels. Therefore, it was suggested that pulmonary toxicity was not dose-dependent (3). Life-threatening clinical conditions such as alveolar hemorrhage and even mortalities were also reported (5).

The diagnostic criteria for sirolimus-induced pneumonia have been defined by Morelon et al. (6). The symptoms emerged after the drug was started, and the clinical symptoms regress after the drug cessation, which makes up the main components of the diagnostic criteria. The other important point was the exclusion of the infectious etiology. Pneumonia can emerge within two to six months after the first dosage, or up to 6 years after initiation of everolimus therapy (2,5,7). Common symptoms of these patients are shortness of breath and coughing (2). Laboratory findings are usually non-specific and infection markers are usually negative (5). Blood, sputum, and BAL cultures were negative, and common infectious microorganisms, including opportunistic agents, should be considered excluded. Thorax computed tomography was usually preferred in the diagnosis (4). Bilateral pulmonary infiltration on imaging modalities is common among all cases. There is no consensus on the management of these patients. Discontinuation of everolimus is the main therapeutic approach. Corticosteroids were recommended in some reports depending on the severity of the disease (5). Pulmonary symptoms resolved in one and three months after stopping everolimus in the reported two cases (3,8). In our patient, pulmonary symptoms started to regress on the 15<sup>th</sup> day, after discontinuation of everolimus treatment. It is a matter of debate whether or not we have taken risks by not starting empirical antimicrobial therapy in our patient who was immunosuppressed.

In conclusion, it is well-known that transplant recipients are prone to opportunistic infections. However, the adverse effects of the drugs should not be underestimated.

#### Ethics

**Informed Consent:** Informed consent was obtained.

#### Footnotes

#### Author Contributions

Concept - K.S.; Design - K.S.; Supervision - S.Y., Y.B.; Data Collection or Processing - K.S.; Analysis or Interpretation - A.K., M.Y.; Literature Search - K.S.; Critical Review - S.Y.; Writing - K.S., Y.B.

**Conflict of Interest:** No conflict of interest was declared by the authors.

**Financial Disclosure:** The authors declared that this study received no financial support.

#### REFERENCES

1. Arunachalam A, Ali SR, Wakefield BJ, Lane CR, Mehta AC. Everolimus induced pneumonitis in a lung transplant recipient. *Oxf Med Case Reports*. 2018 24;2018:omy008.
2. Kaplan B, Qazi Y, Wellen JR. Strategies for the management of adverse events associated with mTOR inhibitors. *Transplant Rev (Orlando)*. 2014;28:126-133.
3. Schrader J, Sterneck M, Klose H, Lohse AW, Nashan B, Fischer L. Everolimus-induced pneumonitis: report of the first case in a liver transplant recipient and review of treatment options. *Transpl Int*. 2010;23:110-113.
4. Lopez P, Kohler S, Dimri S. Interstitial lung disease associated with mTOR inhibitors in solid organ transplant recipients: Results from a large phase III clinical trial program of everolimus and review of the literature. *J Transplant*. 2014;2014:305931.
5. Almeida F, Amorim S, Sarmiento A, Santos L. Life-threatening everolimus-associated pneumonitis: A case report and a review of the literature. *Transplant Proc*. 2018;50:933-938.
6. Morelon E, Stern M, Israël-Biet D, Correas JM, Danel C, Mamzer-Bruneel MF, et al. Characteristics of sirolimus-associated interstitial pneumonitis in renal transplant patients. *Transplantation*. 2001;15;72:787-790.
7. Porta C, Osanto S, Ravaud A, Climent MA, Vaishampayan U, White DA, et al. Management of adverse events associated with the use of everolimus in patients with advanced renal cell carcinoma. *Eur J Cancer*. 2011;47:1287-1298.
8. Siddiqui AS, Zimmerman JL. Everolimus associated interstitial pneumonitis in a liver transplant patient. *Respir Med Case Rep*. 2016;19:15-17.