



# Primary pancreatic hydatid disease: A rare presentation of echinococcosis

Mehmet Köstek<sup>1</sup> , Özgür Bostancı<sup>1</sup> , Muharrem Battal<sup>1</sup> , Hüseyin Alkim<sup>2</sup> 

<sup>1</sup> Clinic of General Surgery, Şişli Hamidiye Etfal Research and Education Hospital, Health Sciences University, İstanbul, Türkiye

<sup>2</sup> Clinic of Gastroenterology, Şişli Hamidiye Etfal Research and Education Hospital, Health Sciences University, İstanbul, Türkiye

## ABSTRACT

Hydatid disease is a zoonotic parasitic disease which rarely involves pancreas primarily. Diagnosis of pancreatic hydatid cyst is a challenge and operative skills are important to avoid spillage of cyst's content. A 19-year-old male patient was admitted to hospital with recurrent abdominal pain which was on epigastrium and left upper quadrant of abdomen. Pain was not associated with nausea, vomiting or fever. An abdominal computed tomography (CT) scan was ordered. As a result of abdominal CT scan, there was a cystic area in tail of pancreas with a diameter of 5.6 cm which includes septa and there was calcification on borders of the cyst. Possible diagnosis were either pancreatic hydatid disease, pancreatic cyst adenoma or cystadenocarcinoma or pseudocyst of autoimmune pancreatitis. Whole body positron emission tomography (PET-CT) scan showed no other cyst or lesion other than pancreatic cyst. Hydatid disease indirect hemagglutination test has been studied and it was positive. Imaging studies and laboratory results were suggested hydatid disease and laparoscopic distal pancreatectomy has been applied. Primary pancreatic hydatid disease should be in differential diagnosis when newly appearing pancreatic cyst has been diagnosed, especially in endemic areas. Appropriate surgical technique has to be applied to avoid dissemination of cyst's content.

**Keywords:** Echinococcosis, hydatid disease, pancreas, pancreatectomy, laparoscopy

## INTRODUCTION

Hydatid disease is a zoonotic parasitic disease which is endemic in countries raising farm animals like Middle Eastern countries, India, New Zealand, Australia, Türkiye and South Europe (1,2). Hydatid disease can involve with many organ but effects liver in 70% of patients and lungs in 20% of patients. This disease also effects muscles, bones, brain and spleen (1,3). This disease primarily involves pancreas very rarely and in literature 0.2-2% of all hydatid diseases were reported as primary pancreatic hydatid disease (4,5).

Diagnosis of a pancreatic hydatid cyst is a real diagnostic challenge. Final diagnosis can only be made during or after surgery but imaging and laboratory studies can help making diagnosis before surgery. A suspicion of pancreatic hydatid cyst is important preoperatively and surgical operation without spillage of cyst's contents is a must.

## CASE REPORT

Nineteen-years-old male patient was admitted to hospital with recurrent abdominal pain. Pain was located in the epigastrium and left upper quadrant of abdomen and it was not associated with nausea, vomiting or fever. There was no relationship with food and not relieved with antacids. There was a tenderness on left upper quadrant. The patient had no history of previous abdominal operation. His vitals were stable and laboratory tests and abdominal CT scan were ordered.

Laboratory test results were completely in normal limits including white blood cell counts, serum CRP, amylase and lipase counts. In abdominal CT scan, there was a cystic area in tail of pancreas with a diameter of 5.6 cm which includes septa and there were calcifications on borders of the cyst (Figure 1). Pancreatic tail was replaced by the cysts. Pancreas head and body were normal. There was no lesions on liver, spleen and kidneys. There was no involvement of major artery and veins.

**Cite this article as:** Köstek M, Bostancı Ö, Battal M, Alkim H. Primary pancreatic hydatid disease: A rare presentation of echinococcosis. Turk J Surg 2023; 39 (4): 383-386

### Corresponding Author

Mehmet Köstek

E-mail: dr.mkostek@gmail.com

Received: 19.03.2020

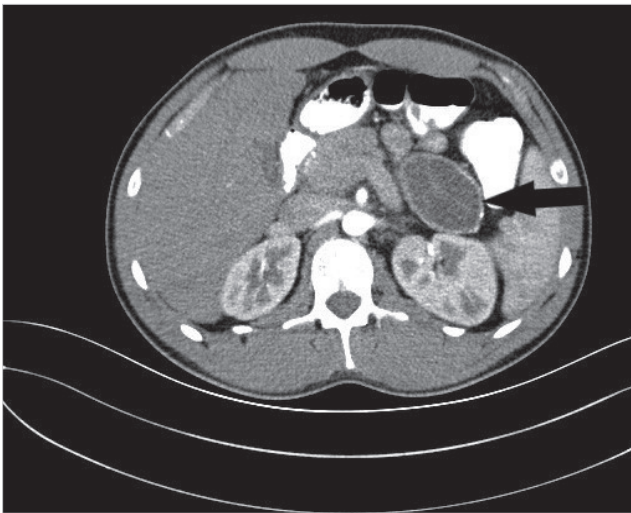
Accepted: 12.05.2020

Available Online Date: 29.12.2023

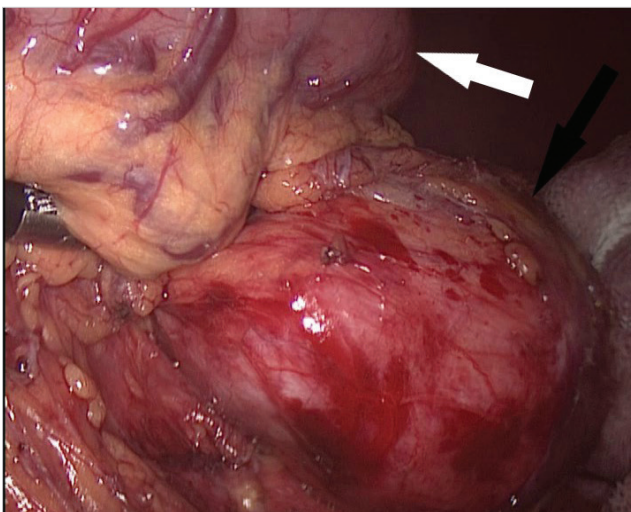
© Copyright 2023 by Turkish Surgical Society Available online at [www.turkjsurg.com](http://www.turkjsurg.com)

DOI: 10.47717/turkjsurg.2023.4768

Possible diagnosis were either pancreatic hydatid disease, pancreatic cyst adenoma or cystadenocarcinoma or pseudocyst of autoimmune pancreatitis. To make a differential diagnosis, immunoglobulin G subtypes have been studied and only IgG2 was higher than normal limits. Hydatid disease indirect hemagglutination test has been studied and it was positive. Endoscopic ultrasound imaging has been applied. It showed that a 3.4 cm x 4.1 cm cyst with septa located at the pancreatic body and there was no normal pancreatic tissue at the body localization due to compression. It also showed cysts at the tail portion of the pancreas but it couldn't be measured and pancreatic duct was dilated. PET-CT scan was ordered for metabolic characterization of the cysts and whole body scan. It showed no lesions other than cysts in pancreas. There was no significant FDG up-



**Figure 1.** An image from computed tomography scan of patient. Black arrow represents pancreatic hydatid cyst.



**Figure 2.** Intraoperative appearance of pancreatic hydatid cyst. Black arrow represents pancreatic hydatid cyst, white arrow represents stomach.

take. At the pancreatic tail, a centrally hypodense cyst which were measured 63 mm x 35 mm and were including septa has been observed.

Imaging studies and laboratory results were suggested hydatid disease and surgical operation was planned for this patient. Spleen preserving laparoscopic distal pancreatectomy has been performed (Figure 2). In total of 4 trocars (1 x 15 mm, 1 x 12 mm, 2 x 5 mm ports) have been used for operation. Twelve mm trocar was placed on umbilicus for the camera and 15 mm trocar was placed from 5 cm left superiolateral site. Right 5 mm trocar was placed from 5 cm right superiolateral to the umbilical port and left 5 mm port placed more left superiolateral to the 15 mm trocar. Fifteen mm trocar was used for entrance of laparoscopic stapling device. Operation time was 185 minutes and estimated blood loss was approximately 120 mL. Excised material has been taken out after widening of 15 mm trocar entrance site. An specimen retrieval bag was used and serious care was taken during this removal process to avoid spillage of cyst content.

There was no complications during admission and patient discharged fifth day postoperatively. Albendazole therapy (800 mg/day) was started after surgery for three months. After analysis of specimen in the pathology department, diagnosis of the patient was concluded with pancreatic hydatid cyst and eosinophil-rich mixed type moderate inflammatory cell infiltration at the cyst wall. At the end of one year of follow-up, patient has no complaint or complications of surgery.

## DISCUSSION

Primary pancreatic hydatid disease is a very rare entity constituting only 0.2-2% of all cases of hydatid disease (4,5). Hydatid disease involves liver and lung in 90% of all cases (1,3). Primary involvement of pancreas with hydatid disease is an unexpected diagnosis for most physicians. Primary pancreatic hydatid cysts are mostly seen in the head (57%), body (24%) and tail (19%) (1-3,6). In this case hydatid cyst was located in the tail and it replaced pancreatic tissue.

*Echinococcus granulosus* is acquired through oral route and it can be spread to the pancreas mainly with hematogenous pathway, and it also uses peripancreatic lymphatic pathway, retroperitoneal and pancreatobiliary pathway (2,7,8).

Clinical presentation can be different from each other based on size and location of hydatid cyst inside of the pancreas in addition to pancreatic canal involvement (1-3,6-8). Cysts that located in the head of pancreas may cause jaundice, cholangitis and pancreatitis but cysts are located in body and tail may be more silent and they can grow slowly until they cause symptoms (fullness, early satiety, abdominal discomfort and pain) or complications (6,7). Complications of pancreatic hydatid disease may be rupture, biliary or intestinal fistula, segmental portal hypertension, vascular thrombosis, acute or chronic pancreatitis (1-3,5-8).

In this case, patient has a cyst in the tail of pancreas and cyst hadn't been noticed unless it started to cause pain.

Pancreatic cysts have a wide range of differential diagnosis. Diagnosis of primary pancreatic hydatid disease is mostly with imaging studies but being suspicious especially in endemic countries can change the surgical approach to the cysts (1,8). Gold standard diagnostic test is histopathologic examination postoperatively (9). Cysts has to be excised or aspirated without spreading protoscolices inside abdomen. Dissemination of hydatid cyst contents inside of body can cause anaphylaxis and recurrences. CT scan, MR imaging, PET-CT or USG can help with diagnosis but none of them satisfactory. CT scan that shows an rounded cystic lesions with curvilinear calcification, indulating membrane, multiple degenerating daughter cyst inside of mother cyst can help with diagnosis of hydatid disease. CT scan also can help with the evaluation of the complications of hydatid disease such as pancreatitis and opening of the hydatid cyst to the pancreatic canal. USG can show multi vesicular cysts, limited by a clean wall, contains daughter cysts and peripheral calcifications (1-3,7). T2 weighted MR images show distinctive low intensity rim of hydatid cyst (10). Various serological test can be used if there is clinical suspicion of hydatid disease. Enzyme linked immuno-absorbent assay gives positive result in 85% of hydatid disease (2,8). Serum immunoelectrophoresis, complement fixation test, immunofluorescence assay and indirect hemagglutination test can be used. In this case, CT scan helped to include hydatid disease as a differential diagnosis. Indirect hemagglutination test was used and it was positive. This result increased our suspicion for primary pancreas hydatid disease.

Surgery is the main choice of treatment of hydatid disease. Complete excision of cyst or distal pancreatectomy can be applied if hydatid cyst is located at the tail of pancreas. In lesions that located at the head of the pancreas partial cystectomy or pericystectomy can be applied. Before excision of the cyst, injection of scolical material is important to decrease the risk of spreading protoscolices to the abdomen. Careful aspiration of the cavity is crucial. Omentoplasty can be applied after cleaning inside of the cavity (2,3). In this case, laparoscopic distal pancreatectomy had been applied. During laparoscopic technique, excision or suction of the cyst must be careful to prevent spillage of the content. Preoperative and postoperative use of albendazole can help prevent recurrences but it is not enough alone (2,8). A good surgical technique is essential.

## CONCLUSION

Primary pancreatic hydatid disease is a rarity and differential diagnosis of this disease is a clinical challenge. Especially in

endemic areas, hydatid disease of pancreas should be kept in mind when a pancreatic cyst is seen.

## Acknowledgment

Authors declare that they have no competing interests. An informed consent was taken from the patient.

**Peer-review:** Externally peer-reviewed.

**Author Contributions:** Concept - All of authors; Design - All of authors; Supervision - All of authors; Materials - All of authors; Data Collection and/or Processing - All of authors; Analysis and/or Interpretation - All of authors; Literature Search - All of authors; Writing Manuscript - All of authors; Critical Reviews - All of authors.

**Conflict of Interest:** The authors have no conflicts of interest to declare.

**Financial Disclosure:** The authors declared that this study has received no financial support.

## REFERENCES

1. *Alsaid B, Alhimyar M, Rayya F. Pancreatic hydatid cyst causing acute pancreatitis: A case report and literature review. J Case Rep Surg 2018; 2018: 9821403. <https://doi.org/10.1155/2018/9821403>*
2. *Suryawanshi P, Khan AQ, Jathal S. Primary hydatid cyst of pancreas with acute pancreatitis. Int J Surg Case 2011; 2(6): 122-4 <https://doi.org/10.1016/j.ijscr.2011.02.011>*
3. *Makni A, Jouini M, Kacem M, Safta Z. Acute pancreatitis due to pancreatic hydatid cyst: A case report and review of the literature. World J Emerg Surg 2012; 7(1): 7. <https://doi.org/10.1186/1749-7922-7-7>*
4. *Dziri C, Dougaz W, Bouasker I. Surgery of the pancreatic cystic echinococcosis: Systematic review. Transl Gastroenterol Hepatol 2017; 2: 105. <https://doi.org/10.21037/tgh.2017.11.13>*
5. *Akbulut S, Yavuz R, Söğütçü N, Kaya B, Hatipoğlu S, Şenol A, et al. Hydatid cyst of the pancreas: Report of an undiagnosed case of pancreatic hydatid cyst and brief literature review. World J Gastroint Surg 2014; 6(10): 190-200. <https://doi.org/10.4240/wjgs.v6.i10.190>*
6. *Canbak T, Acar A, Kıvanç AE, Başak F, Kulalı F, Baş G. Sinistral portal hypertension due to pancreatic hydatid cyst. Türkiye Parazitoloj Derg 2017; 41: 226-8. <https://doi.org/10.5152/tpd.2017.4899>*
7. *Faraj W, Francesca S, Khalifeh M, Jamali F. Laparoscopic resection of pancreatic hydatid disease. Surgery 2006; 139(3): 438-41. <https://doi.org/10.1016/j.surg.2005.10.004>*
8. *Chinya A, Khanolkar A, Kumar J, Sinha S. Isolated hydatid cyst of the pancreas masquerading as pancreatic pseudocyst. BMJ Case Rep 2015; 2015: bcr2015211307. <https://doi.org/10.1136/bcr-2015-211307>*
9. *Hiremath B, Subramaniam N, Boggavarapu M. Primary pancreatic hydatid cyst: An unexpected differential diagnosis. BMJ Case Rep 2015; 2015: bcr2015211377 <https://doi.org/10.1136/bcr-2015-211377>*
10. *Ilıc A, Kocaoğlu M, Zeybek N, Güven S, Adaletli I, Başgöl A, et al. Extrahepatic abdominal hydatid disease caused by Echinococcus granulosus: Imaging findings. AJR Am J Roentgenol 2007; 189(2): 337-43. <https://doi.org/10.2214/AJR.07.2255>*

**OLGU SUNUMU-ÖZET**

Turk J Surg 2023; 39 (4): 383-386

**Pankreasın primer hidatik hastalığı: Ekinokozun nadir bir türü**Mehmet Köstek<sup>1</sup>, Özgür Bostancı<sup>1</sup>, Muharrem Battal<sup>1</sup>, Hüseyin Alkım<sup>2</sup><sup>1</sup> Sağlık Bilimleri Üniversitesi, Şişli Hamidiye Etfal Eğitim ve Araştırma Hastanesi, Genel Cerrahi Kliniği, İstanbul, Türkiye<sup>2</sup> Sağlık Bilimleri Üniversitesi, Şişli Hamidiye Etfal Eğitim ve Araştırma Hastanesi, Gastroenteroloji Kliniği, İstanbul, Türkiye**ÖZET**

Hidatik hastalık, nadiren primer olarak pankreası tutan zoonotik parazitik bir hastalıktır. Pankreatik hidatik kistin tanısının konulması klinisyeni zorlamakta ve kist içeriği yayılmadan operasyonun tamamlanması için cerrahi beceri önem taşımaktadır. On dokuz yaşında erkek hasta epigastri-umda ve karın sol üst kadranda olan tekrarlayıcı karın ağrısı ile hastanemize başvurdu. Ağrının bulantı, kusma ve ateşle ilişkisi yoktu. Çekilen tüm batin bilgisayarlı tomografisinde, pankreas kuyruk kesiminde içerisinde septaların ve sınırlarında kalsifikasyonların bulunduğu 5,6 cm çapında kistik bir yapı görüldü. Ayırıcı tanıda, pankreatik hidatik hastalık, pankreas kistadenomu, kistadenosarkomu veya otoimmün pankreatite sekonder oluşmuş olabilecek psödokist mevcuttu. Tüm vücut fluorodeoksiglukoz pozitron emisyon tomografisinde pankreas kisti dışında herhangi başka bir kist ya da lezyon görülmedi. Hidatik hastalık için yapılan indirekt hemaglutinasyon testi pozitif sonuçlandı. Görüntüleme ve laboratuvar sonuçları hidatik hastalık ile uyumluydu ve hastaya laparoskopik distal pankreatektomi uygulandı. Yeni oluşmuş pankreatik kisti bulunan hastalarda, özellikle endemik bölgelerde, primer pankreatik hidatik hastalık ayırıcı tanıda bulunmalıdır. Kistin içeriğinin batına yayılmadan uygun cerrahinin yapılması büyük önem taşımaktadır.

**Anahtar Kelimeler:** Ekinokoz, hidatik hastalık, pankreas, pankreatektomi, laparoskopi**DOI:** 10.47717/turkjsurg.2023.4768