











Level I axillary dissection in patients with breast cancer and tumor-involved sentinel lymph node after NAC is not sufficient for adequate nodal staging

Jan Žatecký¹⁻³ , Oldřich Coufal^{1,4} , Miloš Holánek^{5,6} , Otakar Kubala^{7,8} , Markéta Kepičová⁸ , Jiří Gatěk⁹ , Milan Lerch³ ,
Matúš Peteja^{2,3} 

¹ Department of Surgical Oncology, Masaryk Memorial Cancer Institute, Brno, Czech Republic

² The Institute of Paramedical Health Studies, Silesian University, Opava, Czech Republic

³ Department of Surgery, Silesian Hospital in Opava, Opava, Czech Republic

⁴ Department of Surgical Oncology, Masaryk University, Brno, Czech Republic

⁵ Department of Comprehensive Cancer Care, Masaryk Memorial Cancer Institute, Brno, Czech Republic

⁶ Department of Comprehensive Cancer Care, Masaryk University, Brno, Czech Republic

⁷ Department of Surgical Studies, University of Ostrava, Ostrava, Czech Republic

⁸ Department of Surgery, University Hospital Ostrava, Ostrava, Czech Republic

⁹ Department of Surgery, EUC Clinic Zlín, Zlín, Czech Republic

ABSTRACT

Objective: The purpose of the study was to investigate the oncological sufficiency of level I axillary dissection for adequate histological nodal staging (ypN) in patients with breast cancer and tumor-involved sentinel lymph node (SLN) after neoadjuvant chemotherapy (NAC).

Material and Methods: A prospective multicentre pilot study took place from 01.01.2018 to 30.11.2020 in three mammary centres in the Czech Republic in patients with breast cancer after NAC (NCT03556397). Patients in the cohort with positive histological frozen section of SLN were indicated to separate axillary dissection of levels I and II.

Results: Sixty-one patients with breast cancer after NAC were included in the study according to inclusion and exclusion criteria. Twelve patients with breast cancer and tumour involved SLN after NAC were further included in the analysis. Two (16.7%) patients had positive non-sentinel lymph nodes in level I only, one (8.3%) patient had positive lymph nodes in level II only, and seven (58.3%) patients had positive lymph nodes in both levels. Level I axillary dissection in a patient with tumour involved SLN after NAC would have resulted in understaging in five (41.7%) patients, mostly ypN1 instead of ypN2.

Conclusion: According to our pilot result, level I axillary dissection is not sufficient in terms of adequate histological nodal staging in breast cancer patients after NAC, and level II axillary dissection should not be omitted.

Keywords: Breast cancer, sentinel lymph node biopsy, neoadjuvant chemotherapy, axillary dissection, level I axillary dissection

INTRODUCTION

Implementation of neoadjuvant chemotherapy (NAC) in patients with breast cancer has brought new questions to axillary surgery. Changes in guidelines have allowed the use of less radical operations such as sentinel lymph node biopsy (SLNB) or targeted axillary dissection (TAD) instead of standard axillary dissection of levels I and II (ALND) even in patients with initially tumor infiltrated lymph nodes with regression after NAC (1-6). Less radical surgical methods have a lower incidence of complications such as seroma formation, lymphoedema, limitations of arm movement, loss of sensitivity. The complication rate of SLNB is significantly lower with 5% compared with up to 58.4% for ALND (7,8). However, in patients with residual nodal disease after NAC detected by SLNB or TAD, completion ALND of levels I and II still represents the standard procedure (1,9).

Correct histological nodal status after NAC is a determinant of long-term prognosis (10). The prognostic value of residual lymph node involvement may differ among breast cancer subtypes (11), and the number of metastatic lymph nodes can influence the decision about adjuvant systemic therapy (9). It could potentially also affect the indication of adjuvant radiotherapy (12).

Cite this article as: Žatecký J, Coufal O, Holánek M, Kubala O, Kepičová M, Gatěk J, et al. Level I axillary dissection in patients with breast cancer and tumor-involved sentinel lymph node after NAC is not sufficient for adequate nodal staging. Turk J Surg 2023; 39 (1): 1-6.

Corresponding Author

Jan Žatecký

E-mail: janzatecky.jz@gmail.com

Received: 09.12.2022

Accepted: 29.01.2023

Available Online Date: 03.03.2023

© Copyright 2023 by Turkish Surgical Society Available online at www.turkjsurg.com

DOI: 10.47717/turkjsurg.2023.5984

According to the recommendation of TNM Classification, adequate pathological nodal staging requires the resection and examination of at least low axillary lymph nodes (level I) with a minimum of six lymph nodes (13). It can be assumed that with a lower number of removed lymph nodes lower complication rate should occur (8), therefore the complication rate of level I axillary dissection should range between the complication rate of the standard level I and II axillary dissection and SLNB, but there are no studies on this topic in the literature.

This prospective pilot study investigated the sufficiency of axillary dissection of level I for adequate histological nodal staging (ypN) in patients with tumor-involved sentinel lymph nodes after NAC.

MATERIAL and METHODS

The presented analysis was one of the primary endpoints of the study "Sentinel Lymph Node Biopsy in Patients with Breast Cancer After Neoadjuvant Therapy." The study was designed as a prospective multicenter pilot trial and was conducted from 01.01.2018 to 30.11.2020 in three surgical departments specializing in breast cancer surgery (Silesian Hospital in Opava, University Hospital Ostrava, EUC Clinic Zlin). Inclusion criteria were diagnosis of breast carcinoma confirmed by biopsy, the indication of neoadjuvant chemotherapy, examination of axillary lymph nodes clinically and by ultrasound and surgical treatment after neoadjuvant chemotherapy. Exclusion criteria were incomplete neoadjuvant chemotherapy, inflammatory breast cancer, and the presence of distant metastases. Axillary nodal status before NAC was examined clinically, by ultrasound and in case of suspicious pathological lymph node by core-cut biopsy. Patients were informed about the suggested treatment and signed informed consent. The study was approved by the Ethics Committee of Faculty of Medicine, University of Ostrava, and by local ethics committees in each center. The study was registered on www.clinicaltrials.gov with code NCT03556397.

Patients included in the presented sub-analysis were patients with tumour involved SLN according to the histological frozen section in the form of micrometastases, micrometastases or isolated tumour cells (ITC) and separate axillary dissection of levels I and II (Figure 1).

Lymphatic mapping was performed by scintigraphy and patent blue. Sentinel lymph nodes were detected by gamma probe and visually tracked according to lymph vessels' blue coloring. Frozen section and definitive histological examination with immunohistochemical evaluation of the sentinel lymph node were performed. In case of finding tumor cells in perioperative frozen section of the sentinel lymph node, axillary dissection of levels I and II was further performed in each patient with perioperative in vivo division of levels and separate histological examination. Level I axillary lymph nodes were defined as lymph nodes below and laterally from the lateral edge of the

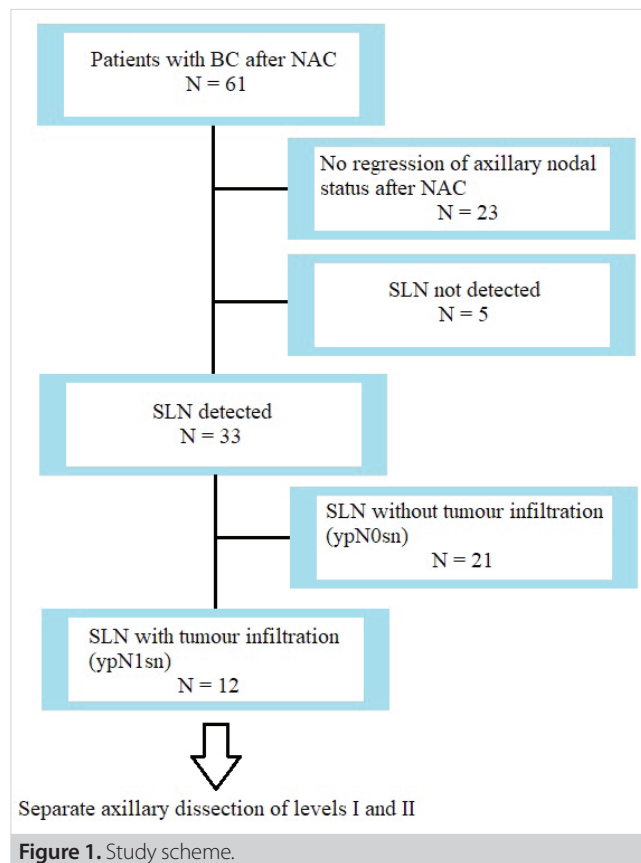


Figure 1. Study scheme.

pectoralis minor muscle, level II axillary lymph nodes as lymph nodes located behind the pectoralis minor muscle. Histological nodal status of axillary lymph nodes after NAC was classified according to the 8th edition of TNM Classification to ypN1 (under three tumor infiltrated lymph nodes), ypN2 (4-9 tumor infiltrated lymph nodes) and ypN3 (more than 10 tumor infiltrated lymph nodes).

Recorded patient and tumor characteristics included age, TNM classification, tumor typing and grading, the positivity of estrogen receptors (ER), progesterone receptors (PR) and HER2 receptors, type of surgery, type of tracer used for SLNB, number of harvested sentinel and non-sentinel lymph nodes, histological examination of lymph nodes. Mean values, percentages, and ranges were calculated.

RESULTS

Sixty-one patients with breast cancer after NAC were included in the study according to inclusion and exclusion criteria. The average age was 48.7 years, the stage of the primary tumor according to TNM classification was T1 in 13 (21.3%) patients, T2 in 33 (54.1%) patients, T3 in 10 (16.4%) patients and T4 in five (8.2%) patients. Axillary nodal status before NAC was N0 in 12 (19.7%) patients, N1 in 44 (72.1%) patients, N2 in two (3.3%) patients and N3 in three (4.9%) patients. Tumor types were

invasive carcinoma of no special type (NST) in 51 (83.6%) patients, invasive lobular carcinoma in six (9.8%) patients, medullary carcinoma in three (4.9%) patients and mucinous carcinoma in one (1.6%) patient. Tumor grade was G1 in four (6.6%) patients, G2 in 34 (55.7%) patients and G3 in 23 (37.7%) patients. According to molecular classification of breast tumours, the most common was triple-negative breast cancer (patients 20, 32.8%), luminal B was present in 18 (29.5%) patients, HER2+ in 16 (26.2%) patients, and luminal A in seven patients (11.5%).

Twelve patients with breast cancer and tumor involved SLN after NAC were further included in the analysis. The average age in the cohort was 52.1 years, with a minimum of 33 and a maximum of 77 years. The stage of the primary tumor was T1 in three (25.0%) patients, T2 in seven (58.3%) patients and T3 in two (16.7%) patients. Axillary nodal status before NAC was N0 (16.7%) in one (8.3%) patient, N1 in seven patients (58.3%), N2 in two patients and N3 in two (16.7%) patients. The regression of axillary nodal burden after NAC was confirmed by clinical examination and USG in all patients in the analysis. The most common breast tumor type was invasive carcinoma of NST in eight (66.7%) cases, four (33.3%) patients had invasive lobular carcinoma. Breast conserving surgery was performed in one patient; in 11 patients, mastectomy was performed. The other patient characteristics are summarized in Table 1.

In seven cases, two tracers were used to detect sentinel lymph nodes-scintigraphy and patent blue, in other cases single tracer

was used. The average number of harvested sentinel lymph nodes was 1.5, with a minimum one and maximum six nodes. Perioperative and definitive histological findings in SLNs are summarized in Table 2.

In two (16.7%) patients, no tumor infiltrated non-sentinel levels I and II axillary lymph nodes were present. In two (16.7%) patients, tumor infiltrated non-sentinel lymph nodes were only found in level I axillary nodes. Levels I and II axillary lymph nodes infiltrated by tumor were present in seven (58.3%) patients (Table 2). Tumor infiltration of level II axillary lymph nodes only was present in one (8.3%) patient.

Performing level I axillary dissection would have only resulted in leaving tumour infiltrated lymph nodes in the axilla in eight (66.7%) patients. With the axillary dissection of levels I and II, upstaging of the pathological nodal status from ypN1 to ypN2 or from ypN2 to ypN3 occurred in five (41.7%) patients (Table 2).

DISCUSSION

The number of breast cancer patients after NAC has increased in the last decade (14), so questions about axillary staging in this subgroup are very topical. The primary outcome of our analysis was to evaluate the possibility of performing axillary dissection of level I only in patients with tumor involved sentinel lymph node after NAC without risk of understaging the axillary nodal status. To our knowledge, this is a first study focusing on the sufficiency of level I axillary dissection in breast cancer patients after NAC for staging purposes.

According to the 8th edition of TNM classification, axillary dissection of level I axillary lymph nodes can be performed with the condition of harvesting a minimum of six lymph nodes for adequate histological nodal staging (13). Five patients in the study achieved the number of lymph nodes in level I with six or more, other patients had a lower number of lymph nodes. On the other hand, TNM classification also states that one of the essential prognostic factors in breast cancer is the number and percentage of tumor infiltrated lymph nodes (13). In eight (66.7%) patients, other tumour infiltrated lymph nodes were found in level II of axillary lymph nodes, moreover, in five (41.7%) patients, an understaging would have occurred if only level I axillary dissection had been performed. According to the study results, the recommendation of TNM Classification about the axillary dissection of level I should not be interpreted as sufficient for adequate nodal staging.

Knowledge of the exact extent of nodal involvement in the axilla is key to determining optimal adjuvant treatment options. In patients with luminal A and luminal B breast cancer subtypes, the exact extent of nodal involvement may determine whether or not adjuvant chemotherapy is necessary (13). Patients with luminal B breast cancer at high risk of recurrence (involvement of four or more nodes, or one to three nodes and

Table 1. Patient characteristics

Characteristic	Value	n (%)
T stage	T1	3 (25.0%)
	T2	7 (58.3%)
	T3	2 (16.7%)
N stage	N0	1 (8.3%)
	N1	7 (58.3%)
	N2	2 (16.7%)
	N3	2 (16.7%)
Tumor type	NST	8 (66.7%)
	Lobular	4 (33.3%)
Grading	G1	1 (8.3%)
	G2	7 (58.3%)
	G3	4 (33.3%)
Receptor positivity	ER positivity	9 (75.0%)
	PR positivity	6 (50.0%)
	HER2 positivity	1 (8.3%)
Tumor regression (Chevallier)	1	1 (8.3%)
	2	2 (16.7%)
	3	9 (75.0%)

Table 2. Overview of patients in the cohort (ypN = post-chemotherapy nodal status by final histological examination)

Patient no.	Tumour type	Number of SLNs	Perioperative histological examination of SLN	Definitive histological examination of SLN	ypN acc. to level I dissection and SLNB	Number of affected LN in level I and SLN/ total number of LN in level I and SLN	ypN acc. to level I and II dissection and SLNB	Number of affected LN in level I and II and SLN/ total number of LN in level I and II and SLN
1	NST	1	micro	micro	N1	2/5	N1	2/11
2	NST	1	macro	macro	N2	7/15	N3	10/24
3	NST	1	micro	ITC	N1	1/2	N2	5/9
4	L	1	macro	macro	N1	2/8	N1	3/14
5	L	1	macro	macro	N1	2/4	N1	2/7
6	NST	1	micro	micro	N1	3/4	N2	4/6
7	L	1	ITC	ITC	N1	3/4	N2	5/10
8	NST	6	macro	macro	N3	10/13	N3	14/23
9	L	1	micro	macro	N1	3/3	N2	5/12
10	NST	1	macro	macro	N2	4/6	N2	5/10
11	NST	1	macro	macro	N1	1/6	N1	1/13
12	NST	2	macro	macro	N1	2/5	N1	2/11

LN: Lymph nodes, SLN: Sentinel lymph node, ITC: Isolated tumour cells, micro: micrometastasis, macro: macrometastasis, NST: Invasive carcinoma of no special type, L: Invasive lobular carcinoma.

either tumor size greater than five cm, histologic grade three, or Ki-67 \geq 20%) may be offered adjuvant endocrine therapy with a combination of CDK 4/6 inhibitor abemaciclib (15). In the case of HER2 positive tumors, patients with nodal involvement or patients with the absence of steroidal receptor expression benefit most from the adjuvant dual anti-HER2 blockade (16). Patients with luminal B HER+ carcinoma with nodal involvement who did not achieve pathological complete remission after NAC administration benefit from sequential therapy of trastuzumab and neratinib (17).

In the past few decades, the trend in breast cancer surgery has been to reduce the radicality of operations performed (18). Few studies have documented replacing levels I and II axillary dissections with radiotherapy in patients with positive sentinel lymph node and without NAC (19,20). OTOASOR and AMAROS trials confirmed a lower morbidity rate in patients with radiotherapy compared to patients with ALND with the same oncosurgical safety (19,20). A study with a group of patients after NAC and positive sentinel lymph node with the indication of radiotherapy as an alternative to ALND is ongoing-Alliance study A011202, with the results in 2024 (21).

One of the most important factors in oncosurgical safety is the probability of locoregional relapses (22). Unfortunately, there are no studies in the literature regarding locoregional relapses in patients after level I axillary dissection after NAC. Graversen investigated locoregional relapses in three subgroups of patients without NAC-included were patients without axillary

dissection, patients with level I axillary dissection and patients with level I and II axillary dissection (23). There were 3128 patients included in the study with five-year follow-up. Axillary relapse occurred in 19% of patients without ALND, 10% patients with level I axillary dissection, and 3% patients with level I and II axillary dissection (23). The incidence of axillary relapses in Graversen's study from 1988 is much higher compared to the studies of AMAROS and OTOASOR with a published incidence of 2% and 0.43%, respectively, obviously due to the higher efficiency of current adjuvant therapy (19,20).

We foresee that in patients with positive sentinel lymph node after NAC, less radical procedures will be investigated as in patients without NAC. Few studies have already been published on this topic, but their results are inconsistent (24,25).

Lymph nodes in axillary levels I and II are not anatomically separated. A surgeon performing level I dissection orients by using the lateral border of pectoral minor muscle as a boundary of the axillary levels. But some borderline lymph nodes cannot be clearly identified as belonging to level I or II. Level I axillary dissection may contain a few lymph nodes from level II, or some lymph nodes of level I may remain in the axilla. This could be a slight limitation in the reproducibility of the study. Another apparent limitation is the low number of included patients. However, the study was designed as a pilot trial. Based on the results, we conclude that level I axillary dissection seems insufficient for adequate nodal staging in patients with tumour involved sentinel lymph node after NAC.

CONCLUSION

Although TNM classification recommends the axillary dissection of level I with at least six lymph nodes as a minimum for adequate nodal staging in patients with breast cancer, our study revealed that this procedure is not sufficient after NAC due to the risk of understaging. Since nodal staging after NAC is an essential prognostic factor and could affect the indication of further treatment, we do not consider axillary dissection of level I only as an adequate method, and we recommend a standard axillary dissection of levels I and II.

Ethics Committee Approval: The study was conducted according to the guidelines of the Declaration of Helsinki, and approved by the Ethics Committee of Faculty of Medicine, University of Ostrava (12/2018, 26.3.2018), by the Ethics Committee of University Hospital Ostrava (1031/2017, 23.11.2017), by the Ethics Committee of Silesian Hospital in Opava (298/2017, 14.11.2017) and by the Ethics Committee of EUC Clinic Zlín (13/2020, 27.4.2020). All patients participating in the study signed consent to participate.

Peer-review: Externally peer-reviewed.

Author Contributions: Concept - JT, OC, MH, OK; Design - JZ, OC, OK; Supervision - OC, OK, ML, MP; Fundings - MP, OC, MK; Materials - JZ, OC, MK, JG; Data Collection and/ or Processing - JZ, MK, JG; Analysis and/ or Interpretation - JZ, OC, OK; Literature Search - JZ, MH, OC, ML; Writing Manuscript - JZ, MH, OC; Critical Reviews - JG, MP, ML.

Conflict of Interest: The authors have no conflicts of interest to declare.

Financial Disclosure: Supported by MH CZ – DRO (MMCI, 00209805) and by the Student Grant Competition of Specific University Research of the University of Ostrava (SGS04 / LF / 2018-2019).

REFERENCES

- National Comprehensive Cancer Network. *Breast Cancer (Version 5-2021)*. Available from: https://www.nccn.org/professionals/physician_gls/pdf/breast.pdf (Accessed date: 28.07.2021).
- Boughey JC, Suman VJ, Mittendorf EA, Ahrendt GM, Wilke LG, Taback B, et al. Sentinel lymph node surgery after neoadjuvant chemotherapy in patients with node-positive breast cancer: The ACOSOG Z1071 (Alliance) clinical trial. *JAMA* 2013; 310(14): 1455-61. <https://doi.org/10.1001/jama.2013.278932>
- Kuehn T, Bauerfeind I, Fehm T, Fleige B, Hausschild M, Helms G, et al. Sentinel-lymph-node biopsy in patients with breast cancer before and after neoadjuvant chemotherapy (SENTINA): A prospective, multicentre cohort study. *Lancet Oncol* 2013; 14(7): 609-18. [https://doi.org/10.1016/S1470-2045\(13\)70166-9](https://doi.org/10.1016/S1470-2045(13)70166-9)
- Caudle AS, Yang WT, Krishnamurthy S, Mittendorf EA, Black DM, Gilcrease MZ, et al. Improved axillary evaluation following neoadjuvant therapy for patients with node-positive breast cancer using selective evaluation of clipped nodes: Implementation of targeted axillary dissection. *J Clin Oncol* 2016; 34(10): 1072-8. <https://doi.org/10.1200/JCO.2015.64.0094>
- Cao S, Liu X, Cui J, Liu X, Zhong J, Yang Z, et al. Feasibility and reliability of sentinel lymph node biopsy after neoadjuvant chemotherapy in breast cancer patients with positive axillary nodes at initial diagnosis: An up-to date meta-analysis of 3578 patients. *Breast* 2021; 59: 256-69. <https://doi.org/10.1016/j.breast.2021.07.015>
- Swarnkar PK, Tayeh S, Michell MJ, Mokbel K. The evolving role of marked lymph node biopsy (MLNB) and targeted axillary dissection (TAD) after neoadjuvant chemotherapy (NACT) for node-positive breast cancer: Systematic review and pooled analysis. *Cancers (Basel)* 2021; 13(7): 1539. <https://doi.org/10.3390/cancers13071539>
- Armer JM, Ballman KV, McCall L, Ostby PL, Zagar E, Kuerer HM, et al. Factors associated with lymphedema in women with node-positive breast cancer treated with neoadjuvant chemotherapy and axillary dissection. *JAMA Surg* 2019, 154(9): 800-9. <https://doi.org/10.1001/jamasurg.2019.1742>
- Wylid L, Markopoulos C, Leidenius M, Senkus-Konefka E. *Breast Cancer Management for Surgeons: A European Multidisciplinary Textbook*. Springer, 2017. <https://doi.org/10.1007/978-3-319-56673-3>
- Cardoso F, Kyriakides S, Ohno S, Penault-Llorca F, Poortmans P, Rubio IT, et al. Early breast cancer: ESMO clinical practice guidelines for diagnosis, treatment and follow-up. *Ann Oncol* 2019; 30: 1194-220. <https://doi.org/10.1093/annonc/mdz173>
- Zetterlund L, Celebioglu F, Hatschek T, Frisell J, de Boniface J. Long-term prognosis in breast cancer is associated with residual disease after neoadjuvant systemic therapy but not with initial nodal status. *Br J Surg* 2021; 108: 583-9. <https://doi.org/10.1002/bjs.11963>
- Laot L, Laas E, Girard N, Dumas E, Daoud E, Grandal B, et al. The prognostic value of lymph node involvement after neoadjuvant chemotherapy is different among breast cancer subtypes. *Cancers (Basel)* 2021; 13: 171. <https://doi.org/10.3390/cancers13020171>
- Huang Z, Zhu L, Huang XB, Tang Y, Rong QL, Shi M, et al. Postmastectomy radiation therapy based on pathologic nodal status in clinical node-positive stage II to III breast cancer treated with neoadjuvant chemotherapy. *Int J Radiat Oncol Biol Phys* 2020; 108: 1030-9. <https://doi.org/10.1016/j.ijrobp.2020.06.028>
- Brierley JD, Gospodarowicz MK, Wittekind C. *TNM Classification of Malignant Tumours*. John Wiley & Sons, 2017. <https://doi.org/10.1002/9780471420194.tnmc26.pub3>
- Pilewskie M, Morrow M. Axillary nodal management following neoadjuvant chemotherapy: A review. *JAMA Oncol* 2017; 3: 549-55. <https://doi.org/10.1001/jamaoncol.2016.4163>
- Johnston SRD, Harbeck N, Hegg R, Toi M, Martin M, Shao ZM, et al. Abemaciclib combined with endocrine therapy for the adjuvant treatment of HR+, HER2-, node-positive, high-risk, early breast cancer (MonarchE). *J Clin Oncol* 2020; 38: 3987-98. <https://doi.org/10.1200/JCO.20.02514>
- von Minckwitz G, Procter M, de Azambuja E, Zardavas D, Benyunes M, Viale G, et al. Adjuvant pertuzumab and trastuzumab in early HER2-positive breast cancer. *N Engl J Med* 2017; 377: 122-31. <https://doi.org/10.1056/NEJMoa1703643>
- Martin M, Holmes FA, Ejlertsen B, Delalogue S, Moy B, Iwata H, et al. Neratinib after trastuzumab-based adjuvant therapy in HER2-positive breast cancer (ExteNET): 5-year analysis of a randomised, double-blind, placebo-controlled, phase 3 trial. *Lancet Oncol* 2017; 18: 1688-700. [https://doi.org/10.1016/S1470-2045\(17\)30717-9](https://doi.org/10.1016/S1470-2045(17)30717-9)
- Veronesi P, Corso G. Standard and controversies in sentinel node in breast cancer patients. *Breast* 2019; 48 (1), 53-6. [https://doi.org/10.1016/S0960-9776\(19\)31124-5](https://doi.org/10.1016/S0960-9776(19)31124-5)
- Sávolt Á, Péley G, Polgár C, Udvarhelyi N, Rubovszky G, Kovács E, et al. Eight-year follow up result of the OTOASOR trial: The optimal treatment of the axilla-surgery or radiotherapy after positive sentinel lymph node biopsy in early-stage breast cancer: A randomized, single centre, phase III, non-inferiority trial. *Eur J Surg Oncol* 2017; 43: 672-9. <https://doi.org/10.1016/j.ejso.2016.12.011>

20. Donker M, van Tienhoven G, Straver ME, Meijnen P, van de Velde CJH, Mansel RE, et al. Radiotherapy or surgery of the axilla after a positive sentinel node in breast cancer (EORTC 10981-22023 AMAROS): A randomised, multicentre, open-label, phase 3 non-inferiority trial. *Lancet Oncol* 2014; 15: 1303-10. [https://doi.org/10.1016/S1470-2045\(14\)70460-7](https://doi.org/10.1016/S1470-2045(14)70460-7)
21. *ClinicalTrials. Comparison of Axillary Lymph Node Dissection With Axillary Radiation for Patients With Node-Positive Breast Cancer Treated With Chemotherapy. Available from: https://clinicaltrials.gov/ct2/show/NCT01901094 (Accessed date: 26.11.2020).*
22. Falco M, Masojć B, Kram A. Locoregional relapse is a strong prognostic indicator of distant metastatic progression in breast cancer patients after negative sentinel lymph node biopsy. *Breast J* 2020. <https://doi.org/10.1111/tbj.14118>
23. Graversen HP, Blichert-Toft M, Andersen JA, Zedeler K. Breast cancer: Risk of axillary recurrence in node-negative patients following partial dissection of the axilla. *Eur J Surg Oncol* 1988; 14(5): 407-12.
24. Almahariq MF, Levitin R, Quinn TJ, Chen PY, Dekhne N, Kiran S, et al. Omission of axillary lymph node dissection is associated with inferior survival in breast cancer patients with residual N1 nodal disease following neoadjuvant chemotherapy. *Ann Surg Oncol* 2021; 28: 930-40. <https://doi.org/10.1245/s10434-020-08928-2>
25. Chun JW, Kim J, Chung IY, Ko BS, Kim HJ, Lee JW, et al. Sentinel node biopsy alone for breast cancer patients with residual nodal disease after neoadjuvant chemotherapy. *Sci Rep* 2021; 11: 9056. <https://doi.org/10.1038/s41598-021-88442-x>



ORIJİNAL ÇALIŞMA-ÖZET

Turk J Surg 2023; 39 (1): 1-6

Meme kanseri ve tümör tutulumlu sentinel lenf nodu olan hastalarda, neoadjuvan kemoterapi sonrası seviye 1 aksiller diseksiyon, uygun bir nod evrelemesi için yeterli değildir

Jan Žatecký¹⁻³, Oldřich Coufal^{1,4}, Miloš Holánek^{5,6}, Otakar Kubala^{7,8}, Markéta Kepičová⁸, Jiří Gatěk⁹, Milan Lerch³, Matuš Peteja^{2,3}

¹ Masaryk Memorial Kanser Enstitüsü, Cerrahi Onkoloji Anabilim Dalı, Brno, Çek Cumhuriyeti

² Silesian Üniversitesi, Paramedik Sağlık Çalışmaları Enstitüsü, Opava, Çek Cumhuriyeti

³ Opava Silesian Hastanesi, Cerrahi Kliniği, Opava, Çek Cumhuriyeti

⁴ Masaryk Üniversitesi, Cerrahi Onkoloji Anabilim Dalı, Brno, Çek Cumhuriyeti

⁵ Masaryk Memorial Kanser Enstitüsü, Kapsamlı Kanser Tedavileri Anabilim Dalı, Brno, Çek Cumhuriyeti

⁶ Masaryk Üniversitesi, Kapsamlı Kanser Tedavileri Anabilim Dalı, Brno, Çek Cumhuriyeti

⁷ Ostrava Üniversitesi, Cerrahi Çalışmalar Anabilim Dalı, Ostrava, Çek Cumhuriyeti

⁸ Ostrava Üniversite Hastanesi, Cerrahi Kliniği, Ostrava, Çek Cumhuriyeti

⁹ Zlín EUC Kliniği, Cerrahi Bölümü, Zlín, Çek Cumhuriyeti

ÖZET

Giriş ve Amaç: Çalışmanın amacı, neoadjuvan kemoterapi (NAC) sonrası meme kanseri ve tümör tutulumlu sentinel lenf nodu (SLN) olan hastalarda yeterli histolojik nodal evreleme (ypN) için seviye I aksiller diseksiyonun onkolojik yeterliliğini araştırmaktır.

Gereç ve Yöntem: 01.01.2018 ve 30.11.2020 tarihleri arasında Çek Cumhuriyeti'ndeki üç meme merkezinde NAC sonrası meme kanseri olan hastalarda prospektif çok merkezli bir pilot çalışma gerçekleştirildi (NCT03556397). SLN'nin histolojik frozen kesiti pozitif olan kohorttaki hastaların, seviye I ve II'de ayrı aksiller diseksiyon yapması belirtildi.

Bulgular: NAC sonrası meme kanseri gelişen 61 hasta dahil edilme ve dışlanma kriterlerine göre çalışmaya dahil edildi. NAC'den sonra SLN'ye dahil olan meme kanseri ve tümörü olan 12 hasta ayrıca analize dahil edildi. İki (%16,7) hastada sadece seviye I'de pozitif sentinel olmayan lenf nodu vardı, bir (%8,3) hastada sadece seviye II'de pozitif lenf nodu vardı ve yedi (%58,3) hastada her iki seviyede de pozitif lenf nodu vardı. NAC sonrası SLN tutulmuş tümörü olan bir hastada seviye I aksiller diseksiyon beş (%41,7) hastada çoğunlukla ypN2 yerine ypN1 olarak düşük evreleme ile sonuçlanacaktı (%41,7).

Sonuç: Pilot sonuçlarımıza göre meme kanseri hastalarında NAC sonrası yeterli histolojik nodal evreleme açısından seviye I aksiller diseksiyon yeterli değildir ve seviye II aksiller diseksiyon ihmal edilmemelidir.

Anahtar Kelimeler: Meme kanseri, sentinel lenf nodu biyopsisi, neoadjuvan kemoterapi, aksiller diseksiyon, seviye I aksiller diseksiyon

DOI: 10.47717/turkjsurg.2023.5984