



# Nipple adenoma; a literature review and our experience with a rare feature

Betül Güzelyüz<sup>1</sup>, Berrin Papila<sup>2</sup>, Cemal Gündoğdu<sup>3</sup>, Hüseyin Büyükbayram<sup>4</sup>

<sup>1</sup>Clinic of General Surgery, Hassa State Hospital, Hatay, Türkiye

<sup>2</sup>Department of General Surgery, İstanbul University-Cerrahpaşa, Cerrahpaşa Faculty of Medicine, İstanbul, Türkiye

<sup>3</sup>Clinic of Medical Pathology, Medicana International İstanbul Hospital, İstanbul, Türkiye

<sup>4</sup>Department of Medical Pathology, Dicle University Faculty of Medicine, Diyarbakır, Türkiye

## ABSTRACT

With this review, we aimed to contribute to the literature by reviewing the studies on nipple adenoma and presenting a novel study regarding its occurrence in a male case, for which we have not found any publications worldwide. We have reviewed studies on nipple adenoma, which we rarely encounter in the literature. We also present a 41-year-old male patient, whom we operated on with a diagnosis of nipple adenoma. His postoperative histopathological examination revealed invasive breast carcinoma, a unique case in the literature, together with this review study. Nipple adenoma, which is extremely rare in male patients, is rare in the literature and clinical practice. In light of the data, this case is the second instance of a male patient with nipple adenoma presented in the literature after many years. The fact that it is the only male patient associated with invasive carcinoma makes the case unique. Nipple adenomas require careful examination because they are rare and can be confused with malignancy. Moreover, although its association with malignancy is exceptionally rare, it should still be included in the differential diagnosis for male breast lesions. Safe surgery and postoperative follow-up are recommended.

**Keywords:** Nipple adenoma, male nipple adenoma, benign breast tumors, male breast cancer

## INTRODUCTION

Nipple adenoma is a benign epithelial breast tumor originating from the ducts and isn't a precancerous lesion. It is almost always unilateral. This extremely rare tumor, which constitutes less than 1% of breast specimens, is mostly seen in women in the fourth and fifth decades and is exceptional in men and children. The time between the onset of symptoms and diagnosis varies, but is usually several years. Unilateral breast itching, pain, serous discharge, and crusting are the most common symptoms and can be clinically confused with Paget's disease (1,2). In addition, they suggest a malignant mass because they are observed as irregularly bordered and hypoechoic lesions on ultrasonography and as nodular density with unclear boundaries on mammography. It may be confused with atypical ductal hyperplasia, ductal carcinoma *in situ*, invasive ductal carcinoma, or adenosquamous carcinoma and although rare, it may also be associated with these. Following a preliminary clinical diagnosis based on the specific location and morphology of the tumor, the definitive diagnosis is made by histopathological examination (2-5). Immunohistochemical examinations for some markers such as p63, superior mesenteric artery, calponin, and estrogen receptor may also be required to distinguish it from an invasive or ductal carcinoma (6). Since it is known that the probability of recurrence is extremely low and the prognosis is excellent, excision in the treatment is sufficient to provide negative surgical margins. Unnecessary extensive surgeries are not recommended (4,7). However, since there is insufficient data on whether it is associated with carcinoma, postoperative follow-up is recommended (2).

We reviewed studies on nipple adenoma, a rare entity in the literature. We presented the case of a 41-year-old male patient who was operated on with a diagnosis of nipple adenoma, and whose postoperative histopathological examination revealed invasive breast carcinoma. This case is unique in the literature and is included in our review study.

**Cite this article as:** Güzelyüz B, Papila B, Gündoğdu C, Büyükbayram H. Nipple adenoma; a literature review and our experience with a rare feature. *Turk J Surg*. [Epub Ahead of Print]

### Corresponding Author

Betül Güzelyüz

E-mail: b.gzlyz1994@gmail.com

ORCID ID: orcid.org/0000-0002-9092-1705

Received: 27.03.2025

Accepted: 12.08.2025

Epub: 15.08.2025

DOI: 10.47717/turkjsurg.2025.2025-3-31

Available at [www.turkjsurg.com](http://www.turkjsurg.com)



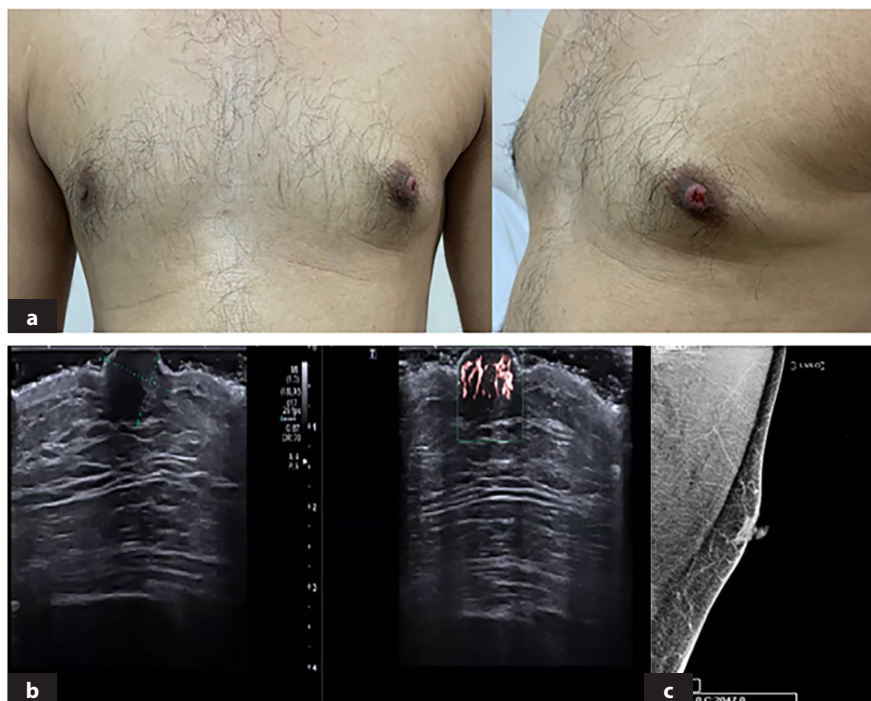## CASE REPORT

A 41-year-old male patient presented with hyperemia, protruding roughness of the nipple, and serous discharge in the left nipple for 9 months (Figure 1a). In ultrasonography, the volume of the left nipple has increased and is 6x9 mm; the nipple skin-subcutaneous tissues are eroded, and the nipple has a hypoechoic appearance with a diameter of 2.2 mm in the center. It suggests a dilated duct with dense content. There are no findings in the areola or retroareolar plane on mammography other than a distinct area in the left nipple (Figure 1b, c). Histopathological examination of the punch biopsy revealed nipple adenoma; immunohistochemical examination reported keratin 5/6 and P63 positive, Ki-67 10% (Figure 2). The patient underwent left nipple resection. Frozen section examination was performed to ensure resection with negative surgical margins to prevent recurrence. In the frozen examination, one side was ulcerated, with suspicious findings observed on the incision surface. Thereupon, considering the relatively low breast volume in the male patient, a mastectomy was performed to achieve extended excision, followed by a sentinel lymph node biopsy. The sentinel lymph node was negative for malignancy and the histopathological examination of the mastectomy specimen revealed an invasive breast carcinoma, 0.6x0.5x0.4 cm in size, with unifocal nipple localization, no special type (ductal) (pT1b, pN0, pMx), and the distance to the nearest surgical margin was

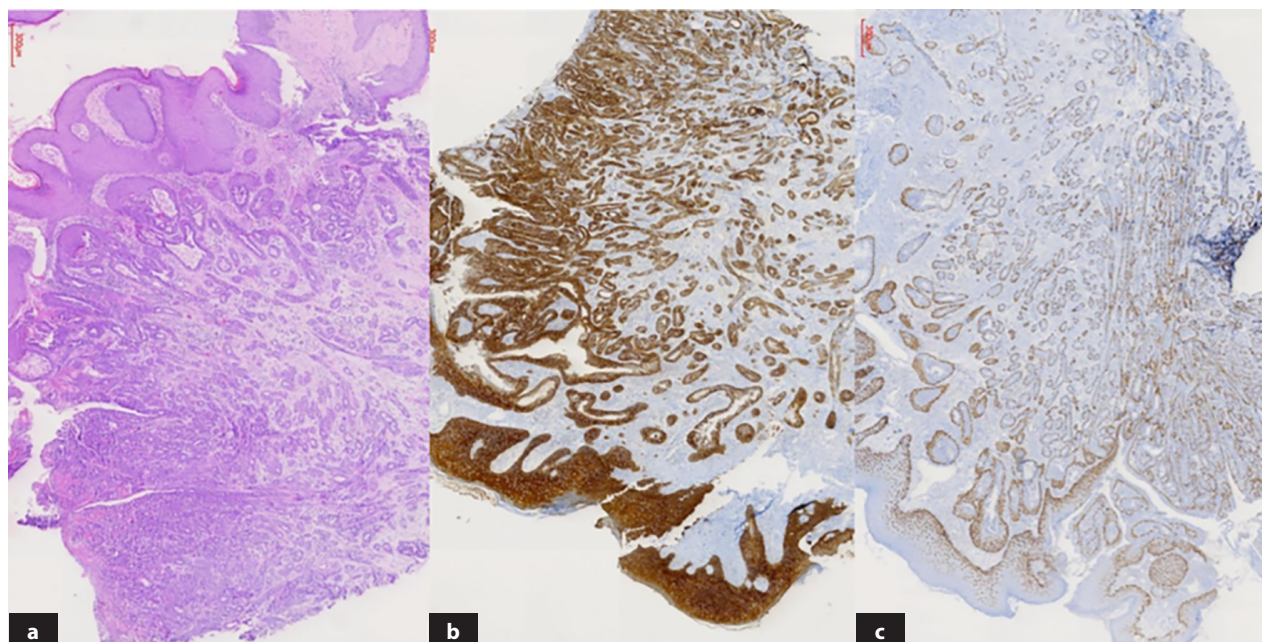
reported as 4.5 cm. Histological grade 1, Mitotic score 1, ER 70% positive, PR 0% negative, human epidermal growth factor receptor-2 (Cerb B-2) 0 negative, Ki-67 20% positive. There is no indication for RT in the node-negative patient. Postoperative treatment and follow-up with Tamoxifen continue in cases of 6 mm tumor and Grade 1, and no complications or recurrence have been observed for more than 1 year.

## DISCUSSION

Nipple adenoma is a rare benign condition that can be confused with Paget's disease of the breast (8). However, it can be confused with malignant lesions and although rare, some publications mention its association with carcinoma (9). In addition, as with other breast lesions, almost all adenomas are seen in women. This makes clinical suspicion difficult in male patients. In the nipple adenoma, which was first described in 1973, in the study published in 1986, consisting of 51 cases, which is still the largest case series known on this subject, in the study published in 2010, 19 cases encountered over 14 years were described, in the study published in 2014, 13 cases were presented, and in studies where 11 cases in 2021 and 12 cases in 2022 were presented, the patients are almost exclusively female (4,6,7,10-12). Finally, in 2023, Weigelt et al.'s (13) 50-case study, which revealed their 20-year experience and is the largest nipple adenoma series published to date, also included female patients only. Although it is stated in this and many similar publications



**Figure 1.** Clinical and radiological images of nipple adenoma. **a)** Hyperemia and serous discharge in the left nipple. **b)** On ultrasonography, the volume of the left nipple has increased and is 6x9 mm, the skin-subcutaneous tissues are eroded, with the central nipple showing a hypoechoic appearance with a diameter of 2.2 mm, suggesting a dilated duct with dense content in the foreground. **c)** In mammography, there are no findings other than prominence in the left areola.



**Figure 2.** Histopathological examination of punch biopsy of nipple adenoma. **a)** Lesion consisting of proliferation of benign glands and ducts scattered within the stroma under the squamous epithelium on the surface, x4 magnification. **b)** Duct epithelia and squamous epithelium stained positively with keratins 5 and 6. **c)** Myoepithelial cells covering the ducts externally were stained positively with p63. The preservation of the outer myoepithelium shows that the lesion is benign and not invasive.

that the incidence rate in men is less than 5%, no study has been found that examines male nipple adenomas in detail. However, the only known case of male nipple adenoma was reported by Boutayeb et al. (14) in 2012 and was subsequently introduced into the literature by these authors (6). On the other hand, although nipple adenoma is similar to invasive carcinoma, its association is so rare that it can be called coincidental. A study of 5 cases was published in 1995, and upon detailed examination, all of them were female patients (9). Considering the data, the case we experienced involves the second male patient with nipple adenoma presented after many years. Additionally, it is the first male patient in the literature associated with invasive carcinoma, which makes the case unique.

However, in the study that mentioned the adenoma-carcinoma association, it was stated that three of the cases presented with a subareolar mass and two with a palpable mass in the lower inner quadrant, accompanied by nipple findings (9). On the other hand, in the study that emphasized that adenoma is a benign lesion that can be expressed as “florid papillomatosis of the nipple duct” and in the male case in whom a nipple adenoma was detected, with no progression in the postoperative follow-up, it is noteworthy that the clinical features of the case include findings limited to the nipple and that there is no palpable mass or other radiological findings (14). The findings in our case did not include a mass, as is often seen in cases with carcinoma,

both clinically and radiologically. However, unlike the male case report in the literature without accompanying carcinoma, our case also presented with serous nipple discharge, in addition to other nipple findings. As a result, it was determined that our case had associated carcinoma.

## CONCLUSION

Nipple adenomas require careful examination because they are rare and can be confused with malignancy. Moreover, since it may be associated with malignancy, especially in cases with palpable findings and duct-related symptoms, although it can be considered exceptional, it should be included in the differential diagnosis of male patients, as in all other breast lesions. A safe surgery and postoperative follow-up are recommended.

## Ethics

**Informed Consent:** Written-signed informed consent was obtained from the patient.

## Footnotes

### Author Contributions

Surgical and Medical Practices - B.G., B.P.; Concept - B.G.; Design - B.G.; Data Collection or Processing - C.G., H.B.; Analysis or Interpretation - B.P.; Literature Search - B.G.; Writing - B.G.

**Conflict of Interest:** No conflict of interest was declared by the authors.

**Financial Disclosure:** The authors declared that this study received no financial support.

## REFERENCES

1. Işıksalan Özbülül N, Özgün A, Özgün U, Parlak S. A case of nipple adenoma mimicking intraductal papilloma, *Firat Med J.* 2009;14:222-223.
2. Quintana-Codina M, Pérez-Muñoz N, Fernández-Figueras MT, Altemir A, Salleras M. Adenoma of the nipple: a mimic of breast malignancy. *Dermatol Online J.* 2021;27.
3. Barco I, Vidal M, Fraile M, Masferrer E, Barco L, Barco D, et al. MOHS micrographic surgery for treating erosive adenoma of the nipple: a case report and review of the literature. *Int J Dermatol.* 2017;56:1451-1454.
4. Aftab K, Idrees R. Nipple adenoma of breast: a masquerader of malignancy. *J Coll Physicians Surg Pak.* 2010;20:472-474.
5. Yang GZ, Li J, Ding HY. [Nipple adenoma: report of 18 cases with review of literatures]. *Zhonghua Bing Li Xue Za Zhi.* 2009;38:614-616. Chinese.
6. Kırmızı A, Dizbay Sak S. Histopathological and immunohistochemical findings of nipple adenoma. *J Ankara Univ Fac Med.* 2021;74:259-263.
7. Aktaş E, Moustafa E, Uysal I, Armutlugöynük H, Özay Nayır P. Nipple adenoma in a young female: a case report. *J Cosmet Dermatol.* 2022;21:5221-5222.
8. Ikeda DM, Helvie MA, Frank TS, Chapel KL, Andersson IT. Paget disease of the nipple: radiologic-pathologic correlation. *Radiology.* 1993;189:89-94.
9. Jones MW, Tavassoli FA. Coexistence of nipple duct adenoma and breast carcinoma: a clinicopathologic study of five cases and review of the literature. *Mod Pathol.* 1995;8:633-636.
10. Bhagavan BS, Patchefsky A, Koss LG. Florid subareolar duct papillomatosis (nipple adenoma) and mammary carcinoma: report of three cases. *Hum Pathol.* 1973;4:289-295.
11. Rosen PP, Caicco JA. Florid papillomatosis of the nipple. A study of 51 patients, including nine with mammary carcinoma. *Am J Surg Pathol.* 1986;10:87-101.
12. Di Bonito M, Cantile M, Collina F, D'Aiuto M, Liguori G, DE Cecio R, et al. Adenoma of the nipple: a clinicopathological report of 13 cases. *Oncol Lett.* 2014;7:1839-1842.
13. Weigelt MA, Sciallis AP, McIntire PJ, Ko JS, Billings SD, Ronen S. Nipple adenoma: clinicopathologic characterization of 50 cases. *Am J Surg Pathol.* 2023;47:926-932.
14. Boutayeb S, Benomar S, Sbitti Y, Harroudi T, Hassam B, Errihani H. Nipple adenoma in a man: an unusual case report. *Int J Surg Case Rep.* 2012;3:190-192. Retraction in: *Int J Surg Case Rep.* 2012;4:357. Retraction in: *Int J Surg Case Rep.* 2012;4:357.