



Early risk stratification of acute diverticulitis using procalcitonin, CRP, and CT imaging: A retrospective analysis

Ozan Barış Namdaroğlu¹, Ahmet Cem Esmer², Selen Öztürk¹, Saltuk Yıldız¹, Korhan Tuncer¹, Göksever Akpınar¹, Hilmi Yazıcı³

¹Department of General Surgery, University of Health Sciences Türkiye, İzmir Tepecik Education and Research Hospital, İzmir, Türkiye

²Clinic of Surgical Oncology, Antalya City Hospital, Antalya, Türkiye

³Department of General Surgery, Marmara University Pendik Research and Training Hospital, İstanbul, Türkiye

ABSTRACT

Objective: Distinguishing mild (Hinchey 1a/1b/2) from severe (Hinchey 3/4) diverticulitis is critical for appropriate management. This study evaluated the predictive value of inflammatory biomarkers and imaging features for early risk stratification.

Material and Methods: We conducted a retrospective analysis of patients with acute diverticulitis between 2017 and 2024 at the hospital's general surgery department. Receiver operating characteristic analysis was used to determine optimal cut-off values for C-reactive protein (CRP) and procalcitonin, while computed tomography (CT) findings were assessed for their discriminative capacity.

Results: A total of 72 patients were included in the study. There were 59 patients in the mild diverticulitis group and 13 patients in the severe diverticulitis group. Patient demographics were similar between the groups. Procalcitonin demonstrated superior predictive performance [area under the curve (AUC) 0.795] compared to CRP (AUC 0.755). The cut-off values for procalcitonin and CRP were 0.095 and 104.5, respectively. Specific CT patterns showed high specificity for severe disease. The combination of biomarkers and imaging criteria significantly improved diagnostic accuracy, with pelvic abscess localization emerging as a key indicator of severity.

Conclusion: A biomarker-guided approach incorporating procalcitonin and targeted CT evaluation enables reliable early identification of severe diverticulitis. This strategy may enhance clinical decision-making regarding antibiotic selection and surgical consultation while reducing unnecessary interventions in mild cases.

Keywords: Acute diverticulitis, C-reactive protein, procalcitonin, disease severity

INTRODUCTION

Acute diverticulitis is a common colonic disease characterized by inflammation and infection of the colonic diverticula, and its presentation may vary from a simple, self-limiting clinical condition to life-threatening complications such as perforation, peritonitis, or bleeding (1). The Hinchey classification system was described in 1978 by Hinchey et al. (2). It contains four different levels of colonic diverticulitis. While mild cases (Hinchey 1a, 1b, and 2) can often be managed by antibiotics and outpatient care, more severe cases (Hinchey 3 and 4) require surgical treatment due to the high risk of their mortality and morbidity (3). Despite its clinical utility, distinguishing between mild and severe diverticulitis at initial diagnosis remains challenging, often leading to delayed interventions or unnecessary hospitalizations (4).

Computed tomography (CT) is the gold standard diagnostic tool for acute diverticulitis (5). Clinical and treatment decisions mainly depend on the CT results. However, clinical symptoms such as abdominal pain, fever, and leukocytosis lack specificity, while CT findings may not always correlate with disease severity in the early stages. Inflammatory biomarkers, particularly C-reactive protein (CRP), have emerged as potential predictors in risk stratification. Recent studies emphasized the importance of CRP in the severity of diverticulitis (6). However, CRP, a non-specific acute-phase reactant, rises proportionally to tissue inflammation, whereas procalcitonin, a more specific marker for bacterial infections, may better indicate

Cite this article as: Namdaroğlu OB, Esmer AC, Öztürk S, Yıldız S, Tuncer K, Akpınar G, et al. Early risk stratification of acute diverticulitis using procalcitonin, CRP, and CT imaging: a retrospective analysis. *Turk J Surg.* 2026;42(2):173-180

Corresponding Author

Hilmi Yazıcı

E-mail: hilmiyazici@hotmail.com

ORCID ID: orcid.org/0000-0001-7470-0518

Received: 27.11.2025

Accepted: 30.01.2026

Epub: 03.02.2026

Publication Date: 04.06.2026

DOI: 10.47717/turkjsurg.2026.2025-11-37

Available at www.turkjsurg.com



systemic involvement (7). Nevertheless, standardized cut-off values for these markers in diverticulitis remain unclear, limiting their reliability in decision-making.

This study aims to investigate factors related to complicated diverticulitis in a single center. Moreover, it aims to determine optimal cut-off values for CRP and procalcitonin. The ability to predict severe diverticulitis at diagnosis could optimize patient triage, reduce healthcare costs, and improve outcomes by facilitating timely surgical consultation or intensive monitoring.

MATERIAL and METHODS

Study Design and Patient Selection

Data regarding patients who were treated with the diagnosis of acute diverticulitis at the University of Health Sciences Türkiye, İzmir Tepecik Education and Research Hospital's General Surgery Department between January 2017 and December 2024 were analyzed retrospectively. Patients were identified through hospital records using ICD-10 codes for diverticulitis (K57.0-K57.6). Inclusion criteria for the patients were aged over ≥ 18 years with radiologically confirmed acute diverticulitis, and availability of complete clinical, laboratory, and imaging data. Because of the retrospective design and non-standardized test ordering in routine practice, CRP and/or procalcitonin were not measured in all patients. Procalcitonin was typically requested selectively based on clinical severity, suspected systemic infection, or diagnostic uncertainty, and may also have been unavailable due to operational factors. Patients without the required biomarker measurements were excluded from analyses to ensure reliable estimation of biomarker cut-off values, acknowledging the potential for selection bias and limited generalizability. Also, patients with missing Hinchey classification and patients with diverticulitis secondary to malignancy or other inflammatory conditions were excluded from the study.

Data Collection

Demographical data, comorbid diseases, clinical features, laboratory parameters, imaging findings, hospitalizations, mortality, and morbidities were extracted from hospital electronic medical records. Patient stratification was performed exclusively based on contrast-enhanced CT findings at the time of admission. According to the Hinchey classification system, patients with localized pericolic inflammation or confined abscesses (Hinchey 1a, 1b, and 2) were categorized as having mild diverticulitis, whereas those with CT evidence of generalized purulent or fecal peritonitis, including free intraperitoneal fluid, extraluminal air, or diffuse contamination (Hinchey 3 and 4), were classified as having severe diverticulitis. CRP and procalcitonin were extracted as the first values obtained during the initial evaluation at emergency department admission. If

multiple measurements were available, the earliest value was used. Symptom onset time was not consistently documented; therefore, all proposed cut-offs refer to admission values.

All abdominal CT examinations were performed using a multidetector CT scanner (SOMATOM go. Up, Siemens Healthineers, Erlangen, Germany) at our institution. Given the retrospective design, the use of intravenous iodinated contrast was determined at the discretion of the treating physician based on the patient's renal function at the time of imaging; therefore, the dataset includes both contrast-enhanced and non-contrast CT studies. When intravenous contrast was administered, imaging was obtained using a multiphase abdominal CT protocol, including arterial, portal venous, and delayed phases, as per institutional routine and the clinical indication. Images were reconstructed with a slice thickness of 2 mm (including multiplanar reformations when available). Radiologic findings were extracted from the official radiology reports generated at the time of presentation. All CT examinations were interpreted and formally reported by on-duty attending radiologists. In keeping with the study's real-world design, images were not re-evaluated or independently re-read for research purposes; therefore, inter-observer agreement analyses were not performed.

Abscess on CT was defined as a well-demarcated, pericolic or pelvic fluid collection with well-bordered, heterogeneous content and possibly extraluminal air foci. Measurements were taken in axial and coronal planes, and the largest diameter was calculated in centimeters. An abscess size was identified among patients with severe diverticulitis; interventional thresholds were performed according to the existing literature.

Free fluid was defined as non-contrast-enhancing extraluminal fluid collection, typically in the pelvic recesses or pericolic spaces, without evidence of perforation. It was recorded as either present or absent.

Ethical Considerations

This study was approved by the Ethics Committee of the University of Health Sciences Türkiye, İzmir Tepecik Education and Research Hospital (approval number: 2025/01-06, date: 05/02/2025), and it was performed in accordance with the ethical standards as laid down in the 1964 Declaration of Helsinki and its later amendments or comparable ethical standards, and informed consent was waived due to the retrospective nature of the study.

Statistical Analysis

SPSS version 28.0 (SPSS Inc., IBM, Chicago, US) was used for statistical analysis. The data were presented as mean \pm standard deviation, median, and interquartile range (IQR). The proportion or frequency was compared between the two groups using Fisher's

exact test or the χ^2 test, and differences in continuous variables were evaluated using the Student's t-test and the Mann-Whitney U test for non-parametric values. Receiver operator characteristics (ROC) curves were obtained for CRP (mg/L) and procalcitonin (ng/mL). The Youden index (Sensitivity + 1 – Specificity) was used to determine the cut-off values for both laboratory values.

RESULTS

Between January 2017 and December 2024, 121 patients with acute left colon diverticulitis were admitted to the hospital. Of them, 49 patients had no CRP and procalcitonin values and were excluded from the study. Finally, 72 patients were included in the study with acute diverticulitis, stratified into mild (Hinchey 1a/1b/2, n=59) and severe (Hinchey 3/4, n=13) diverticulitis groups (Table 1). Demographic analysis revealed no significant

differences in age (mean 56.6±15.5 vs. 51.3±19.4 years, p=0.175) or sex distribution (48.6% male vs. 69.2%, p=0.100) between groups. Comorbidities, including diabetes (15.3% vs. 15.4%, p=1.000) and hypertension (37.5% vs. 23.1%, p=0.346), were similarly distributed. Abdominal pain was present in 94.4% of cases overall, without group differences (94.9% mild vs. 92.3% severe, p=0.558). However, although vomiting was more common in severe cases, this rate was not statistically significant (23.1% vs. 6.8%, p=0.106). Management strategies differed significantly. While hospitalization is required for all severe cases, 67.8% of mild cases are in need of hospitalization (p=0.015).

Laboratory results, CT imaging findings, and treatment status of the patients are summarized in Table 2. Between groups, only in inflammatory markers CRP and procalcitonin showed marked differences (p=0.004, p=0.001, respectively). Radiological

Table 1. Patient characteristics between the groups				
	All patients	Mild diverticulitis	Severe diverticulitis	
	n=72	n=59	n=13	p
Gender, n (%)				0.100
Male	35 (49%)	26 (44%)	9 (69%)	
Female	37 (51%)	33 (55%)	4 (31%)	
Age, mean ± SD	56.6±15.5	57.8±14.5	51.3±19.4	0.175
Comorbidity, n (%)				
Diabetes mellitus	11 (15%)	9 (15%)	2 (15%)	1.000*
Hypertension	27 (37%)	24 (41%)	3 (23%)	0.346*
Cardiovascular disease	7 (10%)	7 (12%)	0	0.337*
Pulmonary disease	3 (4%)	3 (5%)	0	1.000*
Symptoms, n (%)				
Abdominal pain	68 (94%)	56 (95%)	12 (92%)	0.558*
Vomiting	7 (10%)	4 (7%)	3 (23%)	0.106*
Fever	5 (7%)	4 (7%)	1 (8%)	1.000*
Hinchey classification, n (%)				<0.001
1a	52 (72%)	52 (88%)	0	
1b	3 (4%)	3 (5%)	0	
2	4 (6%)	4 (6%)	0	
3	11 (15%)	0	11 (85%)	
4	2 (3%)	0	2 (15%)	
Treatment, n (%)				0.015*
Outpatient	19 (26%)	19 (32%)	0	
Hospitalization	53 (74%)	40 (68%)	13 (100%)	
Number of attacks, n (%)				0.278
1	62 (86%)	49 (83%)	13 (100%)	
2	9 (12%)	9 (15%)	0	
3	1 (2%)	1 (2%)	0	

SD: Standard deviation, *: Fisher's exact test.

assessment through CT imaging yielded particularly discriminative findings. The presence of abscesses was significantly more common in severe cases (38.5%) compared to mild cases (11.9%, $p=0.034$), with pelvic abscesses showing the strongest association with severe disease (30.8% vs. 1.7%, $p=0.003$). Free fluid detection on CT scans emerged as a strongly associated finding for severe diverticulitis, present in all severe cases (100%) compared to only 11.9% of mild cases ($p<0.001$). Similarly, extraluminal air was observed in 92.3% of severe cases versus 10.2% of mild cases ($p<0.001$), further emphasizing the value of CT imaging in severity assessment.

The analysis of treatment strategies revealed significant differences in management between severity groups. All

patients with severe diverticulitis required hospitalization (100% vs. 67.8% in mild cases, $p=0.015$), with a substantially higher rate of surgical intervention in this group (100% vs. 5.1%, $p<0.001$). Medical management showed distinct patterns between groups. While 94.9% of mild cases were managed with standard antibiotic regimens alone, severe cases frequently required antibiotic escalation (61.5% vs. 13.6%, $p=0.001$), with broader-spectrum coverage including piperacillin-tazobactam or carbapenems.

We performed a multivariate logistic regression analysis to determine the independent factors for the severity of acute diverticulitis. Among the clinical findings and laboratory values, CRP and procalcitonin were found to be significant in

Table 2. Comparison of laboratory, imaging findings, and treatment strategies between the groups

Laboratory findings, median (IQR)	All patients	Mild diverticulitis	Severe diverticulitis	p
	n=72	n=59	n=13	
Glucose	107 (IQR: 94-130)	105 (IQR: 93-125)	125 (IQR: 95-136)	0.183
Ure	33 (IQR: 26-44)	35 (IQR: 27-43)	32 (IQR: 26-55)	0.843
Creatinin	1 (IQR: 0.8-1.1)	1 (IQR: 0.8-1.1)	1 (IQR: 0.9-1.2)	0.621
CRP	71 (IQR: 30-131)	62 (IQR: 27-108)	136 (IQR: 74-198)	0.004
WBC	12.2 (IQR: 9.8-15.7)	11.8 (IQR: 9.9-14.4)	15 (IQR: 9.6-19.2)	0.319
Neutrophil	9.1 (IQR: 6.5-12.2)	8.7 (IQR: 6.5-10.6)	10.8 (IQR: 7.6-16.2)	0.091
Lymphocyte	1.9 (IQR: 1.3-2.8)	1.9 (IQR: 1.4-2.7)	1.5 (IQR: 1-3)	0.629
Hemoglobin	12.9 (IQR: 11.9-14.6)	12.9 (IQR: 11.9-14.5)	13.1 (IQR: 11.7-14.8)	0.524
Platelet	268 (IQR: 220-321)	264 (IQR: 220-307)	315 (IQR: 246-367)	0.072
Procalcitonin	0.04 (IQR: 0.01-0.19)	0.03 (IQR: 0.01-0.07)	0.36 (IQR: 0.09-0.77)	0.001
CT findings, n (%)				
Abscess	12 (17%)	7 (12%)	5 (38%)	0.034*
Abscess localisation n (%)				0.003
Pelvic	5 (7%)	1 (2%)	4 (31%)	
Pericolonic	6 (8%)	5 (9%)	1 (8%)	
Retroperitoneal	1 (2%)	1 (2%)	0	
Abscess size, median (IQR)	4 (IQR: 2.3-6.8)	4 (IQR: 2-6)	6 (IQR: 2.5-7)	0.530
Free liquid n (%)	20 (28%)	7 (12%)	13 (100%)	<0.001*
Extra-luminal air n (%)	18 (25%)	6 (10)	12 (92%)	<0.001*
Treatment, n (%)				<0.001
Medical	56 (78%)	56 (95%)	0	
Surgery	16 (5%)	3 (5%)	13 (100%)	
Antibiotics, n (%)				0.001*
Standard	56 (78%)	51 (86%)	5 (38%)	
Wide spectrum	16 (22%)	8 (14%)	8 (62%)	
Morbidity, n (%)	3 (4%)	2 (3%)	1 (8%)	0.455
Mortality, n (%)	2 (3%)	1 (2%)	1 (8%)	0.331*

*: Fisher's exact test, IQR: Interquartile range, CT: Computed tomography, CRP: C-reactive protein, WBC: White blood cell.

the univariate analysis. In the multivariable logistic regression, procalcitonin was found to be the only predictive marker for the severity of acute diverticulitis (Table 3).

ROC curve analysis established optimal discriminatory thresholds for CRP and procalcitonin (Figures 1 and 2). CRP showed an area under the curve (AUC) of 0.755 [95% confidence interval (CI): 0.601-0.909, p=0.004], with an optimal cut-off value of 104.5 mg/L providing 69.2% sensitivity and 71.2% specificity. Procalcitonin exhibited even stronger predictive capability with

an AUC of 0.795 (95% CI: 0.652-0.937, p=0.001). The optimal cut-off was determined to be 0.095 ng/mL, yielding 76.9% sensitivity and 78.0% specificity.

DISCUSSION

This comprehensive study provides robust evidence supporting the use of inflammatory biomarkers for early and accurate differentiation between mild and severe diverticulitis. In this study, we aimed to obtain optimal cut-off values for CRP and

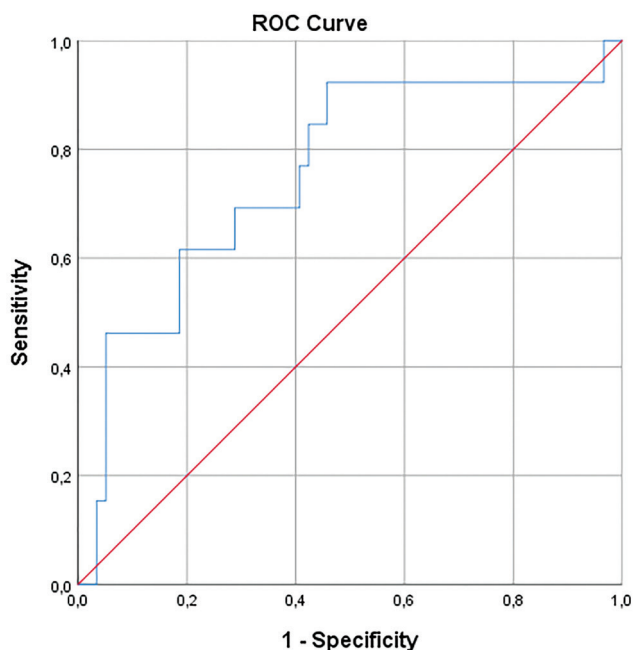
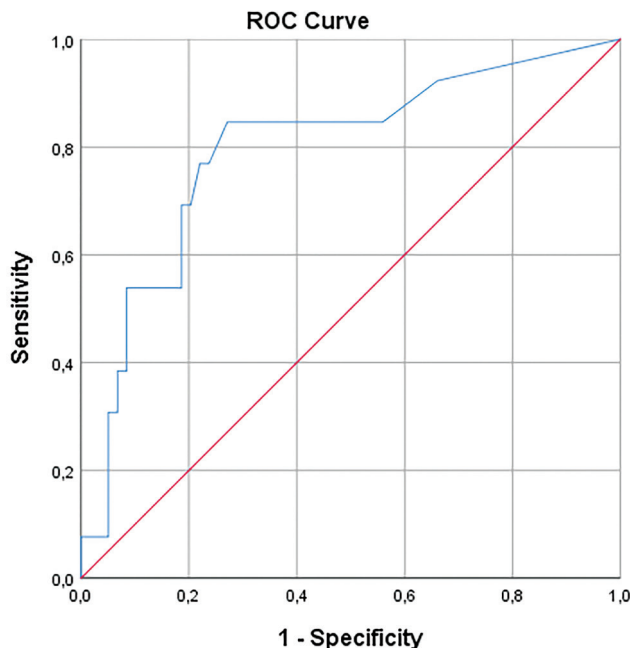


Figure 1. ROC curve for C-reactive protein. Cut-off value: 104.5 [sensitivity: 69.2%; specificity: 71.2%, AUC (95% CI): 0.755 (0.601-0.909), p=0.004].

ROC: Receiver operator characteristics, AUC: Area under the curve, CI: Confidence interval



Diagonal segments are produced by ties.

Figure 2. ROC curve for procalcitonin. Cut-off value 0.095 [sensitivity: 76.9%; specificity: 78%, AUC (95% CI): 0.795 (0.652-0.937), p=0.001].

ROC: Receiver operator characteristics, AUC: Area under the curve, CI: Confidence interval

Table 3. Univariable and multivariable logistic regression analysis regarding severity of diverticulitis						
n=72	OR	95% CI	p	OR	95% CI	p
Gender	2.856	0.790-10.323	0.109			
Age	0.972	0.934-1.013	0.176			
Abdominal pain	0.643	0.061-6.724	0.712			
Fever	1.146	0.117-11.186	0.907			
Diabetes mellitus	1.010	0.191-5.341	0.991			
Vomiting	4.125	0.789-21.299	0.091			
Creatinine >1 mg/dL	1.220	0.700-2.124	0.557			
White blood cell >11000 µL	1.077	0.972-1.195	0.158			
Hemoglobin	1.069	0.768-1.486	0.693			
C-reactive protein >104.5	5.559	1.506-20.512	0.010	1.979	0.413-9.479	0.393
Procalcitonin >0.095	11.795	2.824-49.265	<0.001	8.283	1.637-41.907	0.010

OR: Odds ratio, CI: Confidence interval.

procalcitonin in predicting severe diverticulitis, with cut-off values of 104.5 mg/L and 0.095 ng/mL, respectively. These biomarkers performed remarkably well in our ROC analysis and may provide valuable findings to clinical examinations. While CRP and procalcitonin have been associated with severe disease in recent studies, their combined application in a newly described risk assessment model might be essential.

For clinical use, this study suggests that elevated levels beyond these thresholds should prompt clinicians to consider early imaging, closer monitoring, or surgical consultation, particularly when clinical signs are evident. Although the primary aim of this study was not to develop a formal diagnostic algorithm, our results suggest that these biomarkers can play a role in a tailored decision-making process. Incorporating them into an evidence-based clinical pathway may facilitate earlier identification of patients at risk for complicated disease.

The exceptional performance of procalcitonin (AUC 0.795) compared to CRP (AUC 0.755) in our study likely reflects fundamental differences in their pathophysiological origins. While CRP is a general acute-phase reactant produced in response to interleukin-6 stimulation (8), procalcitonin is more specifically upregulated during severe bacterial infections and systemic inflammatory responses (7,9). This biological distinction explains why procalcitonin showed greater specificity (78% vs. 71.2%) for detecting complicated diverticulitis cases, which typically involve transmural inflammation and micro-perforation (10). Our optimal procalcitonin cut-off of 0.095 ng/mL aligns with recent multicenter studies (11,12), though slightly lower than thresholds reported in septic populations (13), reflecting the localized nature of diverticular inflammation.

The CRP cut-off value of 104.5 mg/L defined in our study deserves special attention. This value is lower than that found by Mäkelä et al. (6), who recommended 150 mg/L to diagnose inflammation in clinical practice, suggesting that the assessment of diverticulitis severity requires adjusted thresholds. There are various cut-off results regarding CRP and procalcitonin in recent studies. Nizri et al. (14) found that above 90 mg/L CRP levels are associated with a higher risk of complicated diverticulitis. Kechagias et al. (15) showed that CRP levels above 173 mg/L result in surgical or invasive drainage treatments. Both studies also showed that higher CRP levels are associated with higher Hinchey scores. The strong correlation between CRP levels and the Hinchey classification supports its role as a continuous marker of disease progression rather than a simple present/absent indicator.

Procalcitonin has been gaining popularity in recent years. It has been used as an inflammatory marker in various kinds of diseases (16). However, there is no clear consensus on the optimal cut-off value for the severity of acute diverticulitis. Schena et al. (7)

examined 503 acute left colon diverticulitis. They found that procalcitonin levels greater than 0.05 ng/mL have emerged as an independent risk factor for acute diverticulitis (7). In another study, Jeger et al. (17) found that procalcitonin levels above 0.1 ng/mL were related to complicated diverticular diseases. In this study, a procalcitonin level of 0.095 ng/mL was found to be related to severe diseases. Moreover, according to the multivariate logistic regression analysis, CRP and procalcitonin were found to be independent risk factors for severe diverticulitis. Our findings are also consistent with the existing studies. Yet, these findings should be supported by the large, prospective cohorts.

Our CT findings provide compelling evidence that imaging should serve as more than just a diagnostic tool for diverticulitis. The near-pathognomonic association of free fluid (100% vs. 11.9%, $p < 0.001$) and extraluminal air (92.3% vs. 10.2%, $p < 0.001$) with severe cases suggests these features should trigger immediate surgical consultation (5). Notably, the anatomical distribution of abscesses emerged as a critical prognostic factor - pelvic abscesses (30.8% in severe cases) were associated with poor outcomes, likely due to the challenging surgical access and higher risk of fistula formation (3). The 4.2 cm median abscess size in severe cases (IQR 2.5-7 cm) provides an essential benchmark for intervention thresholds, supporting recent guidelines recommending drainage for collections > 3 -4 cm (4).

The development of a weighted scoring system incorporating both biomarkers and imaging features represents the most clinically significant output of this research. Patients meeting all three high-risk criteria (CRP ≥ 104.5 mg/L, procalcitonin ≥ 0.095 ng/mL, and free fluid on CT) had a 97% probability of severe disease in our cohort. This finding may inform the establishment of a rapid assessment protocol in the emergency department. Thus, a faster emergency surgical consultation can be provided for patients with severe imaging findings, accelerating the treatment process. The combination of biomarker thresholds (CRP ≥ 104.5 mg/L and procalcitonin ≥ 0.095 ng/mL) together with key CT features such as free fluid or extraluminal air may represent a pragmatic high-risk profile for early surgical consultation and closer monitoring. However, we did not formally derive or externally validate a weighted score, and prospective validation is needed before implementation as a clinical decision rule.

Our study revealed significant differences in broad-spectrum antibiotic utilization between severity groups, with 61.5% of severe cases requiring escalated coverage compared to only 13.6% of mild cases ($p = 0.001$). This disparity highlights the critical need for precise risk stratification to guide appropriate antibiotic selection while avoiding unnecessary broad-spectrum use in mild diverticulitis (18,19).

Procalcitonin was the only biomarker that remained independently associated with severe diverticulitis in multivariate analysis, underscoring its superior prognostic value compared with conventional inflammatory markers. Unlike CRP, which reflects a nonspecific acute-phase response, procalcitonin is selectively upregulated in the setting of systemic bacterial infection and correlates more closely with bacterial burden and disease severity (8,9). This biological specificity likely explains its persistent association with complicated diverticulitis, which is frequently characterized by transmural inflammation and microperforation. Our findings are consistent with previous studies demonstrating procalcitonin as an independent predictor of disease severity and need for surgical intervention in acute diverticulitis (7,18). Notably, the optimal cut-off identified in our cohort (0.095 ng/mL) closely aligns with thresholds reported in prior prospective and multicenter studies, supporting the external validity of our results. Collectively, these data suggest that procalcitonin may serve as a key biomarker for early risk stratification, particularly when integrated with CT findings, and may help guide timely escalation of care in patients with severe disease.

These findings suggest a stratified antibiotic approach: narrow-spectrum regimens (e.g., amoxicillin-clavulanate) may suffice for mild cases without high-risk biomarkers, while severe cases with elevated procalcitonin or CRP ≥ 104.5 mg/L warrant broader coverage (e.g., piperacillin-tazobactam). This aligns with recent guidelines emphasizing biomarker-guided therapy, though prospective validation of our specific thresholds is needed (10-12,16). The absence of statistically significant differences in mortality (7.7% vs. 1.7%, $p=0.331$) and morbidity (7.7% vs. 3.4%, $p=0.455$) between severity groups should be interpreted with caution, as our study was likely underpowered to detect these clinically important outcomes due to the limited number of severe cases.

Study Limitations

While providing clinically relevant findings, our study has several limitations that merit discussion. First, this study has a relatively small number of patients diagnosed with severe diverticulitis ($n=13$). This restricted sample size might reduce the reliability of the statistical analysis, particularly those involving ROC curves and the determination of optimal diagnostic thresholds. While the findings offer valuable insights into potential predictive markers of CRP and procalcitonin, the sturdiness and generalizability of these results are limited. In addition, symptom onset timing could not be reliably captured in this retrospective dataset; thus, our biomarker thresholds are anchored to admission (baseline) measurements and may differ if tests are obtained later in the disease course. A post-hoc power analysis was not performed; however, we acknowledge that the small cohort size for this subgroup may introduce

variability and limit the ability to draw definitive conclusions. Future studies with larger sample sizes are warranted to validate these findings. Second, the single-center nature limits generalizability, though our patient demographics match population-level diverticulitis epidemiology. Therefore, future research should focus on:

- Multicenter validation of our cut-off values,
- Prospective evaluation of the proposed decision pathway,
- Cost-effectiveness analysis of biomarker-guided imaging strategies,
- Investigation of serial biomarker measurements for monitoring treatment response.

CONCLUSION

This study confirms that integrating CRP, procalcitonin, and CT findings enables early, accurate differentiation of severe diverticulitis. The proposed biomarker thresholds and imaging criteria provide a practical framework for risk stratification, guiding timely surgical intervention for high-risk cases while optimizing antibiotic use in mild diseases. Implementing this approach may improve outcomes through targeted management, though prospective validation is warranted to confirm clinical utility. These findings support moving toward precision medicine strategies in diverticulitis care.

Ethics

Ethics Committee Approval: This study was approved by the Ethics Committee of the University of Health Sciences Türkiye, İzmir Tepecik Education and Research Hospital (approval number: 2025/01-06, date: 05/02/2025), and it was performed in accordance with the ethical standards as laid down in the 1964 Declaration of Helsinki.

Informed Consent: Informed consent was waived due to retrospective nature of the study.

Footnotes

An abstract of this study was presented as an oral presentation at the 3rd International Turkish Colon and Rectum Surgery Congress in Belek, Antalya, Türkiye, between 16 and 20 May 2025.

Author Contributions

Concept - S.Ö., S.Y., K.T.; Design - S.Ö., S.Y., K.T.; Data Collection or Processing - O.B.N., A.C.E.; Analysis or Interpretation - H.Y.; Literature Search - O.B.N., A.C.E., H.Y.; Writing - O.B.N., A.C.E., G.A.

Conflict of Interest: No conflict of interest was declared by the authors.

Financial Disclosure: The authors declared that this study received no financial support.

REFERENCES

1. Feuerstein JD, Falchuk KR. Diverticulosis and diverticulitis. *Mayo Clin Proc.* 2016;91:1094-1104.
2. Hinchey EJ, Schaaf PG, Richards GK. Treatment of perforated diverticular disease of the colon. *Adv Surg.* 1978;12:85-109.
3. Biondo S, Lopez Borao J, Millan M, Kreisler E, Jaurrieta E. Current status of the treatment of acute colonic diverticulitis: a systematic review. *Colorectal Dis.* 2012;14:e1-e11.

4. Sartelli M, Weber DG, Kluger Y, Ansaloni L, Coccolini F, Abu-Zidan F, et al. 2020 update of the WSES guidelines for the management of acute colonic diverticulitis in the emergency setting. *World J Emerg Surg.* 2020;15:32.
5. Laméris W, van Randen A, Bipat S, Bossuyt PM, Boermeester MA, Stoker J. Graded compression ultrasonography and computed tomography in acute colonic diverticulitis: meta-analysis of test accuracy. *Eur Radiol.* 2008;18:2498-2511.
6. Mäkelä JT, Klintrup K, Takala H, Rautio T. The role of C-reactive protein in prediction of the severity of acute diverticulitis in an emergency unit. *Scand J Gastroenterol.* 2015;50:536-541.
7. Schena CA, Covino M, Laterza V, Quero G, La Greca A, Cina C, et al. The role of procalcitonin as a risk stratification tool of severity, prognosis, and need for surgery in patients with acute left-sided colonic diverticulitis. *Surgery.* 2024;176:162-171.
8. Pepys MB, Hirschfield GM. C-reactive protein: a critical update. *J Clin Invest.* 2003;111:1805-1812. Erratum in: *J Clin Invest.* 2003;112:299.
9. Hatzistilianou M. Diagnostic and prognostic role of procalcitonin in infections. *ScientificWorldJournal.* 2010;10:1941-1946.
10. van Dijk ST, Bos K, de Boer MGJ, Draaisma WA, van Enst WA, Felt RJJ, et al. A systematic review and meta-analysis of outpatient treatment for acute diverticulitis. *Int J Colorectal Dis.* 2018;33:505-512.
11. Sartelli M, Ansaloni L, Bartoletti M, Catena F, Cardi M, Cortese F, et al. The role of procalcitonin in reducing antibiotics across the surgical pathway. *World J Emerg Surg.* 2021;16:15.
12. Wacker C, Prkno A, Brunkhorst FM, Schlattmann P. Procalcitonin as a diagnostic marker for sepsis: a systematic review and meta-analysis. *Lancet Infect Dis.* 2013;13:426-435.
13. Solomkin JS, Mazuski JE, Bradley JS, Rodvold KA, Goldstein EJ, Baron EJ, et al. Diagnosis and management of complicated intra-abdominal infection in adults and children: guidelines by the Surgical Infection Society and the Infectious Diseases Society of America. *Clin Infect Dis.* 2010;50:133-164. Erratum in: *Clin Infect Dis.* 2010;50:1695. Dosage error in article text.
14. Nizri E, Spring S, Ben-Yehuda A, Khatib M, Klausner J, Greenberg R. C-reactive protein as a marker of complicated diverticulitis in patients on anti-inflammatory medications. *Tech Coloproctol.* 2014;18:145-149.
15. Kechagias A, Sofianidis A, Zografos G, Leandros E, Alexakis N, Dervenis C. Index C-reactive protein predicts increased severity in acute sigmoid diverticulitis. *Ther Clin Risk Manag.* 2018;14:1847-1853.
16. Vijayan AL, Vanimaya, Ravindran S, Saikant R, Lakshmi S, Kartik R, et al. Procalcitonin: a promising diagnostic marker for sepsis and antibiotic therapy. *J Intensive Care.* 2017;5:51.
17. Jeger V, Pop R, Forudastan F, Barras JP, Zuber M, PISO RJ. Is there a role for procalcitonin in differentiating uncomplicated and complicated diverticulitis in order to reduce antibiotic therapy? A prospective diagnostic cohort study. *Swiss Med Wkly.* 2017;147:w14555. Erratum in: *Swiss Med Wkly.* 2018;148:w14673.
18. Hanna MH, Kaiser AM. Update on the management of sigmoid diverticulitis. *World J Gastroenterol.* 2021;27:760-781.
19. Peery AF, Shaukat A, Strate LL. AGA clinical practice update on medical management of colonic diverticulitis: expert review. *Gastroenterology.* 2021;160:906-911.e1.